

THE NORMAL ROENTGENOGRAPHIC MEASUREMENT  
OF THE RIGHT DESCENDING PULMONARY ARTERY  
IN 1,085 CASES AND ITS CLINICAL APPLICATION

PART II. CLINICAL APPLICATION OF THE MEASUREMENT  
OF THE RIGHT DESCENDING PULMONARY ARTERY  
IN THE RADIOLOGICAL DIAGNOSIS OF PULMONARY  
HYPERTENSIONS FROM VARIOUS CAUSES

C. H. JOSEPH CHANG

*Department of Radiology, West Virginia University School of Medicine, Morgantown,  
West Virginia, U.S.A.*

The dilatation of pulmonary artery and increased measurement of the right descending pulmonary artery is a most reliable roentgen sign of pulmonary hypertension. Measurement of the right descending pulmonary artery on the routine posteroanterior view of chest, especially in inspiration and expiration is absolutely necessary in making the roentgenological diagnosis of pulmonary hypertension. To determine an abnormal measurement of the right descending pulmonary artery this author's normal value for the right descending pulmonary artery size is most important.

The purpose of this Part II is to report the radiological diagnosis of pulmonary hypertensions from various etiologies and other abnormal hemodynamics in pulmonary circulation by using this author's technique of measurement of the right descending pulmonary artery on the routine posteroanterior view of the chest.

PULMONARY HYPERTENSION IN ADVANCED SOFT  
COAL MINER'S PNEUMOCONIOSIS

The presence of pulmonary hypertension and cor pulmonale in advanced chronic lung disease, especially in soft coal miner's pneumoconiosis is a well known fact. The diagnosis of pulmonary hypertension can be made on the routine posteroanterior chest roentgenogram by measuring the right descending pulmonary artery. Inspiratory and expiratory measurement is most helpful in doubtful or borderline cases.

A representative case is illustrated as follows:

CASE REPORT

*Case 1.* P. L. This is a 55 year old negro male who has been working in the coal mines for the past 25 years. Since one year ago he has been

---

Received for publication June 24, 1965.

complaining of marked exertional dyspnea and it is progressively worse. At the present time he has dyspnea with the least amount of exercise. He has lost approximately 20 pounds of his body weight during the past 12 months. He denies any night sweats, productive cough or hemoptysis. Family history was non-contributory.

Physical examination showed increased anteroposterior diameter of the chest. It was hyperresonant with decreased breath sounds. The head, neck and abdomen were negative. Rectal examination revealed a moderately enlarged prostate gland. Laboratory examination was not remarkable except for 16.2 g of hemoglobin with hematocrit of 49. The electrocardiogram showed sinus bradycardia and first degree of atrioventricular block.

His chest roentgenograms (Fig. 8) showed advanced soft coal miner's pneumoconiosis with markedly dilated right descending pulmonary artery suggesting pulmonary hypertension. In inspiration the right descending pulmonary artery measured 20 mm and 22 mm for the expiration.

The patient was admitted on 11-17-63 for the right heart catheterization and measurement of the pulmonary artery pressure. The pulmonary artery pressure was mean 35 mmHg (58 mmHg, systolic/26 mmHg, diastolic) and

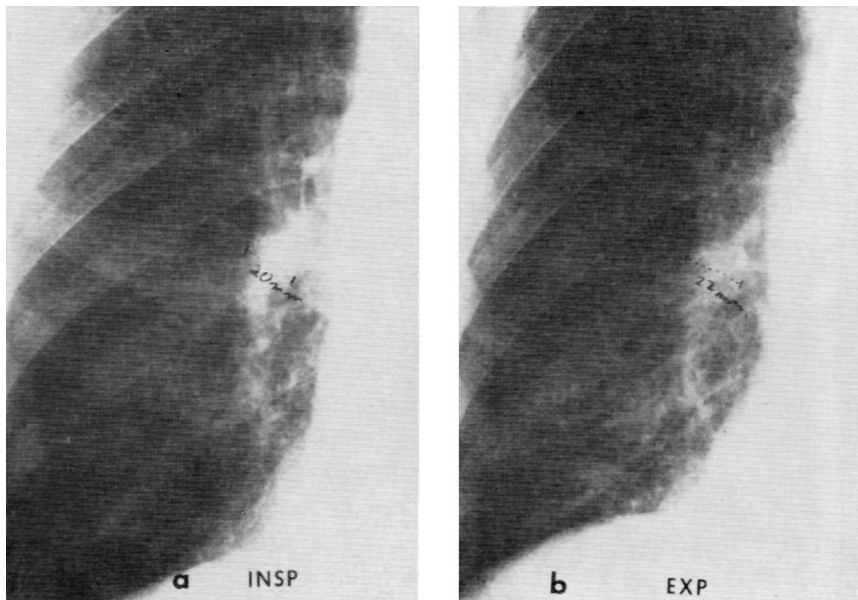


FIG. 8. Case 1. Abnormal measurement of the right descending pulmonary artery in pulmonary hypertension with advanced soft coal miner's pneumoconiosis.

(a) Inspiratory measurement is 20 mm.

(b) Expiratory measurement is 22 mm and it exceeds the inspiratory measurement. Note marked pulmonary emphysema with nodular fibrosis from advanced pneumoconiosis.

the diagnosis of pulmonary hypertension was confirmed. He was discharged from the hospital without any complication on 11-21-63.

*Comment:* This case well illustrated the usefulness of the right descending pulmonary artery measurement. The diagnosis of pulmonary hypertension was made on the chest roentgenogram prior to the catheter study. Inspiratory measurement, 20 mm is smaller than expiratory measurement of 22 mm. This is very interesting phenomenon. This is apparently paradoxical to the normal inspiratory and expiratory measurements. In normal, the expiratory measurements are always smaller than expiratory measurements.

#### PULMONARY HYPERTENSION IN POST-MITRAL COMMISSUROTOMY

Following mitral commissurotomy for the mitral stenosis, pulmonary hypertension can occur from postoperative mitral regurgitation or restenosis of mitral valve. The diagnosis of pulmonary hypertension can be made the right descending pulmonary artery measurements on the routine posteroanterior view of chest roentgenogram.

#### CASE REPORT

*Case 2.* T. E. This is a 54 year old white female. This patient has known rheumatic heart disease since her childhood. She was admitted because of increasing dyspnea on 4-21-59. She had a transventricular dilatation of the mitral valve for mitral stenosis at the National Institutes of Health and now shows clinical evidence of mitral regurgitation. She also had a radical resection of the hard palate and part of the soft palate for the carcinoma of the hard palate in 1958. However, no clinical or radiological evidence of recurrent malignancy was noted.

The posteroanterior view of the chest (Fig. 9) revealed enlarged right and left ventricle with left atrial enlargement. Dilated superior pulmonary veins were also noted. Marked dilatation of the right descending pulmonary artery suggesting pulmonary hypertension was noted. Inspiratory measurement was 20 mm and expiratory was 23 mm. Paradoxical expiratory measurement was again noted.

*Comment:* The diagnosis of pulmonary hypertension was apparently made by radiological study and no further catheter study was necessary in such a risky patient. This case shows a special value of roentgenographic measurement of the right descending pulmonary artery in making the diagnosis of pulmonary hypertension, especially with such a poor risky patient. Paradoxical phenomenon in inspiratory and expiratory measurements is also noted in this case. Expiratory measurement was larger than inspiratory measurement. This is also a reliable roentgen sign in chronic pulmonary hypertension.

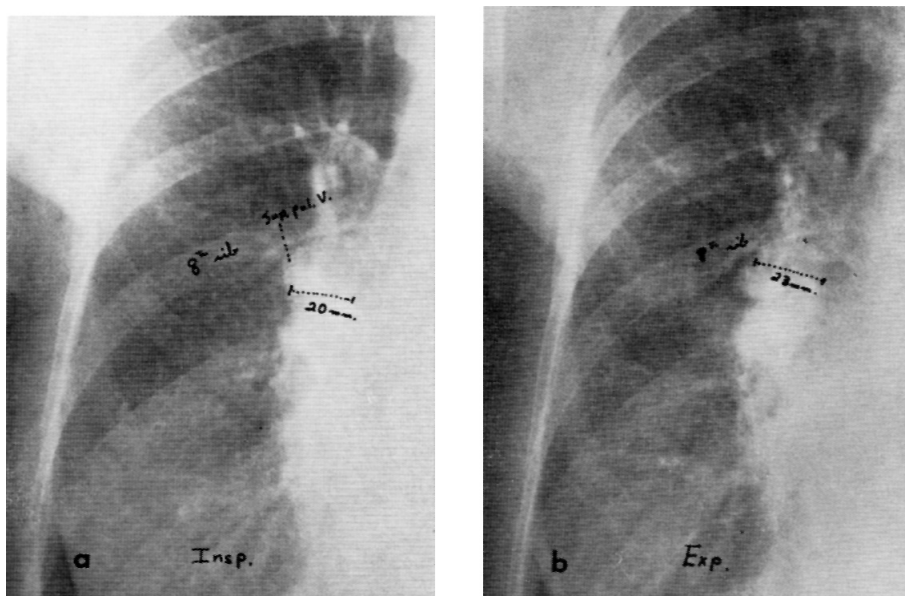


FIG. 9. Case 2. Abnormal measurement of the right descending pulmonary artery in pulmonary hypertension following mitral commissurotomy.

(a) Inspiratory measurement is 20 mm.

(b) Expiratory measurement is 23 mm. Paradoxical phenomenon of larger expiratory measurement in the chronic pulmonary hypertension is seen. Note persistently prominent superior pulmonary veins.

#### MEASUREMENTS OF THE RIGHT DESCENDING PULMONARY ARTERY IN PULMONARY INFARCTION

Roentgenological examination in the diagnosis of pulmonary infarction is a valuable study. Though various roentgenographic signs were described in the past, dilatation and increased measurement of the descending pulmonary artery in pulmonary infarcts is a most reliable roentgen sign. This sign is reported by this author and Davis<sup>5</sup>. The presence of acute cor pulmonale in pulmonary infarction will cause this roentgenographic phenomenon.

#### CASE REPORT

*Case 3.* T. E. This 29 year old white housewife, Gravida 5, Para 4, Abortions 0, was admitted to the hospital for a dilatation and curettage after an incomplete abortion. This was performed on the day of admission. She developed fever on the first postoperative day and three days later had sudden right-sided chest pain, increased by coughing. Blood streaked sputum was noted. However, no evidence of thrombophlebitis was noted.

On auscultation of the chest, decreased breath sounds and pleural ribs

were noted over the right lower lobe. White blood cell counts were normal with normal differentials. Electrocardiogram was within normal limits.

Chest roentgenogram previously (Fig. 10 A) was normal and the right descending pulmonary artery measured 12 mm. Chest X-ray on the day of the onset of chest pain (Fig. 10 B) showed a homogeneous density in the right lower lobe with dilatation of the right descending pulmonary artery which now measured 17 mm. These radiological findings are quite compatible with massive pulmonary infarction of the right lower lobe. Follow-up study (Fig. 10 C), five days later, demonstrated an accumulation of right pleural fluid and a persistence of the right lower lobe infiltration. The right descending pulmonary artery again measured 17 mm. Two months later (Fig. 10 D) there was resolution of the infarcts in the right lower lobe with linear scars and pleural thickening. The right descending pulmonary artery had returned to normal size (12 mm).

Following the infarct a right thoracentesis yielded grossly bloody fluid. The patient was treated symptomatically. The fever, hemoptysis and chest pain resolved and she was discharged three weeks after operation.

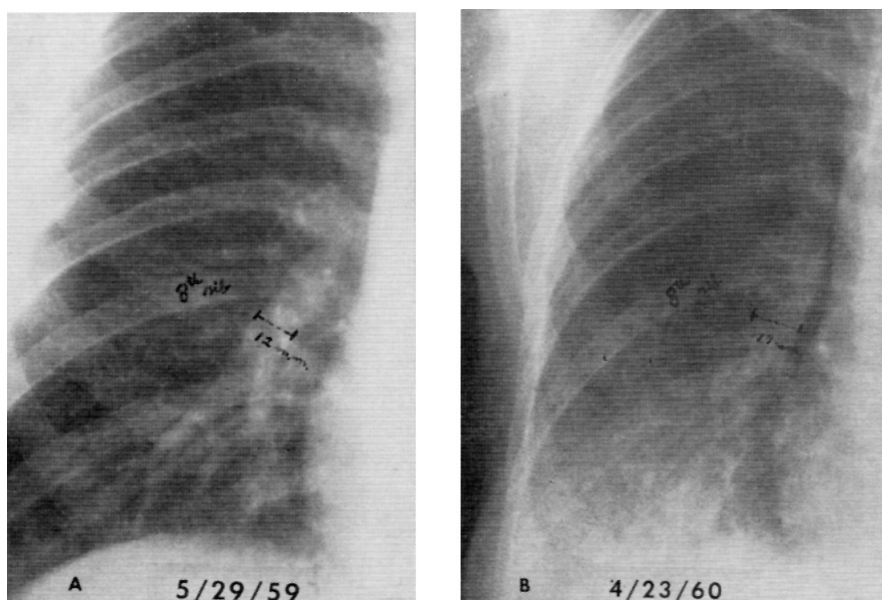


FIG. 10. Case 3. Abnormal measurement of the right descending pulmonary artery in pulmonary infarction of right lower lobe.

(A) Previous normal chest roentgenogram on 5-29-59. The right descending pulmonary artery measures 12 mm.

(B) Increased measurement of the right descending pulmonary artery with massive pulmonary infarction in the right lower lobe on 4-23-60. The artery measures 17 mm.

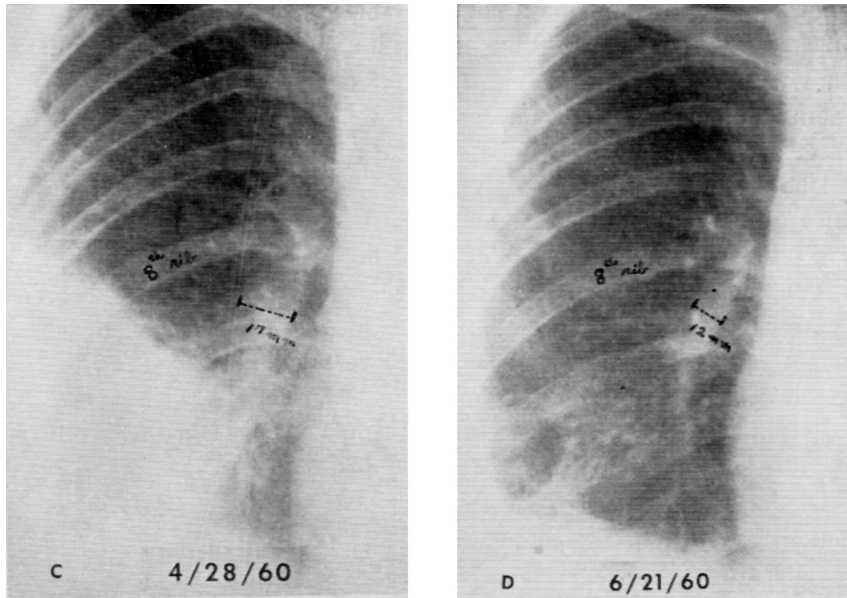


FIG. 10. Case 3. (cont'd)

(C) Follow-up study on 4-28-60 again shows persistent infarcts in the right lower lobe and appearance of the right pleural fluid. The right descending pulmonary artery measurement is again 17 mm.

(D) Two months later, 6-21-60, resolution of the pulmonary infarction in the right lower lobe with linear pulmonary scars and residual pleural thickening. The size of the right descending pulmonary artery returned to normal and now measures 12 mm.

*Comment:* Dilatation of the descending pulmonary artery is a most constant and reliable roentgen sign of pulmonary infarction. Measurement of the right descending pulmonary artery is essential in the radiological diagnosis of pulmonary infarcts on the right and this was well illustrated by this case. This roentgen sign usually appears within 24 hours of the onset of chest pain and shows its maximal measurements within two to three days. In doubtful cases, especially shortly after possible infarction, serial films taken at daily intervals for three days are helpful in showing change of the size of the descending pulmonary artery. If available, previous chest roentgenograms are valuable in showing changes from a previously normal range of descending pulmonary artery size.

This sign is also helpful to make early differential diagnosis with pneumonitis. No demonstrable dilatation of the descending pulmonary artery is seen in pneumonitis, even with a massive lobar consolidation. The measurement of the artery remains within normal limits and this is well illustrated by the following case:

## CASE REPORT

*Case 4.* L. L. A 37 year old white female had total abdominal hysterectomy for carcinoma in situ of the cervix. On the first postoperative day she had dyspnea, wheezing and fever. Her chest roentgenogram (Fig. 11 A) showed massive lobar consolidation involving the right lower lobe. However, the measurement of the right descending pulmonary artery remains within normal limits (14 mm). Follow-up study (Fig. 11 B) three days later after intensive antibiotic therapy shows complete resolution of the pneumonia. There are no changes in the size of the right descending pulmonary artery which still measures 14 mm.

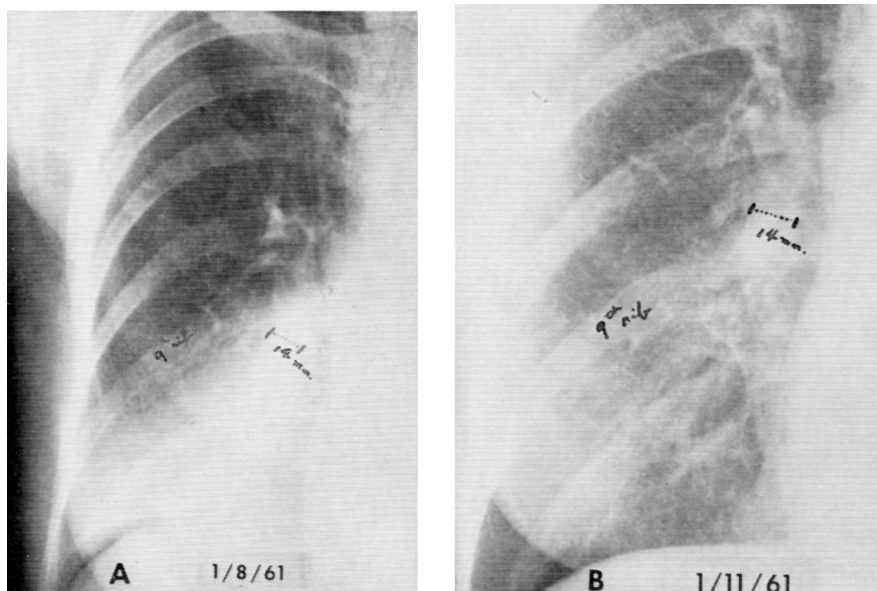


FIG. 11. Case 4. Normal measurement of the right descending pulmonary artery in the right lower lobar pneumonia.

(A) The right descending pulmonary artery measures 14 mm. Note right lower lobar pneumonia and postoperative pneumoperitoneum.

(B) Three days later, after intensive antibiotic therapy, complete resolution of the right lower lobar pneumonia is noted. The right descending pulmonary artery again measures 14 mm. No changes in the size of the right descending pulmonary artery, even massive lobar pneumonia.

MEASUREMENT OF THE RIGHT DESCENDING PULMONARY ARTERY  
IN PULMONARY EMBOLISM WITHOUT INFARCTION

In approximately 20 per cent of the cases of pulmonary embolism, infarction does not occur (Hampton and Castleman (1940)). This will make the roentgen diagnosis very difficult. Although Westermark<sup>10</sup>, in 1938, described

oligemia of lungs causing increased radiolucency and decreased volume of the lung involved which was described by Fleischner (1962)<sup>6)</sup>, most constant and early roentgen sign in acute embolism involving the more peripheral portion of the pulmonary artery without infarction is dilated pulmonary artery. There may be amputated appearance of the pulmonary artery. However, the dilatation of the descending pulmonary artery is most reliable roentgen sign. Acute cor pulmonale and pulmonary hypertension from pulmonary embolism is responsible for this valuable sign. This may be only recognizable abnormality on the chest roentgenograms in this condition. The diagnosis can only be made by measuring the right descending pulmonary artery in this abnormality.

#### CASE REPORT

*Case 5.* G. L. This is a 23 year old white dental student who was admitted to the hospital on 7-2-64 because of severe dyspnea and weakness.

Earlier that morning he had gotten out of bed and gone to the bathroom and during the process of having a bowel movement had become severely dyspneic. This period of dyspnea was associated with rapid heart beat and extreme weakness.

A pheochromocytoma of the right adrenal gland had been removed nine days prior to this admission.

Chest roentgenogram (Fig. 12 b) on admission revealed marked dilatation of the right descending pulmonary artery which measures 20 mm. There was also seen amputated appearance of the artery to the right lower lobe. Slightly increased radiolucency was also noted in the right lower lobe. With this finding the diagnosis of acute embolism of the right lower lobe artery without infarction is strongly suggested. There appeared to be definite increase in size of the right descending pulmonary artery since previous normal chest roentgenogram of 5-27-64 which measured 15 mm (Fig. 12 a).

Electrocardiograms were taken and showed S wave change which was compatible with pulmonary embolism. In view of these findings and more apparent roentgenographic changes, the diagnosis of pulmonary embolism without infarcts was confirmed. He was then placed on large doses of heparin and absolute bed rest. During the next few days the patient developed severe pain over the right scapula which was intensified by breathing. This pain gradually subsided within a week. Blood enzyme studies during this period revealed an elevation of lactic dehydrogenase (LDH) to 750 units. Follow-up chest X-ray film on 7-8-64 (Fig. 12 c) now showed the size of the right descending pulmonary artery to be returned to normal size (15 mm). Also amputated appearance of the right lower lobe artery was not seen. No demonstrable radiological evidence of new pulmonary embolism was noted.

The patient was kept in bed until all of his chest pain had subsided.



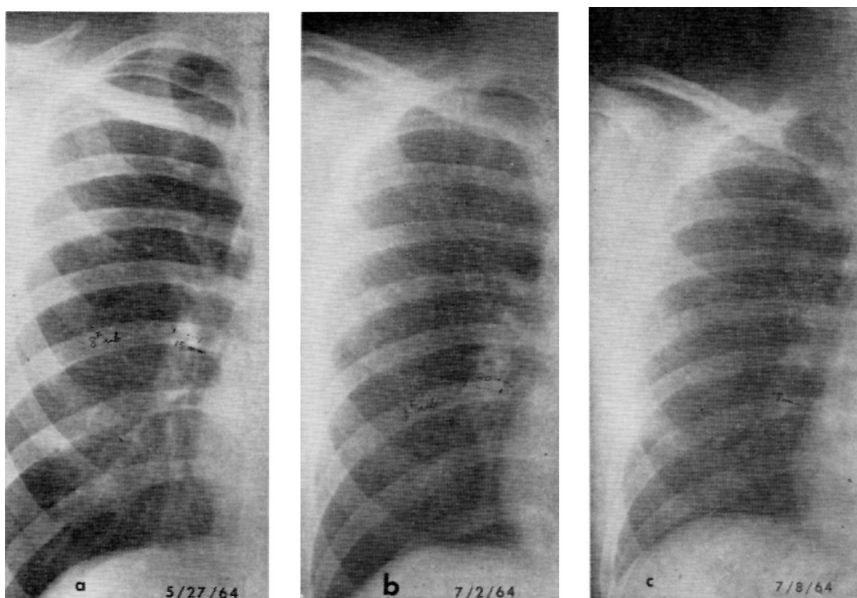


FIG. 12. Case 5. Abnormal measurement of the right descending pulmonary artery in the pulmonary embolism involving more peripheral portion of the right pulmonary artery without infarction.

(a) Normal pre-operative chest roentgenogram on 5-27-64. The right descending pulmonary artery measures 15 mm.

(b) Admission chest roentgenogram on 7-2-64 showing markedly dilated right descending pulmonary artery with amputated appearance of the artery to the right lower lobe (arrow). These findings are quite compatible with pulmonary embolism involving the artery to the right lower lobe without pulmonary infarction. The right descending pulmonary artery now measures 20 mm.

(c) Follow-up study on 7-8-64 shows normal appearing right descending pulmonary artery. The size of the artery returned to normal and it now measures 15 mm.

Heparinization was discontinued on 7-29-64 with institution of anticoagulation with cumidin. He was discharged on 7-26-64 with maintenance dose of cumidin for the next several months.

*Comment:* This case very well illustrated the value of measurement of the right descending pulmonary artery in making the diagnosis of pulmonary embolism without infarction. On gross observation of the chest roentgenogram on 7-2-64 (Fig. 12 b) no gross pulmonary abnormalities were shown which may have passed as a negative chest. However, there was apparent dilatation of the right descending pulmonary artery and measurement of the artery was 20 mm. This immediately indicates acute pulmonary hypertension and abnormal pulmonary hemodynamics. With this finding plus amputated appearance of the right lower lobe artery and with clinical symptoms, the diagnosis of acute

embolism of the right lower lobe artery without pulmonary infarction can readily be made.

MEASUREMENT OF THE RIGHT DESCENDING PULMONARY ARTERY IN ACUTE  
MASSIVE EMBOLISM OF MAIN RIGHT PULMONARY ARTERY

An acute massive embolism of the central pulmonary artery is a serious emergency. However, there is only minimal physical findings. In contrast to the patient's severe dyspnea and anxiety, there may be a few rales or an occasional asthmatic wheeze may be heard.

The chest roentgenogram is of great importance in making prompt diagnosis. Westermarck (1938)<sup>14)</sup> described oligemia of the lung, and "stringy" appearance of the vessel shadows was described by Torrance (1959)<sup>13)</sup> in this condition. However, changes in size of the descending pulmonary artery is also very valuable roentgen sign. Measurement of the right descending pulmonary artery in making the roentgen diagnosis and differential diagnosis of acute massive emboli involving the main right pulmonary artery is most important.

In contrast to emboli to the more peripheral portion of the pulmonary artery, the size of the right descending pulmonary artery may be either decreased or normal in acute massive embolism of the central right pulmonary artery. Severe arteriospasm of the pulmonary artery following massive emboli may be responsible for this roentgen phenomenon. There may also be compensatory increased pulmonary flow in the left lung. Increased radiolucency of the lung from oligemia is more apparent in this condition.

CASE REPORT

*Case 6.* S. L. This 75 year old white female was re-admitted to the hospital on the afternoon of 2-25-62 with severe dyspnea and bilateral anterior chest pain. She was markedly cyanotic but no evidence of thrombophlebitis was seen in either leg. She was discharged from the hospital in the same morning after successful repair of her ventral hernia. She had right hemicolectomy in December of 1960 for the carcinoma of the cecum, and no clinical evidence of recurrent tumor could be found.

The electrocardiogram showed right heart strain. With these clinical and laboratory findings, the possibility of pulmonary embolism is raised.

Her chest roentgenogram on 2-25-62 (Fig. 13 b) showed markedly increased radiolucency in the entire right lung with apparently decreased size of the right descending pulmonary artery. The artery now measures only 8 mm. This was 14 mm on previous study of 11-2-60 (Fig. 13 a). The right diaphragm was also markedly elevated. These findings are quite compatible with acute massive embolism involving the main right pulmonary artery.

She was immediately prepared for surgery and had embolectomy of the

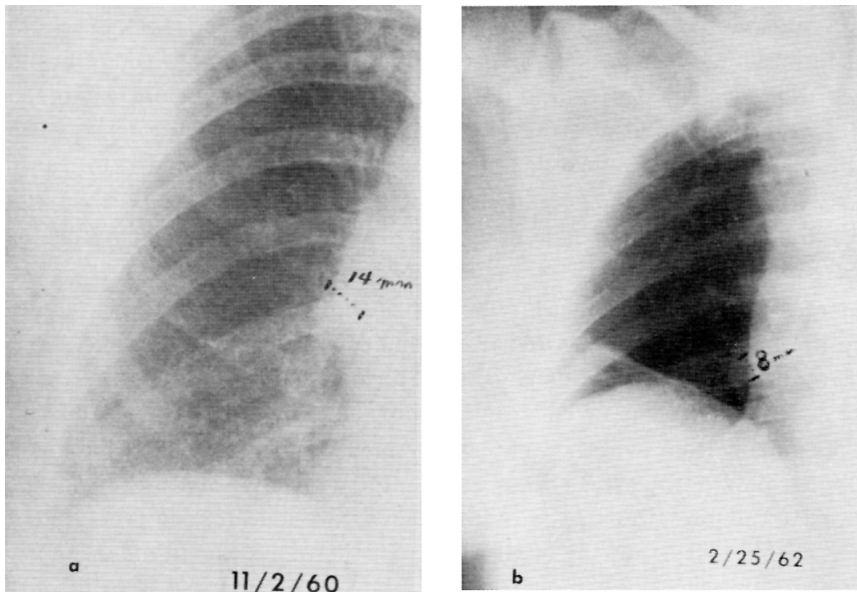


FIG. 13. Case 6. Abnormal measurement of the right descending pulmonary artery in a case of massive embolism involving the central right pulmonary artery.

(a) Chest roentgenogram on 11-2-60 showing normal size of the right descending pulmonary artery. The measurement is 14 mm.

(b) Chest roentgenogram on admission showing markedly increased radiolucency of the right lung and decreased size of the right descending pulmonary artery. The artery now measures 8 mm. Elevation of right diaphragm is also noted. These findings are quite compatible with massive pulmonary embolism involving the central right pulmonary artery.

pulmonary artery. Several large organized clots were removed from the pulmonary artery without difficulty. Because of the massiveness of the emboli, the patient did not tolerate the procedure and shortly after extraction of the emboli her heart ceased to beat and could not be revived.

*Comment:* This is a typical case of acute massive emboli of the main right pulmonary artery following surgery. The physical, laboratory and radiological findings are classical. Markedly increased radiolucency of the right lung, severe oligemia, with decreased right descending pulmonary artery measurement will provide the diagnosis. Early diagnosis could save patient's life, especially recent advance in the surgical technique of pulmonary artery embolectomy. The sign of decreased size of the right descending pulmonary artery is also important in making differential diagnosis with so-called "idiopathic unilateral increased radiolucency of the lung". The later will not show decreased size of the pulmonary artery.

## DISCUSSION

All afore-cited cases of pulmonary hypertension from various etiologies showed dilated right descending pulmonary artery and abnormal roentgenographic measurements of the artery. The width of the artery varied with the changes of pulmonary hemodynamics and this appeared to be very sensitive. In massive pulmonary embolism the central portion of the right pulmonary artery, the size of the right descending pulmonary artery may be either decreased or normal.

Increased expiratory measurements of the right descending pulmonary artery in chronic pulmonary hypertension, especially with chronic lung diseases in an interesting roentgenographic phenomenon. This is paradoxical to the normal measurements which always show smaller expiratory measurements. This phenomenon of increased expiratory measurement is probably the result of a higher pulmonary artery pressure than intra-alveolar pressure and a further increase of the pressure in the pulmonary artery due to compression of the pulmonary capillaries during expiration. Furthermore, the pulmonary vascular resistance falls with positive-pressure inflation in a collapsed or a moderately inflated lung, such condition as in a chronic lung disease, and this was well illustrated by Burton and Patel's experiments (1958)<sup>4</sup>. To my knowledge, this paradoxical phenomenon in chronic pulmonary hypertension was never described in the literatures. The inspiratory and expiratory measurements are of great value, especially in borderline normal cases. In normal cases, there is a definite decrease during expiration.

In hemodynamically significant acute pulmonary embolism, whether with or without pulmonary infarction, most reliable and constant early roentgen sign is a dilatation of the descending pulmonary artery except for the acute massive embolism involving the central pulmonary artery. Measurement of the descending pulmonary artery, affected side, on the chest roentgenogram is of great value in making the diagnosis of pulmonary embolism. Especially in acute pulmonary embolism without infarction, this is the only detectable roentgenographic change and this was well illustrated in Case 5. This roentgen sign is also helpful to make early differential diagnosis with pneumonitis. No demonstrable dilatation of the artery is seen in the acute pneumonitis, even with a massive lobar consolidation. This was also well illustrated in Case 4. This sign usually appears within 24 hours of onset of the disease and shows its maximal measurement of the artery in two to three days. Serial films of the chest taken at intervals of 12 or 24 hours are also of great value, especially in doubtful or very early cases.

In acute massive pulmonary embolism of the central pulmonary artery, however, the size of the pulmonary artery may be decreased or normal. Increased radiolucency of the lungs from oligemia is usually more apparent

in this condition. These were well illustrated in Case 6.

In all cases, abnormal pulmonary hemodynamics were best diagnosed by measuring the right descending pulmonary artery on the posteroanterior view of the chest roentgenograms.

#### SUMMARY AND CONCLUSIONS

The abnormal roentgenographic measurements of the right descending pulmonary artery in pulmonary hypertension from various etiologies are presented with illustrated cases and its value of the clinical application is also described. Measurement of the right descending pulmonary artery by this author's method is of great value in the diagnosis of abnormal pulmonary hemodynamics.

The following observations were also made:

1. In pulmonary hypertension, the right descending pulmonary artery measurement exceeded the normal upper limits (16 mm in male and 15 mm in female). If the artery measures 17 mm or more the presence of pulmonary hypertension is indicated. This is a valuable roentgen sign of pulmonary hypertension.

2. In chronic pulmonary hypertension, especially with chronic lung disease, the phenomenon of increase in expiratory measurement of the right descending pulmonary artery is noted. To this author's knowledge, this paradoxical phenomenon was never reported in the literatures, and this is the first to report a new roentgen sign. In normal adults, the expiratory measurements are always smaller than inspiratory.

3. Increased measurement of the descending pulmonary artery is a most reliable and constant early roentgen sign in hemodynamically significant acute pulmonary embolism involving the more peripheral portion of the pulmonary artery. Sometimes, this sign is only detectable roentgenographic change, especially in an acute pulmonary embolism without pulmonary infarction and the diagnosis can always be made by the measurement of the descending pulmonary artery of the affected side.

4. In acute massive pulmonary embolism involving the central pulmonary artery, the measurement of the descending pulmonary artery may be decreased or normal.

#### REFERENCES

1. Abrams, H. L. Radiologic aspects of increased pulmonary artery pressure and flow; preliminary observations. *Stanford M. Bull.* 14: 97-111, 1956.
2. Assmann, H. Über Veränderungen der Hilusschatten im Röntgenbilde bei Herzkrankheiten. *Deutsche Arch. Klin. Med.* 132: 355-361, 1920.
3. Bayliss, R. I. S. Effect of lung disease on the heart and circulation. *Brit. Med. Bull.* 8: 354-357, 1952.

4. Burton, A. C. and D. J. Patel. Effect on Pulmonary Vascular Resistance of Inflation of the Rabbit Lungs. *J. Appl. Physiol.* **12**: 239-246, 1958.
5. Chang, C. H. (Joseph) and W. C. Davis. A Roentgen Sign of Pulmonary Infarction. *Clin. Radiol.* (In press, will appear in January 1965 issue).
6. Fleischner, F. G. Pulmonary Embolism. *Clin. Radiol.* **18**: 169-182, 1962.
7. Halmógyi, D., B. Felkai, J. Iványi, M. Tényi, T. Zsotér, and Z. Seics. The role of the nervous system in the maintenance of pulmonary arterial hypertension in heart failure. *Brit. Heart J.* **15**: 15-24, 1953.
8. Hampton, A. O. and J. Castleman. Correlation of postmortem chest teleroentgenograms with autopsy findings: with special reference to pulmonary embolism and infarction. *Amer. J. Roentgen.* **43**: 305-326, 1940.
9. Johnson, P. M., E. H. Wood, B. S. Pasternack, and M. A. Jones. Roentgen evaluation of pulmonary arterial pressure in mitral stenosis. *Radiology*, **76**: 541-547, 1961.
10. Macklin, C. E. Musculature of bronchi and lungs. *Physiol. Rev.* **9**: 1-60, 1929.
11. Rushmer, R. F. Cardiovascular Dynamics. *Second Edition*, 1961. W. B. Saunders Co., Philadelphia and London.
12. Schwedel, J. B., D. W. Escher, S. R. Aaron, and D. Young. Roentgenologic diagnosis of pulmonary hypertension in mitral stenosis. *Amer. Heart J.* **53**: 163-170, 1957.
13. Torrance, Jr., D. J. Roentgenographic Signs of Pulmonary Artery Occlusion. *Amer. J. Med. Sci.* **237**: 651-662, 1959.
14. Westermark, N. On the Roentgen Diagnosis of Lung Embolism. *Acta. Radiol.* **19**: 357, 1938.
15. Westermark, N. Importance of intra-alveolar pressure in diagnosis of pulmonary diseases. *Radiology* **50**: 610-618, 1948.