

## 23 Fractures of the Talus

M. Tile

### 23.1

#### Introduction

Injuries to the talus occur infrequently, but, when they do, the consequences can be grave. Misconceptions about this injury abound, due mainly to poor comprehension of the blood supply to the talus and to the common practice of comparing dissimilar cases.

Disability arising from talar fractures is due to the major complications of avascular necrosis and of malunion from nonanatomical reduction, which in turn leads to osteoarthritis of the subtalar joint and altered biomechanics of the foot. Also, skin problems are common, often worsened by injudicious surgery. Sepsis may ensue, with severe disability or amputation the likely outcome.

In 1832, Sir Astley Cooper gave in dramatic detail one of the first accounts of the natural history of dislocation of the talus. He describes vividly how «Mr. Downes, on the 24th of July, 1820, had the misfortune to dislocate the astragalus by falling from his horse.» In consultation he observed «that I would not operate and that perhaps the skin might give way and the bone become exposed – when we would be justified in removing it.» Previous treatment was therefore further pursued: «On the 29th the leeches were repeated and the lotion continued.» – «On the 20th of August – . . . there was a great discharge of pus and the astragalus became loose. . . . On Oct. 5, 1820, finding the astragalus very loose, I removed it» (i.e., 10 weeks after the accident). In October, 1821, the patient «had slight motion at the ankle which was gradually increasing.»

Syme (1848) recorded 13 patients, of whom only two survived. He recommended primary amputation for open injuries of the talus. Anderson (1919) collected 18 cases of talar injuries occurring in air crashes and named this injury «aviator's astragalus.»

Coltart, in 1952, wrote the then definitive work on this subject. He recorded 228 cases, of which 106 were fractures or fracture-dislocations of the talar neck. Most of the subsequent reviews reflect the principles

in Coltart's series. He described the natural history of fractures of the talar neck with no displacement, with subtalar dislocation, and with complete dislocation of the body of the talus, and he indicated the prognosis of each.

As in all fractures, sound management depends upon a return to basic principles. Fractures of the talar neck with displacement demand anatomical reduction and stable internal fixation if closed reduction fails, otherwise the subtalar joint will be adversely affected. However, surgery must not jeopardize the already precarious blood supply to the body of the talus.

Therefore, a precise knowledge of the blood supply to the talus is essential for logical management.

### 23.2

#### Anatomical Considerations

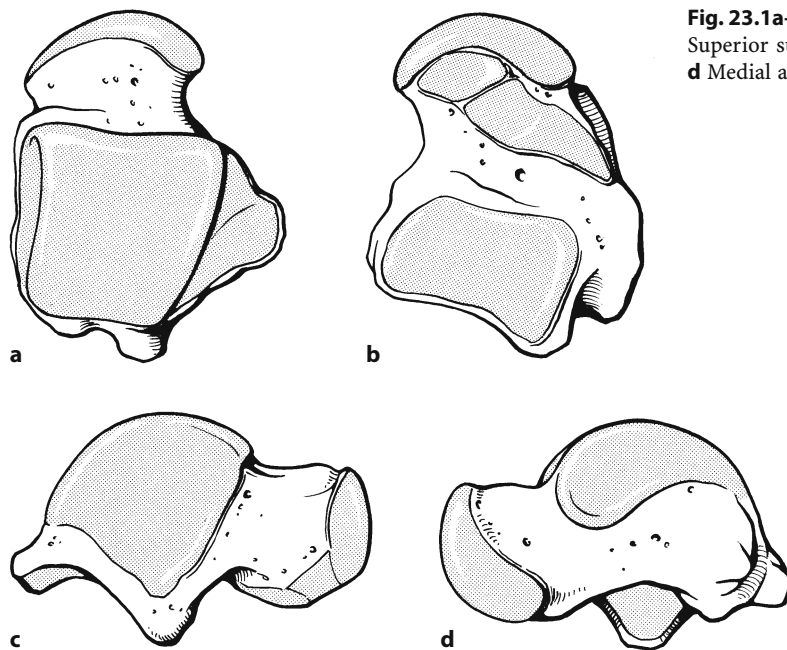
The talus is an unique bone, in that 60% of it is covered by articular cartilage, and it has no muscular or tendinous attachments (Fig. 23.1).

#### 23.2.1

##### Vascular Anatomy

The surgical significance of the vascular anatomy cannot be overemphasized. Because of the association of certain fractures and dislocations with avascular necrosis of the body of the talus, the extraosseous and intraosseous vascular anatomy has been the subject of considerable investigation. Lexor et al. (1904), Sneed (1925), Phemister (1940), McKeever (1943), Watson-Jones (1946), Kleiger (1948), and Wildenauer (1950) were pioneers in this field.

Wildenauer (1950) fully described the blood supply of the talus and is credited with being the first to describe the important artery arising from the posterior tibial artery and coursing through the tarsal canal, which is now known to be the most important



**Fig. 23.1a–d.** Anatomical features of the talus. **a** Superior surface. **b** Inferior surface. **c** Lateral aspect. **d** Medial aspect

vessel to the body of the talus. He also pointed out the anatomical distinction between the tarsal sinus and the tarsal canal. The tarsal canal is formed by the sulcus of the talus and the sulcus of the os calcis. It lies obliquely from a posterior medial to an anterior lateral position and opens into the tarsal sinus. In the canal, the interosseous talocalcaneal ligament and the artery of the tarsal canal are located. Wildenauer believed that the most important vascular contributions came from the arteries of the tarsal sinus, tarsal canal, and the medial periosteal network.

Further studies by Coltart (1952), Lauro and Purpura (1956), Haliburton et al. (1958), and Montis and Ridola (1959) added to our knowledge by confirming the studies of Wildenauer, especially the importance of the medial blood supply.

Mulfinger and Trueta (1970) wrote the classic work on this subject, again reaffirming the earlier findings of Wildenauer. Their experimental technique ensured that only the arterial blood supply was injected with contrast medium, offsetting criticism of previous studies.

The important arterial supply to the talus is described in the following sections.

### 23.2.1.1

#### Extraosseous Arterial Supply

##### *From the Posterior Tibial Artery*

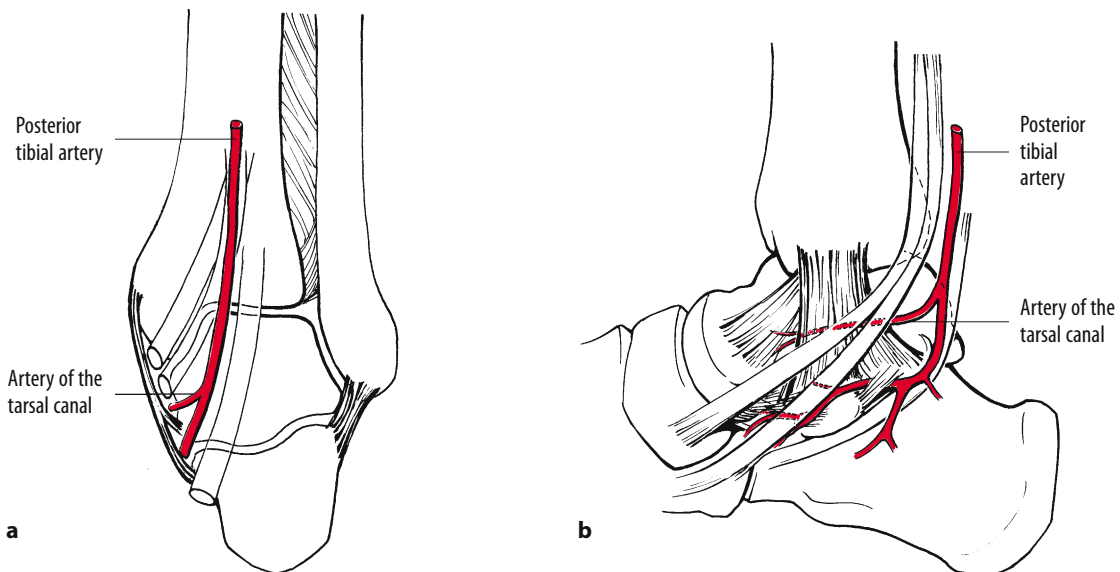
**Artery of the Tarsal Canal.** This important artery usually arises from the posterior tibial artery, 1 cm

proximal to the origin of the medial and lateral plantar arteries (Fig. 23.2). From that point, it passes anteriorly between the sheath of the flexor digitorum longus and the flexor hallucis longus muscles to enter the tarsal canal, in which it lies anteriorly close to the talus. Many branches enter the body of the talus from the arterial network in the tarsal canal. Continuing through the tarsal canal into the tarsal sinus, this artery anastomoses with the artery of the tarsal sinus, forming a rich vascular sling beneath the talar neck.

**Deltoid Branch.** A substantial artery supplying a portion of the medial half of the body of the talus hugs the inner surface of the deltoid ligament of the ankle (Fig. 23.3). This vessel arises most commonly from the artery of the tarsal canal or directly from the posterior tibial artery, and less frequently from the medial plantar branch of the posterior tibial artery. The surgical significance of this vessel is obvious. First, since most injuries of the talus occur with dorsiflexion and inversion, the medial soft tissues, including this artery, may remain intact and ensure the viability of the body of the talus. Second, medial surgical approaches to the talus may interfere with this vessel, thereby possibly injuring the only remaining blood supply to the talus.

##### *From the Anterior Tibial Artery*

**Superior Neck Branches.** The dorsalis pedis artery, a continuation of the anterior tibial artery, sends branches to the superior surface of the neck of the talus.



**Fig. 23.2a,b.** Extrasosseous blood supply to the talus. **a** The artery of the tarsal canal arising from the posterior tibial artery. Note its position along the interior surface of the deltoid ligament. **b** From there, it can be seen entering the tarsal canal

**Artery of the Tarsal Sinus.** This artery is always present, large, and always anastomoses with the artery of the tarsal canal. It is formed by an anastomosis of a branch of the dorsalis pedis artery with a branch of the perforating peroneal artery. This lateral blood supply is profuse, with many direct branches into the bone.

#### **From the Peroneal Artery**

Small branches from the peroneal artery join with branches of the posterior tibial artery to form the posterior plexus around the talus. The perforating peroneal artery contributes to the artery of the tarsal sinus, but in general the peroneal supply to the talus is not considered to be important.

#### **23.2.1.2**

##### **Intraosseous**

#### **Head of Talus**

The head of the talus is supplied by two sources, medially by branches of the dorsalis pedis artery and laterally by branches of the arterial anastomosis in the artery of the tarsal sinus (Fig. 23.4).

#### **Body of Talus**

The anastomotic artery in the tarsal canal supplies most of the talar body, through four or five branches

on the medial side. This vessel usually supplies almost all of the middle third of the body, except for the extreme superior aspect, and all of the lateral third, except for the posterior aspect.

The deltoid artery supplies the medial third of the body (see Fig. 23.4).

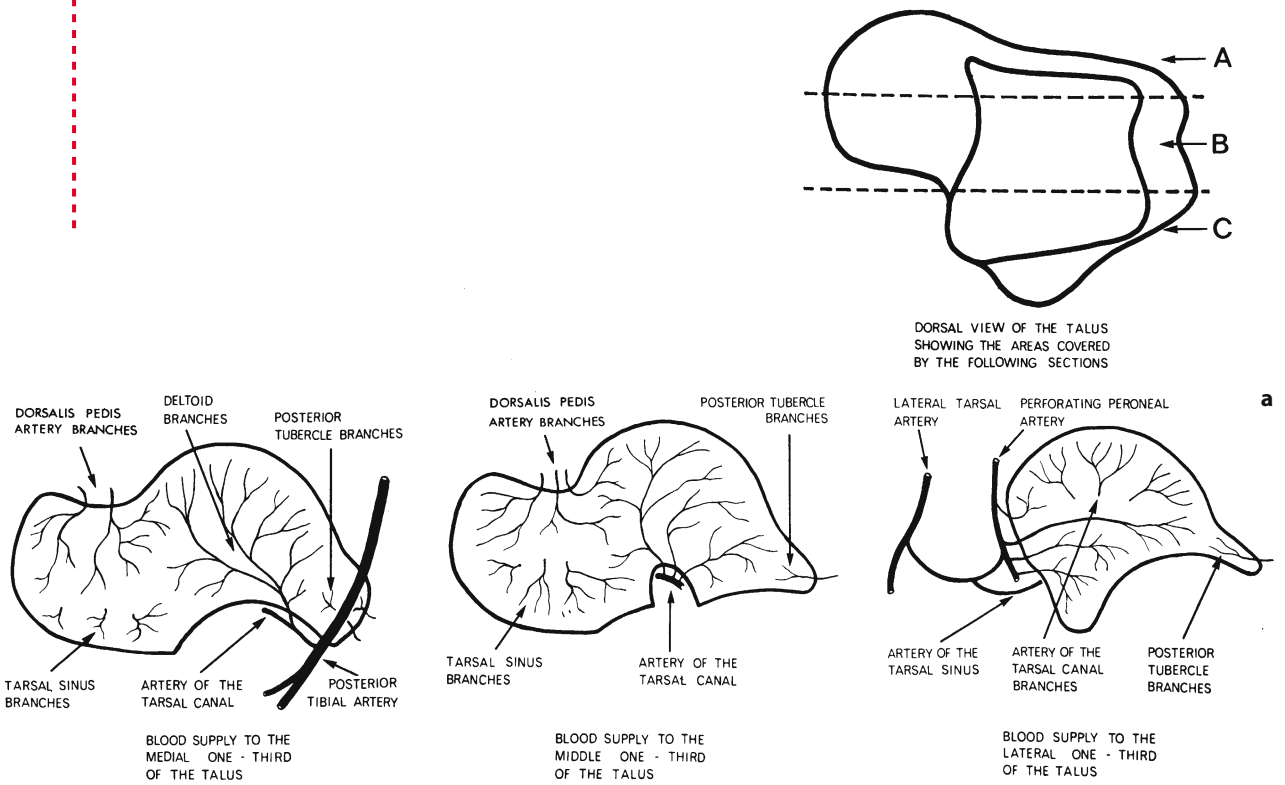
Rich anastomoses within the bone were found in almost all cases, especially between the superior neck vessels and the vessels arising from the tarsal canal. In some people, the artery of the tarsal sinus and the tarsal canal may anastomose within the bone.

#### **23.2.1.3**

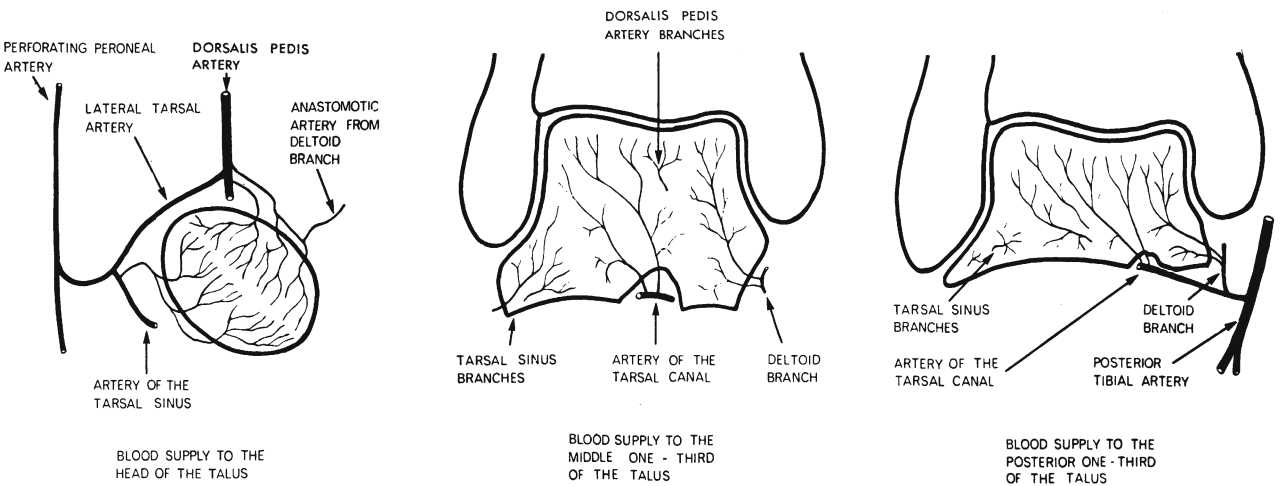
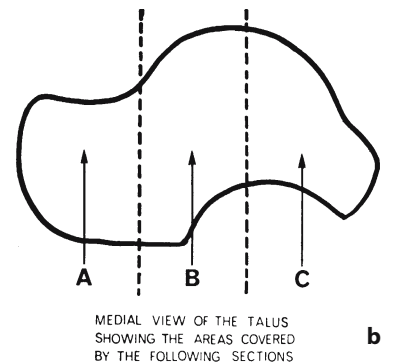
##### **Summary**

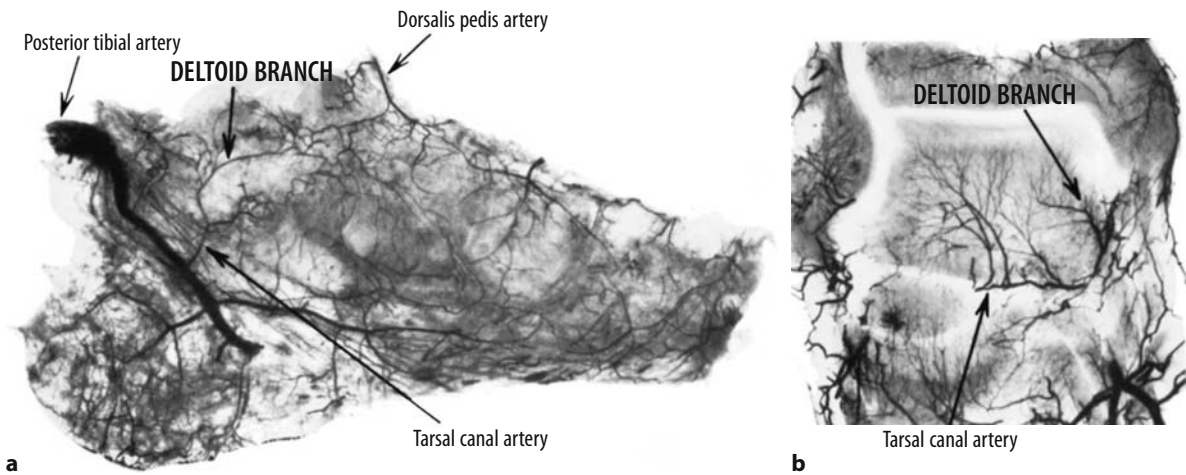
From these studies, it may be deduced that:

1. The body of the talus has a rich blood supply through several anastomoses.
2. The major blood supply enters posterior to the talar neck, so that an isolated neck fracture, unless it extended posteriorly into the body, would be unlikely to interfere with the blood supply.
3. An important vessel lies adjacent to the inner surface of the deltoid ligament. Except in cases of total dislocation of the talus and posterior extrusion of the body, this vessel maintains the viability of the talar body, if it is not interfered with surgically.



**Fig. 23.3a,b.** The deltoid branch. **a** Blood supply to the talus in sagittal sections. The artery of the tarsal canal is shown with the deltoid artery branch arising from it, lying close to the inner surface of the deltoid ligament and entering the body of the talus. **b** Blood supply to the talus in coronal sections. The deltoid branch arising from the artery of the tarsal canal is clearly seen with its relationship to the deltoid ligament and medial malleolus. The other arterial supply, including the perforating peroneal artery, the lateral tarsal artery, the artery of the tarsal sinus, and the dorsalis pedis artery, is also clearly indicated. (From Mulfinger and Trueta 1970)





**Fig. 23.4a,b.** Interosseous blood supply to the talus. **a** Sagittal section of the middle third of the tarsal bone. Anastomoses between the deltoid branches and dorsalis pedis artery can be seen. **b** Coronal section through the middle third of the talus, again showing the anastomotic links. (From Mulfinger and Trueta 1970)

## 23.2.2

### Mechanism of Injury

#### 23.2.2.1

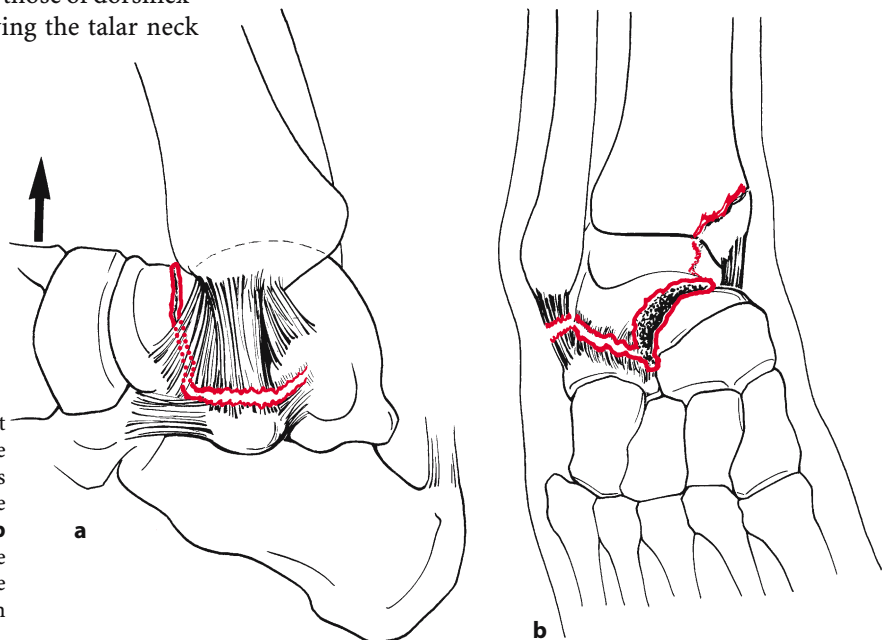
##### Common Pattern

Most fractures of the talar neck are caused by a severe dorsiflexion force (see Fig. 23.5). In the Royal Air Force studies (Coltart 1952), forced dorsiflexion of the foot against the rudder bar caused the fracture of the talar neck: hence the term “aviator’s astragalus.” In our society, most injuries are caused by the complex high-energy forces associated with motor vehicle accidents.

Rotation forces may be added to those of dorsiflexion to complete the injury. Following the talar neck

fracture, the body of the talus locks in the ankle mortise. The remainder of the foot, including the head of the talus and the os calcis, displaces medially through the subtalar joint (Fig. 23.5).

Continuation of the dorsiflexion force ruptures the intraosseous ligaments between the talus and os calcis as well as the posterior talofibular and talocalcaneal ligaments. The body of the talus is forced posteromedially out of the mortise with the neck fracture, pointing laterally and superiorly. In more than 50% of such cases the medial malleolus fractures obliquely or vertically (Figs. 23.5b; see also Fig. 23.12).



**Fig. 23.5a,b.** Talar neck fractures. Most talar neck fractures are caused by a severe dorsiflexion force. **a** The talar neck abuts the anterior portion of the tibia and the continuing force fracture the talar neck. **b** A continuing inversion force ruptures the lateral subtalar ligaments, and often the lateral ligament of the ankle, or causes an avulsion of the lateral malleolus

Thus, the body of the talus rotates around the intact or partially intact deltoid ligament and eventually rests posterior to the medial malleolus, anterior to the Achilles tendon. The neurovascular structures are rarely injured primarily, but may be secondarily if pressure on them is not rapidly removed.

### 23.2.2.2

#### Atypical Patterns

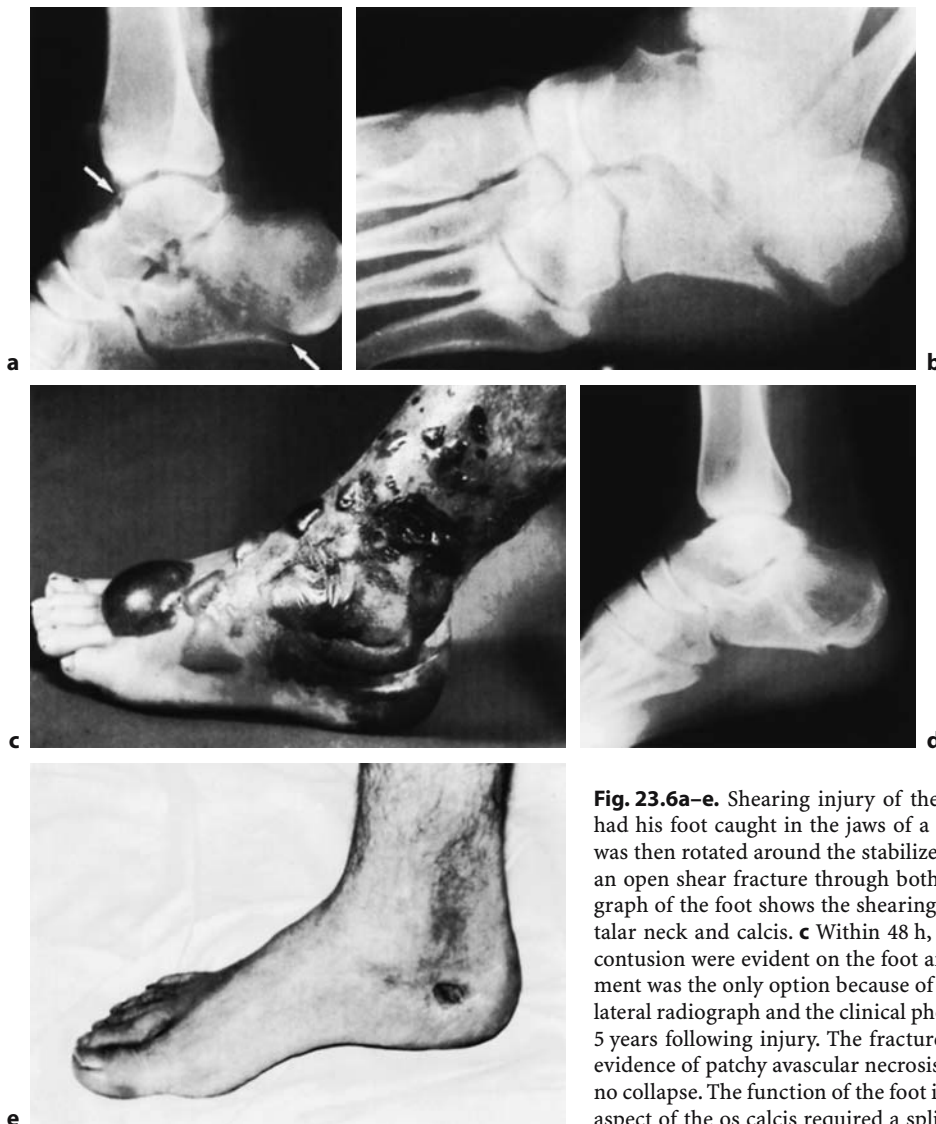
Instead of the usual injury of dorsiflexion, shearing forces may occasionally produce an unusual injury. Shearing forces, acting perpendicular to the cancellous trabeculae, are usually associated with marked instability and displacement, as in the case shown in Fig. 23.6. In this example, the patient's

foot was caught in the jaws of a logging machine and his body rotated around the stabilized os calcis and talus, creating an open shear fracture through both bones.

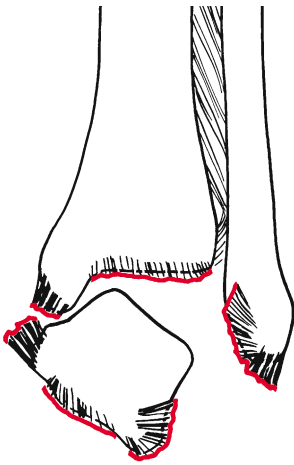
### 23.2.2.3

#### Total Dislocation of the Talus

Total dislocation of the talus is a severe injury usually caused by forced, violent, internal rotation and plantar flexion. As the foot displaces, the anterolateral capsule and the collateral ligaments rupture. Further inversion causes a rupture of the talocalcaneal ligaments allowing the talus to extrude from the ankle mortise, often with rupture of the overlying skin (Fig. 23.7; see also Fig. 23.14).



**Fig. 23.6a–e.** Shearing injury of the talus. This 21-year-old man had his foot caught in the jaws of a logging machine. **a** His body was then rotated around the stabilized os calcis and talus, creating an open shear fracture through both bones. **b** The oblique radiograph of the foot shows the shearing oblique fracture through the talar neck and calcis. **c** Within 48 h, massive fracture blisters and contusion were evident on the foot and ankle. Nonoperative treatment was the only option because of the soft tissue crush. **d,e** The lateral radiograph and the clinical photograph show the final result 5 years following injury. The fractures have healed, but there was evidence of patchy avascular necrosis of the body of the talus with no collapse. The function of the foot is good. An area on the medial aspect of the os calcis required a split-thickness skin graft



**Fig. 23.7.** Total dislocation of the talus with disruption of all soft tissue attachments

## 23.3

### Classification and Natural History

Armed with a knowledge both of the rich blood supply of the talus and also of the mechanisms of injury, it is possible to develop a classification of fractures of the talus of considerable prognostic value. The most widely accepted classification of these fractures is a variation on that originated by Coltart (1952), as shown in Table 23.1. Excluded from this classification are the common avulsion fractures of portions of the talus and fractures of the talar dome – so-called osteochondritis dissecans of the talus – since both of these injuries differ in their behavior from the more uncommon fractures of the body and neck.

Clearly, the outcome of these injuries is dependent upon the type of fracture and the degree of violence causing it. These aspects will also affect the talar blood supply and the degree of subluxation or dislocation of the talar body, the major factors influencing the prognosis of this injury.

**Table 23.1.** Classification of fractures of the talus

Fractures of the talar body
Fractures of the talar neck
Type A: Undisplaced fracture of the talar neck
Type B: Displaced fracture of the talar neck with subtalar joint subluxation
Type C: Displaced fracture of the talar neck with dislocation of the body
Subtalar dislocation
Total dislocation of the talus

#### 23.3.1

##### Fractures of the Body of the Talus

Simple linear cracks in the body should pose few management problems; the results should be uniformly good with simple treatment.

Major violence may cause severe comminution to the body of the talus, usually defying primary reconstruction. Areas of avascular necrosis and marked incongruity of the subtalar and even the ankle joint combine to make this injury potentially disastrous (Fig. 23.8). Late pain, deformity, and collapse of the talus are common, often requiring secondary reconstruction procedures.

#### 23.3.2

##### Fractures of the Talar Neck

#### 23.3.2.1

##### Type A: Undisplaced Fractures of the Talar Neck

Linear fractures of the talar neck with no subluxation of the subtalar joint usually have an excellent prognosis with simple management (Fig. 23.9). Ample blood supply is retained in most cases to maintain the viability of the body, and if the hindfoot is truly anatomical, no biomechanical abnormalities will ensue. All major literature reports confirm this, including the reviews of Coltart (1952), Pennal (1963), Hawkins (1970), and Kenwright and Taylor (1970).

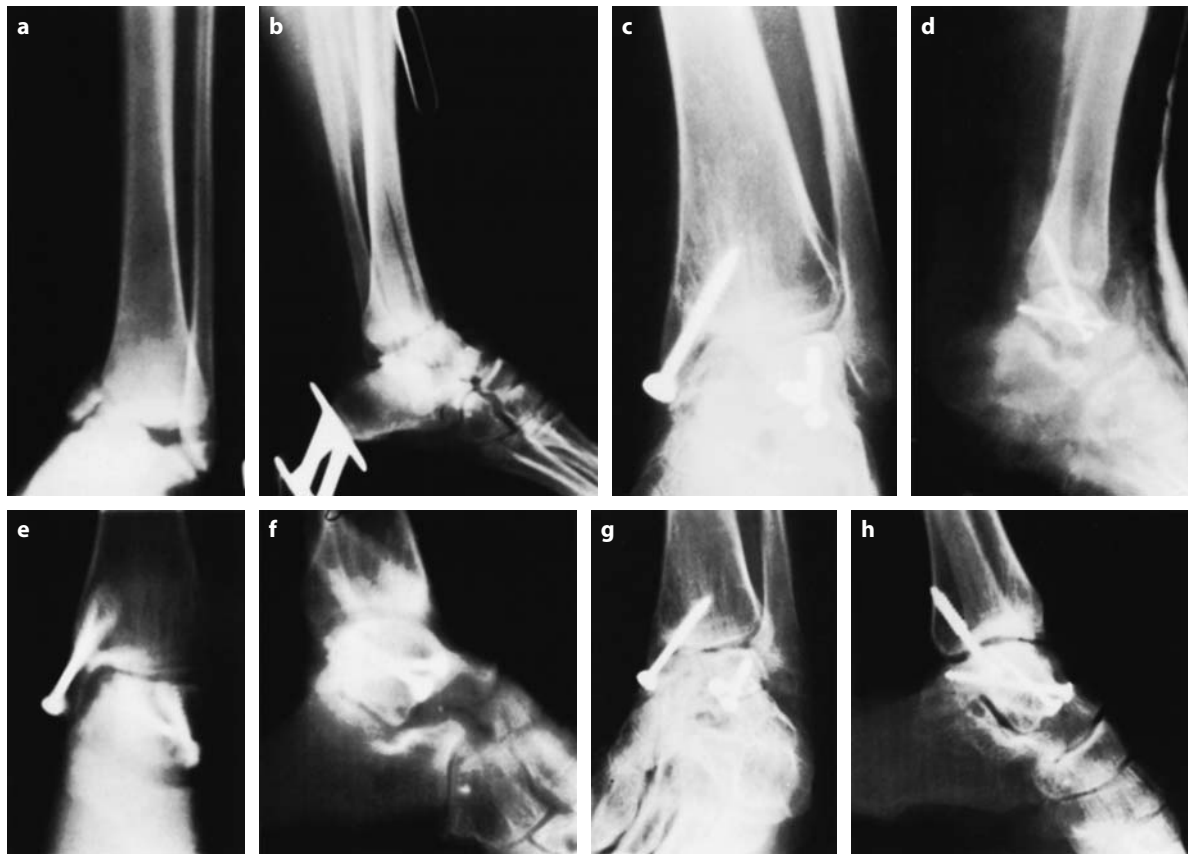#### 23.3.2.2

##### Type B: Displaced Fractures of the Talar Neck with Subluxation of Subtalar Joint

Any degree of displacement of the fracture through the neck of the talus must be accompanied by a corresponding subluxation of the subtalar joint (Fig. 23.10). Most often, the os calcis and the remainder of the foot subluxate medially, thereby preserving the medial soft tissues even if the medial malleolus is fractured. In this particular type of injury, avascular necrosis leading to collapse of the body is uncommon, but anatomical reduction is required to prevent malunion with resultant foot problems.

##### Avascular Necrosis

Although portions of the talar body may become avascular, collapse is rare. The intact medial soft tissue envelope usually retains sufficient vascularity to the body to maintain partial viability. The process of creeping



**Fig. 23.8a–h.** Fracture through the body of the talus. **a,b** Anteroposterior and lateral radiographs of this 19-year-old woman show a comminuted fracture of the talar neck extending through the body, together with a fracture of the medial malleolus. Treatment consisted of open reduction and internal fixation. **c,d** At 3 months, the anteroposterior and lateral radiographs show union of the medial malleolus. The medial aspect of the talus appears vascularized, whereas the lateral aspect of the talus is sclerotic and avascular. **e,f** Anteroposterior and lateral tomography shows a defect in the distal tibia, allowing varus deformation. **g,h** At 5 years, the talus has not collapsed, but shows a patchy avascular necrosis. The patient has restricted ankle motion and minimal discomfort and functions well despite the vascular necrosis

substitution is able to strengthen the dead bone at a speed which more than compensates for the tendency of that bone to collapse (see Figs. 23.8, 23.10).

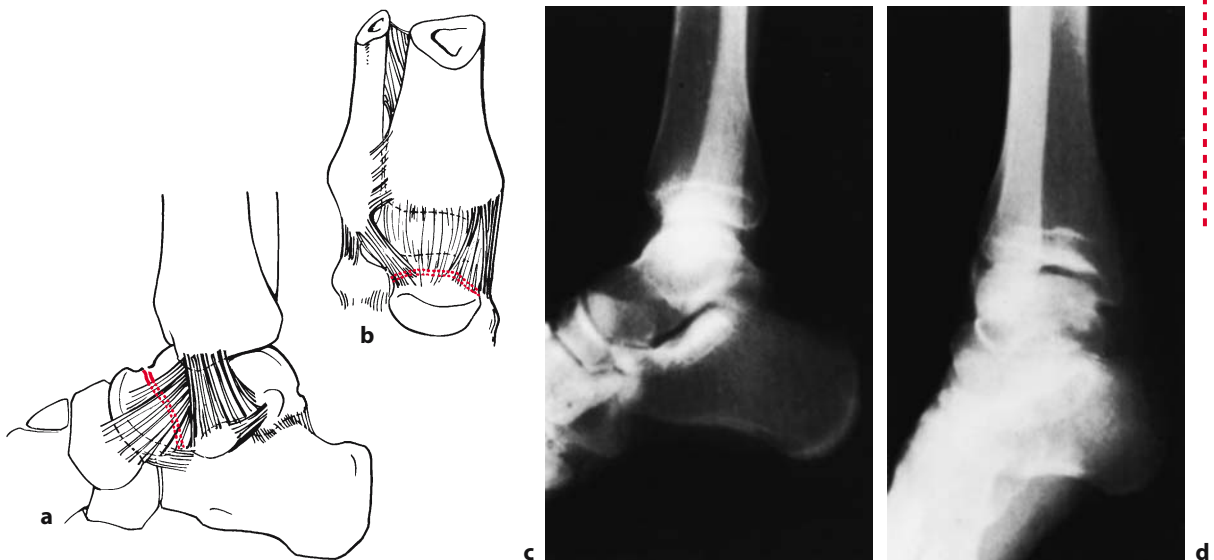
It is wrong to believe that this injury usually results in late problems associated with avascular necrosis. Therefore, aggressive treatment modalities for this injury, such as primary subtalar fusion, should be avoided because the outlook with proper management is favorable. Peterson and Goldie (1975) pointed out in an experimental study that division of the talar neck with displacement disrupted the talar blood supply. However, the clinical reviews are clear on this point: i.e., the majority of cases will not develop clinically significant avascular necrosis. Although the reported incidence of avascular necrosis of the talar body in type B injuries is 20%–50%, all authors agree that most cases proceed to

bony union with no collapse of the avascular bone. Pennal (1963) reported three cases (33%) of patchy avascular necrosis with no collapse, Kenwright and Taylor (1970) four cases (36%) with no collapse, and Hawkins (1970) 42% with no significant collapse. More recent literature supports the above views (Grob et al. 1985; Comfort et al. 1985; Szyzkowitz et al. 1985).

#### **Malunion with Chronic Subtalar Subluxation**

In a type B talar neck fracture, malunion is of greater clinical significance than avascular necrosis. If an anatomical reduction is not obtained and maintained, the neck of the talus will heal in an abnormal position (Fig. 23.11). Of necessity, the subtalar joint will remain chronically subluxated. This in turn





**Fig. 23.9a–d.** Type A: undisplaced fracture of the talar neck. **a** Lateral and **b** anteroposterior diagrammatic views. **c** Lateral and **d** anteroposterior radiographs

causes two major problems leading to a poor result: secondary degenerative arthritis and altered foot mechanics.

**Secondary Degenerative Arthritis of the Subtalar Joint.** This condition may occur early because of the altered joint biomechanics, and is the most frequent cause of unsatisfactory results in type B injuries. Of Pennal's ten cases, the six treated nonoperatively developed these changes, whereas the four treated operatively did not.

**Altered Foot Mechanics.** If the talar neck heals in the malunited position, the subluxated os calcis at the subtalar joint is usually displaced inwards. Since the remainder of the foot rotates around the subtalar axis through the talar neck and the os calcis, the net effect is a varus heel and foot (Fig. 23.11b). The normal plantigrade position of the foot is lost, markedly altering the patient's gait pattern.

Therefore, if the talar neck fracture is not anatomically reduced by closed means, open reduction and internal fixation are absolutely imperative.

### 23.3.2.3

#### **Type C: Displaced Fractures of the Talar Neck with Posterior Dislocation of the Body**

Avascular necrosis of the body is inevitable in these injuries (Fig. 23.12) and plays the major role in determining the outcome. The incidence of avas-

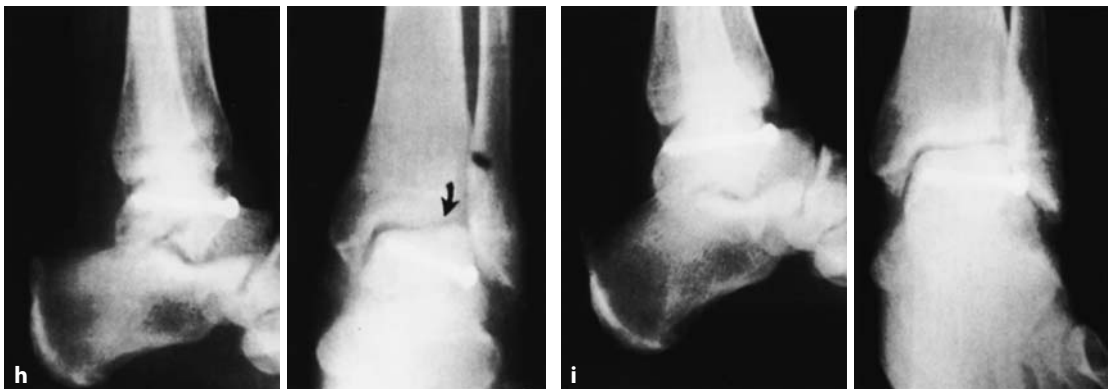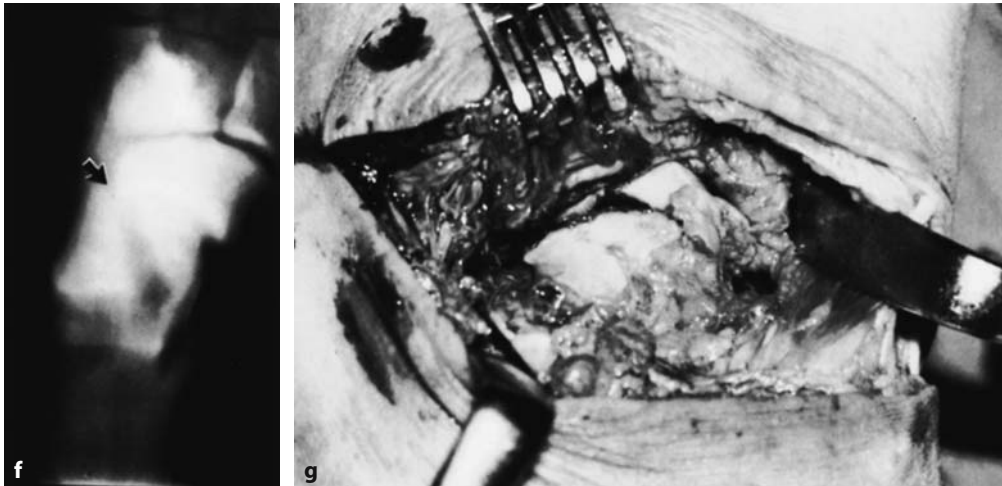
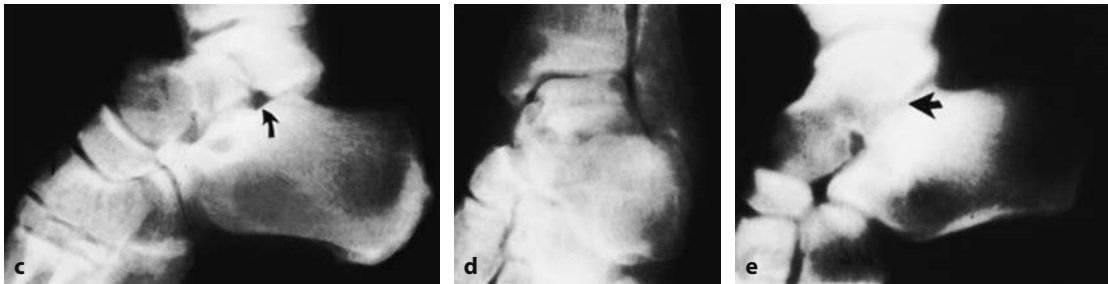
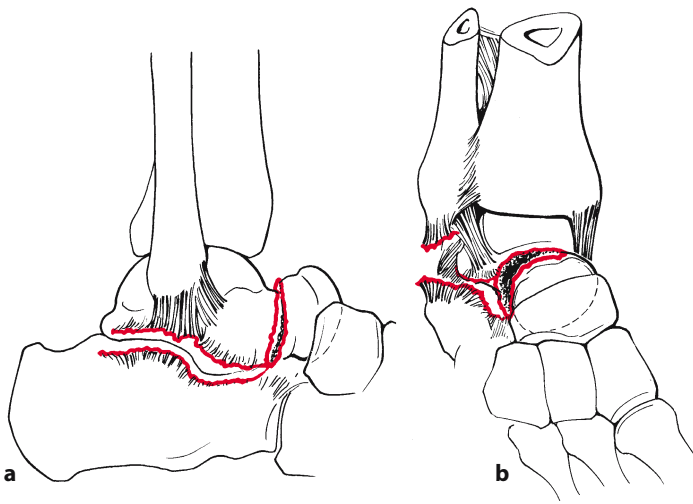
cular necrosis approaches 100%, the occasional exception being those cases which retain the deltoid ligament attachment to the talus. I have seen this ligament retained even in an open fracture, as illustrated in Fig. 23.12c–h. Pennal (1963) reported avascular necrosis in 14 out of 14 cases (100%); however, in one it was patchy in nature. Kenwright and Taylor (1970) reported three out of four (75%) with surprisingly good results. Hawkins reported 18 out of 20 (90%), with three nonunions. Treatment of this injury by all methods resulted in only three satisfactory results. None of the attempts to revascularize the talus early showed any significant effect; therefore, the ultimate prognosis for this injury must be guarded.

Even more sinister is the open type C fracture, in Hawkins' series 50% of the total.

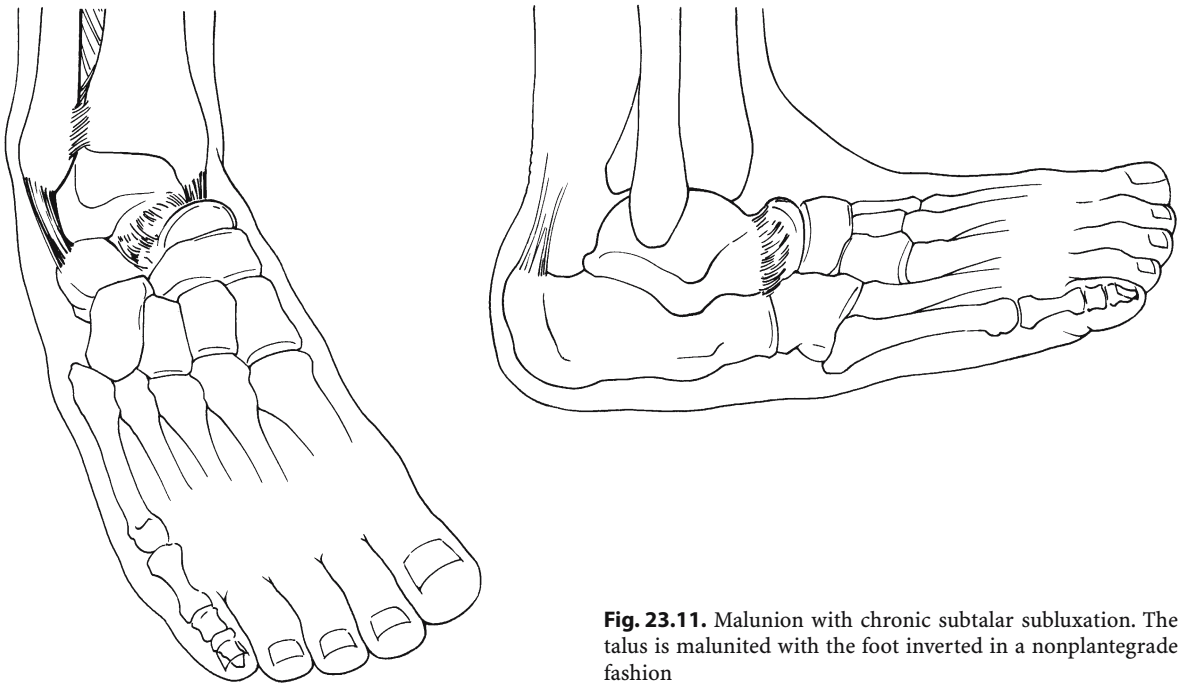
### 23.3.3

#### **Subtalar Dislocation**

This injury (Fig. 23.13), if reduced quickly and anatomically, usually results in good function of the foot and no avascular necrosis of the talus. Late osteoarthritis of the subtalar joint may occur in some cases.



**Fig. 23.10a-i.** Type B: displaced fracture of the talar neck with subluxation of the subtalar joint. **a,b** Displaced talar neck fracture. The foot is displaced dorsally and medially with disruption of the lateral subtalar ligament and lateral ligament of the ankle. Note the subtalar subluxation. **c,d** Lateral and anteroposterior radiographs of a 43-year-old man showing a comminuted oblique fracture of the talar neck extending posteriorly into the body. The arrow shows the subtalar subluxation. **e** This is clearly seen in the lateral tomograms (*arrows*). **f** Anteroposterior tomogram showing the oblique nature of the fracture (*arrow*). **g** This was confirmed at the time of surgery. Through a lateral approach, the fracture was reduced and internally fixed with a single cancellous bone screw. **h** The anatomical appearance is shown in the lateral and anteroposterior radiographs. At 10 weeks, no evidence of radiolucency is noted in the talus, indicating avascular necrosis (*arrow*). **i** At 62 weeks, increased density is still noted in the talus, but there is no evidence of collapse. The patient's talar body never collapsed, and he has gone on to an excellent long-term result



**Fig. 23.11.** Malunion with chronic subtalar subluxation. The talus is malunited with the foot inverted in a nonplantigrade fashion

### 23.3.4

#### Total Dislocation of the Talus

This injury (Fig. 23.14) is usually caused by violent inversion forces, completely extruding the talus laterally. Most often, the dislocation is open. Usually, all soft tissues are stripped from the bone, and therefore avascular necrosis is certain. Sepsis and skin necrosis are common in the open injury. Of Pennal's ten cases, two required tibiocalcaneal fusion and one an amputation. Detenbeck and Kelly (1969), reporting on nine

such cases, of which seven were open, failed to reduce the dislocation closed in all cases. Their dismal results emphasize the seriousness of this injury:

- Eight of nine patients developed sepsis.
- Seven of nine patients required talectomy, five with tibiocalcaneal fusion.
- Nine of nine patients required an amputation for sepsis.

Therefore, this injury has the greatest potential for disaster; often that potential is realized.

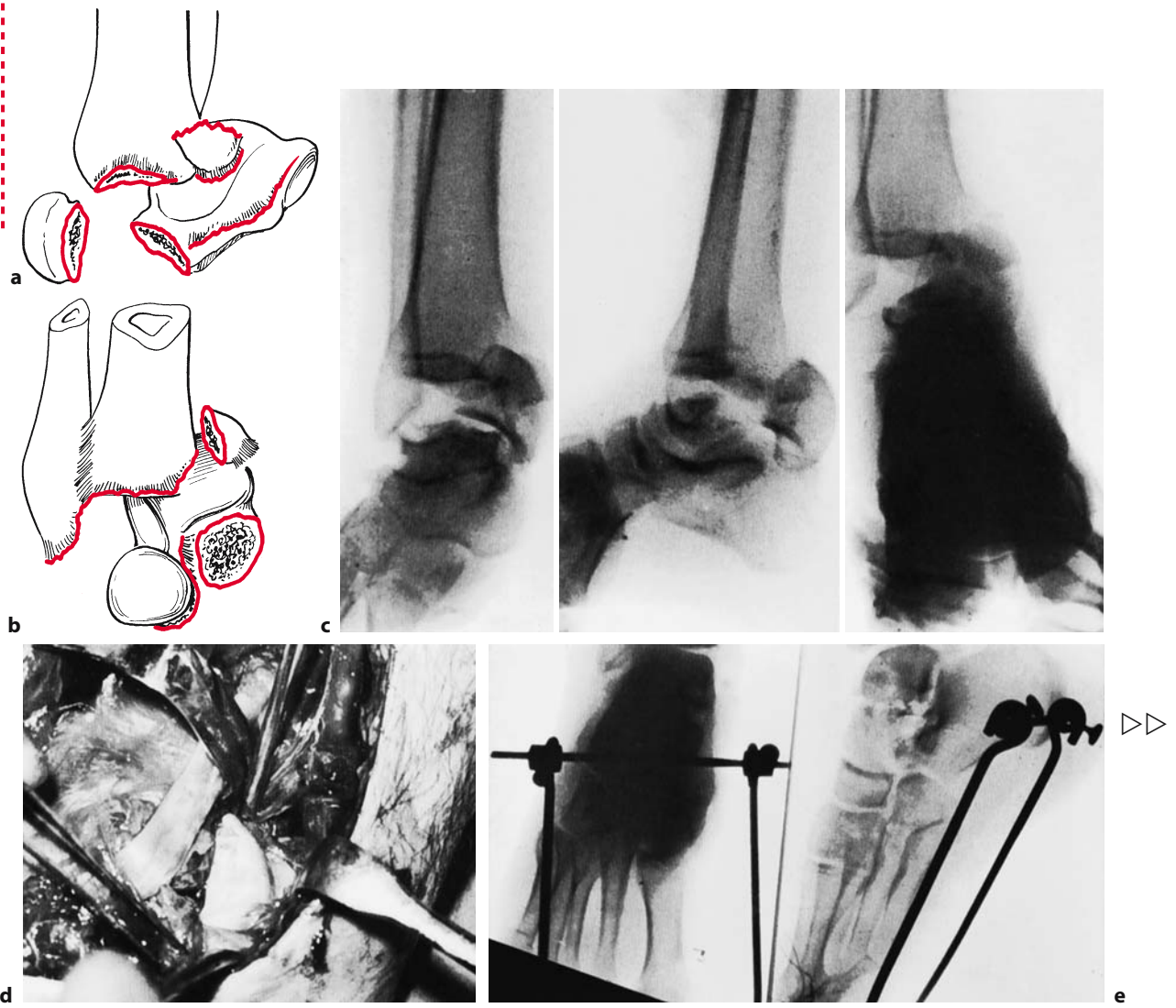


Fig. 23.12. a-h

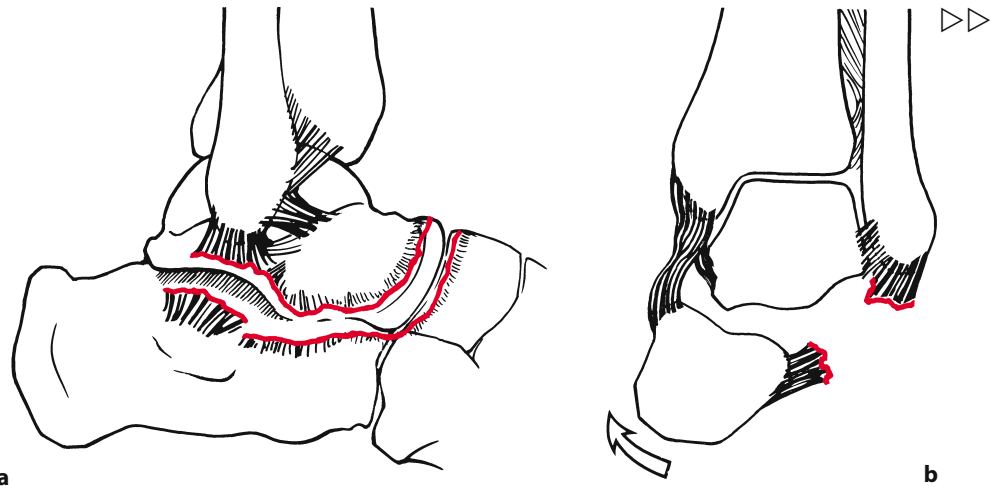
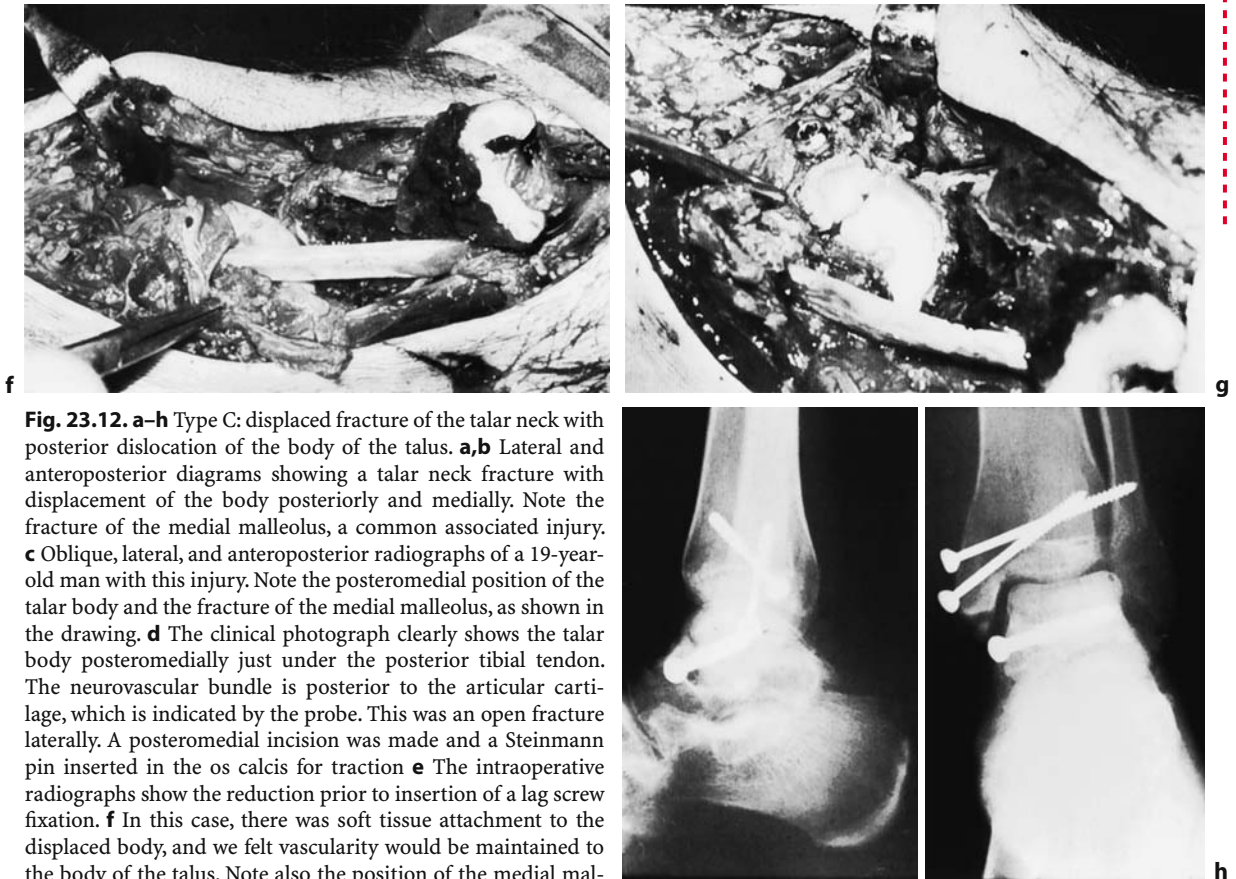
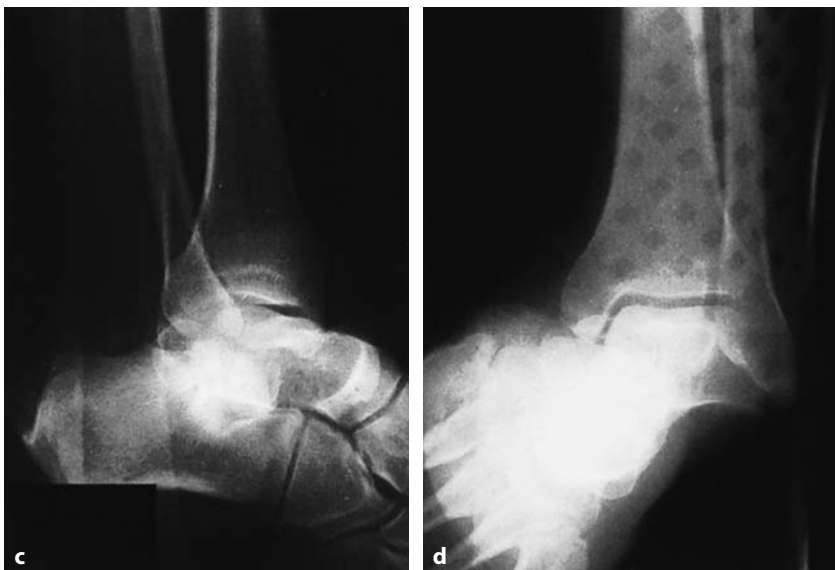

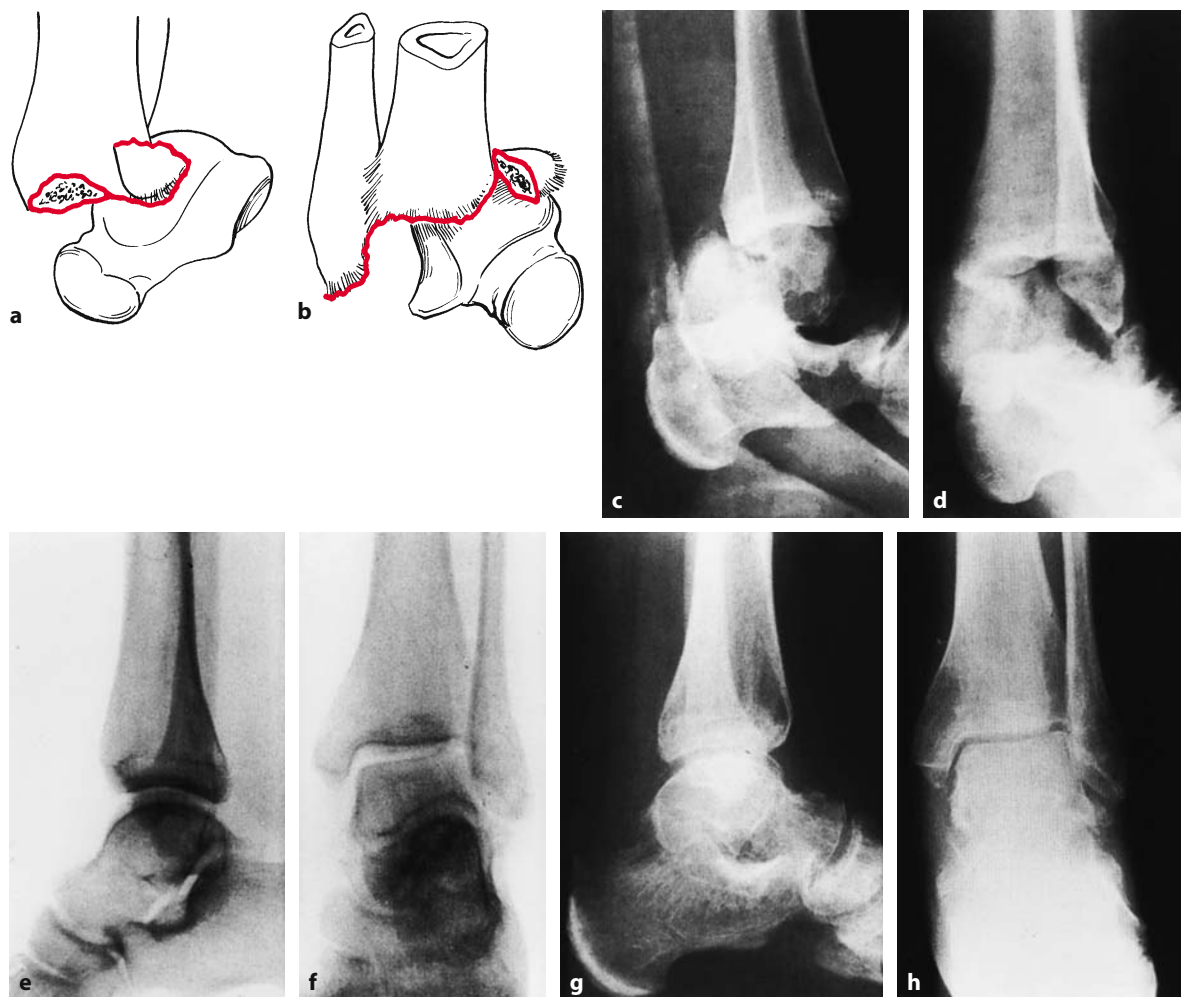
Fig. 23.13a-d.



**Fig. 23.12. a–h** Type C: displaced fracture of the talar neck with posterior dislocation of the body of the talus. **a,b** Lateral and anteroposterior diagrams showing a talar neck fracture with displacement of the body posteriorly and medially. Note the fracture of the medial malleolus, a common associated injury. **c** Oblique, lateral, and anteroposterior radiographs of a 19-year-old man with this injury. Note the posteromedial position of the talar body and the fracture of the medial malleolus, as shown in the drawing. **d** The clinical photograph clearly shows the talar body posteromedially just under the posterior tibial tendon. The neurovascular bundle is posterior to the articular cartilage, which is indicated by the probe. This was an open fracture laterally. A posteromedial incision was made and a Steinmann pin inserted in the os calcis for traction **e** The intraoperative radiographs show the reduction prior to insertion of a lag screw fixation. **f** In this case, there was soft tissue attachment to the displaced body, and we felt vascularity would be maintained to the body of the talus. Note also the position of the medial malleolar fracture. **g,h** The talar fracture was fixed with a single screw, as shown in the clinical photograph and the postoperative radiograph. At 8 weeks, there is a clear radiolucent line along the dome of the talus, indicating vascularity. The patient developed a patchy avascular necrosis with no collapse



**Fig. 23.13a–d.** Subtalar dislocation. **a,b** Lateral and anteroposterior diagrammatic views of a complete subtalar dislocation. Note the disruption of the subtalar and lateral ligaments. **c,d** Lateral and anteroposterior radiographs of subtalar dislocation



**Fig. 23.14a–h.** Total dislocation of the talus. **a,b** Lateral and anteroposterior diagrams showing a complete dislocation of the talus with a fracture of the medial malleolus. **c,d** This injury is clearly seen on the lateral and anteroposterior radiographs of a 29-year-old man involved in a motor vehicle accident. Closed reduction failed to reduce the total dislocation of the talus, and therefore open reduction was necessary. **e,f** The intraoperative Polaroid radiographs indicated the reduction. **g,h** At 6 months, patchy avascular necrosis is evident, but no collapse occurred

## 23.4

### Management

#### 23.4.1

##### Assessment

Prior to instituting management of the fracture, a careful assessment is mandatory.

##### 23.4.1.1

###### Clinical Assessment

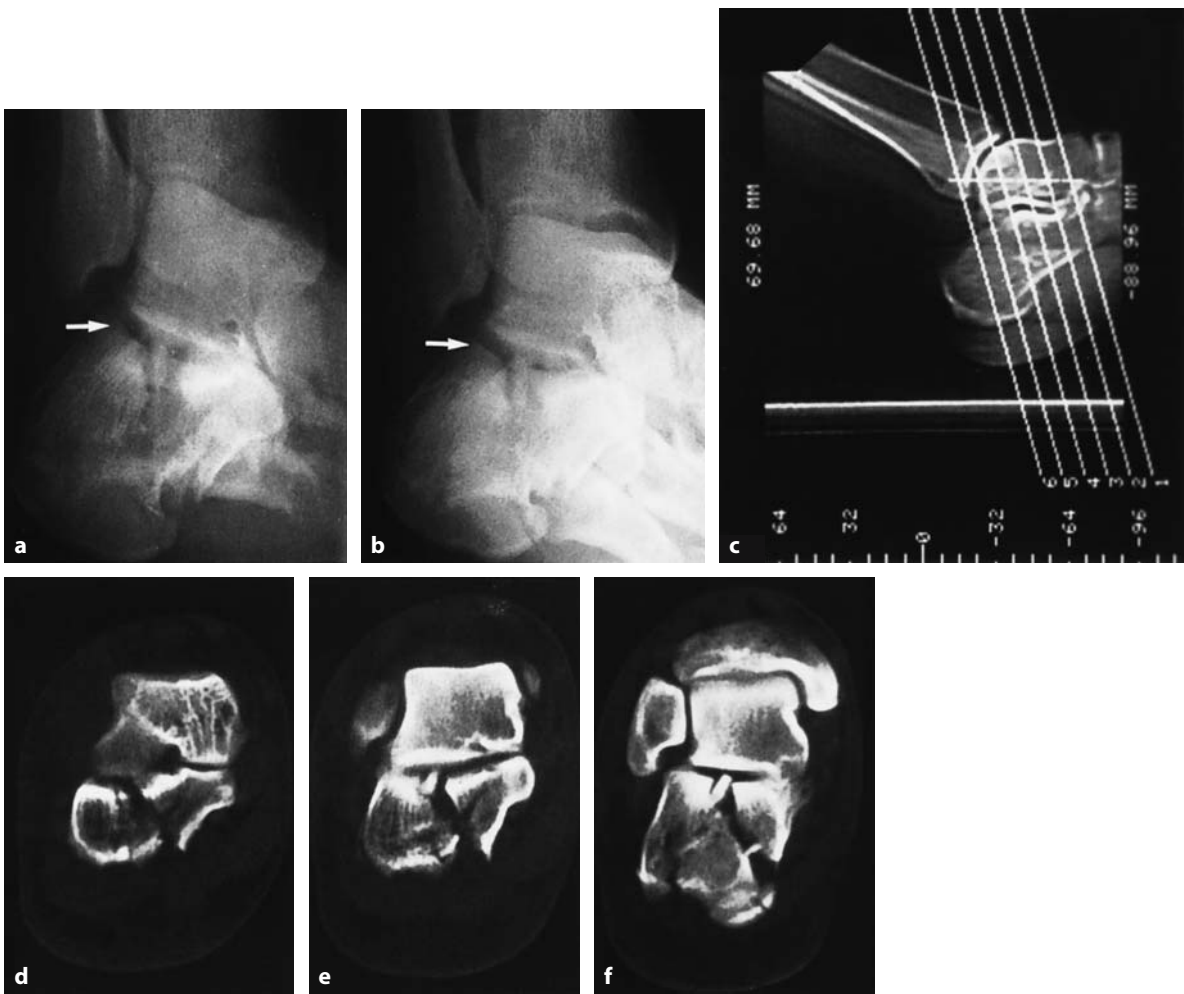
As always, a complete medical history and physical examination are essential in order to reveal the mech-

anism of injury, the general medical profile of the patient, and the state of the limb. Of great importance is the state of the soft tissues, either the presence of an open wound or, if the wound is closed, the presence of severe skin damage heralding the early onset of fracture blisters and necrosis. Injudicious surgery through such skin may prove disastrous.

##### 23.4.1.2

###### Radiological Assessment

Standard views of the hindfoot should be supplemented with tomograms and special views, in order to clearly outline the subtalar joint. Standard views include an anteroposterior, a lateral, and two oblique views of the



**Fig. 23.15a–f.** Broden's view of the subtalar joint. **a,b** The subtalar joint is best seen on Broden's view (*arrows*). In this case, an os calcis fracture, the precise relationship between the talus and os calcis can be seen. **c–f** CT scans of the same patient. Again, note the relationship between the os calcis and the talus

foot (see Fig. 23.12). Tomograms are in our opinion invaluable (as they are in other fractures) for revealing comminution of the neck and body and incongruity of the subtalar joint (see Fig. 23.10e, f). Broden's view (Broden 1949) is excellent for viewing the subtalar joint, especially after a closed reduction (Fig. 23.15a,b). Computed tomograms (CT) of the foot will afford excellent visualization of the fracture pattern, as well as the degree of comminution (Fig. 23.15c–e).

### 23.4.2

#### Decision-Making

Careful assessment will reveal the personality of the injury. Following this, the management should become logical.

### 23.4.2.1

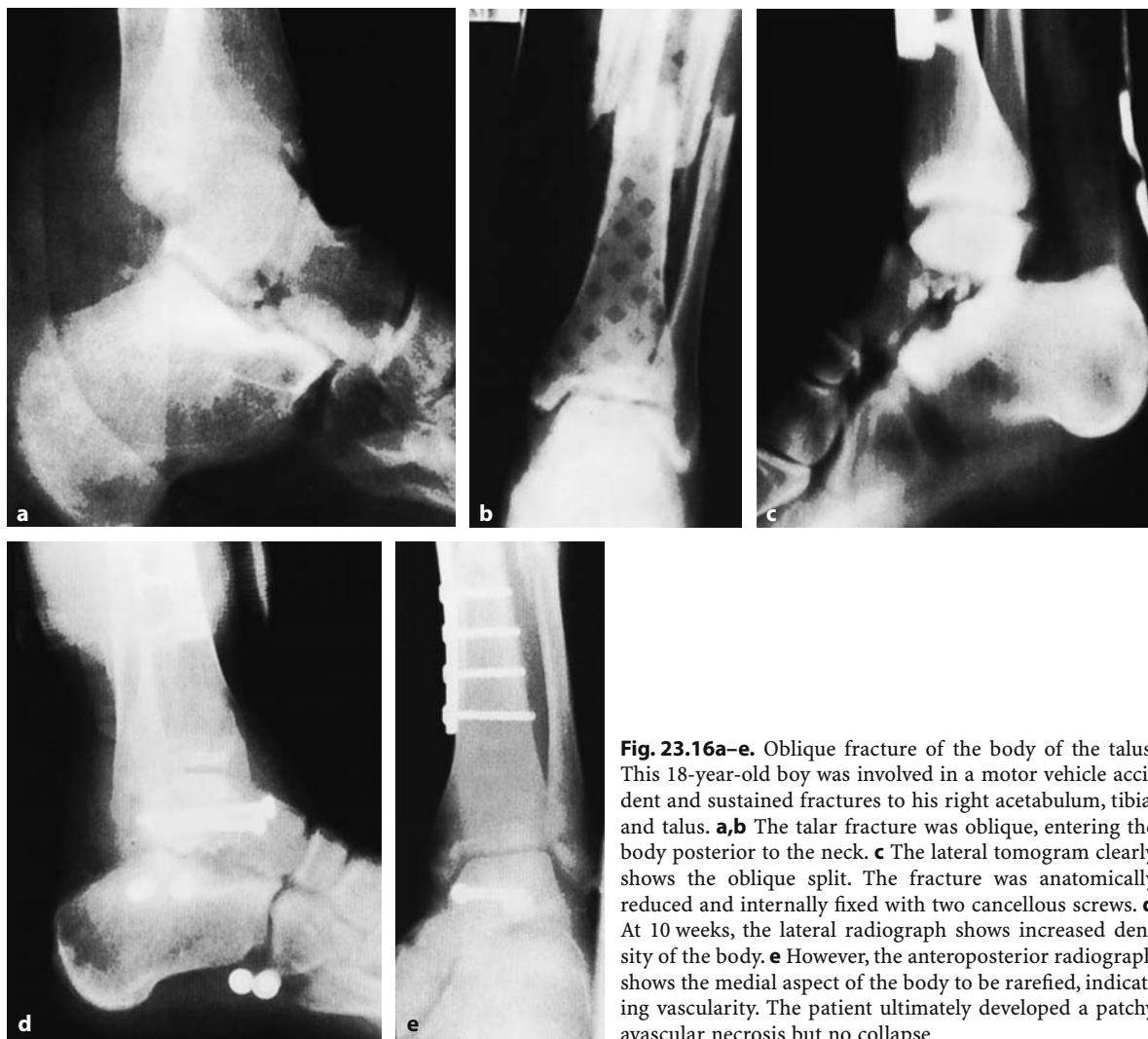
#### Fractures of the Body

##### *Undisplaced Fractures*

For fractures of the body only symptomatic treatment is required, usually a below-knee cast for 6–8 weeks. A good result may be expected.

##### *Displaced Fractures*

If the fracture is comminuted and displaced, as is all too often the case, the surgeon must assess whether it can be operatively stabilized. If the body is split, it may be possible to perform an open reduction and stable internal fixation using cancellous screws (Fig. 23.16). If the body is completely shattered, the



**Fig. 23.16a–e.** Oblique fracture of the body of the talus. This 18-year-old boy was involved in a motor vehicle accident and sustained fractures to his right acetabulum, tibia, and talus. **a,b** The talar fracture was oblique, entering the body posterior to the neck. **c** The lateral tomogram clearly shows the oblique split. The fracture was anatomically reduced and internally fixed with two cancellous screws. **d** At 10 weeks, the lateral radiograph shows increased density of the body. **e** However, the anteroposterior radiograph shows the medial aspect of the body to be rarefied, indicating avascularity. The patient ultimately developed a patchy avascular necrosis but no collapse

surgeon may immobilize the foot until pain subsides and then begin a rehabilitation program. Most often, the patient will require a secondary reconstructive procedure, such as a tibiocalcaneal fusion.

As an alternative for the worst cases, we favor primary excision of the body of the talus and either a Blair-type fusion (Crenshaw 1971, p. 502) or tibiocalcaneal fusion. This procedure should only be performed through skin that has healed sufficiently to avoid necrosis.

#### 23.4.2.2

#### Fractures of the Talar Neck

##### *Type A Fractures*

If an assessment of the injury indicates an undisplaced linear type fracture through the talar neck,

i.e., a type A injury, simple treatment consisting of immobilization in a plaster cast until the fracture is healed (usually 6–8 weeks) is adequate. The expected result of such treatment is a healed fracture in perfect position, with no abnormality of the subtalar joint. Avascular necrosis is a rarity, and late secondary arthritis of the subtalar joint is also uncommon.

A word of warning, however: the assessment of the subtalar joint must be extensive and accurate and must include all of the radiographic views mentioned above. If there is any question about displacement of the subtalar joint, the injury should be considered a type B injury, which requires anatomical reduction.

##### *Type B Fractures*

If the fracture of the talar neck is associated with a subluxation of the subtalar joint (type B fracture),



anatomical restoration of the neck is essential to restore congruity to the subtalar joint, which, in turn, will restore the normal plantigrade position of the foot. A closed reduction with general anesthesia may accomplish this task. However, it is again essential that the closed reduction of the talar neck is absolutely anatomical. In our opinion, this is rarely accomplished, so that a common final result with such fractures treated nonoperatively is malunion and chronic subluxation of the subtalar joint (see Fig. 23.10).

In order to avoid this, we recommend early anatomical open reduction and internal fixation of this injury, if the patient's general state allows. This injury should be considered like any other fracture-dislocation of a weight-bearing joint, of which anatomical open reduction and stable internal fixation are the hallmarks of treatment.

If the surgical approach does not interfere with the remaining medial blood supply, significant avascular necrosis will be rare. Furthermore, since the anatomical reduction of the subtalar joint restores congruity between the dome of the os calcis and the talus, secondary problems in that joint and in the foot will be avoided, resulting in a satisfactory outcome.

In a type B injury there is no indication for primary subtalar fusion in an attempt to restore blood flow to the body of the talus, since the flow is usually ample.

### **Type C Fractures**

A fracture of the talar neck with dislocation of the talar body (i.e., type C: see Fig. 23.12), whether open or closed, constitutes a surgical emergency. The extruded body lies posterior to the medial malleolus. Although the neurovascular bundle is rarely injured primarily, pressure on these structures may cause secondary nerve injury or vascular impairment, either arterial or venous. It is therefore urgent that the body of the talus be reduced.

Even under general anesthesia and with a pin inserted in the os calcis, less than 10% of these injuries can be reduced closed, so little time should be wasted with this maneuver. One or two attempts under image intensification should convince the surgeon that open reduction will be necessary.

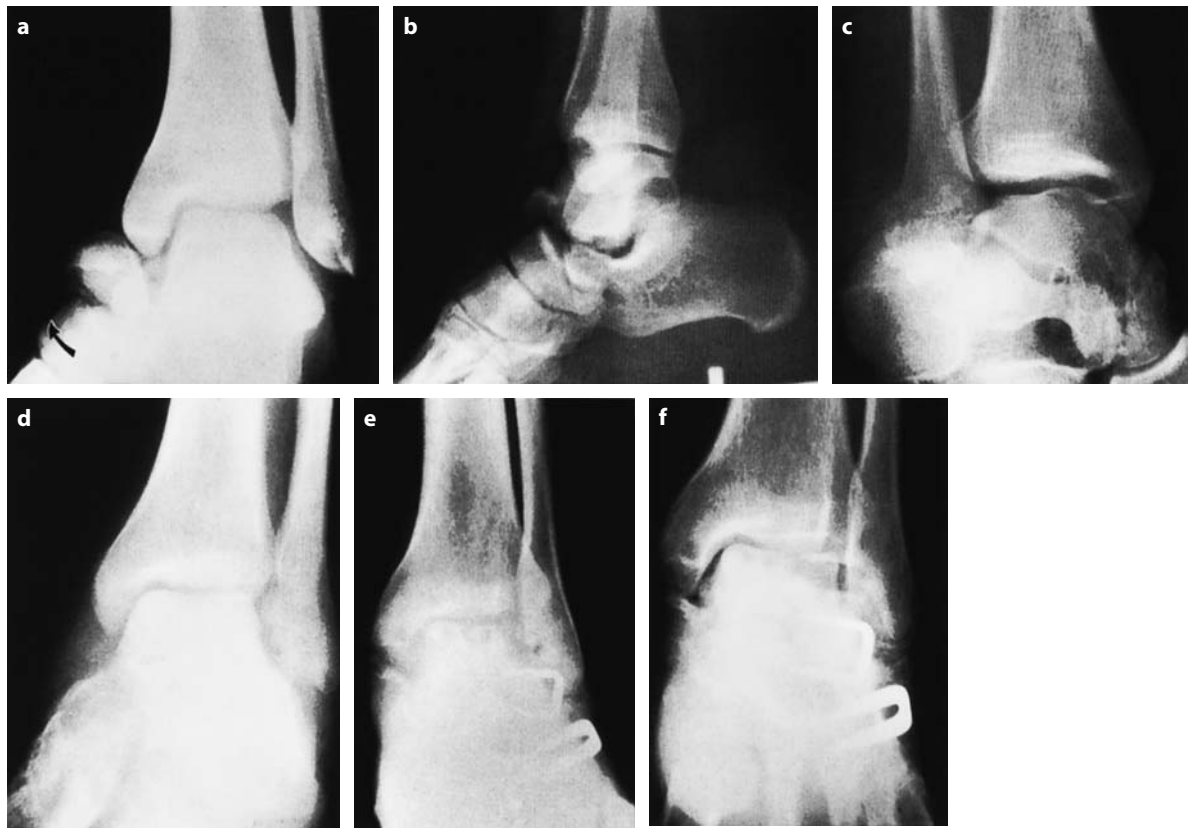Since more than 50% of patients with this injury have an associated fracture of the medial malleolus, open reduction should be performed medially by turning down the bony fragment (see Fig. 23.12). Care should be taken to preserve any medial soft tissue attachment to the body of the talus, as this may

be its only remaining blood supply. Reduction of the body of the talus is then performed manually. This may be a difficult task, requiring full reenactment of the injury in forced dorsiflexion with a Steinmann pin in the os calcis for traction.

Once the body of the talus has been restored to its normal position, the talar neck fracture should then be stably fixed with cancellous lag screws. We favor stable internal fixation, even in cases where the body is free of all soft tissue, unless the body is comminuted or contamination of the wound would make sepsis likely in an open fracture. In those cases, the body of the talus should be discarded and a Blair-type fusion (Crenshaw 1971, p. 502) or a tibiocalcaneal fusion should be performed at the earliest safe opportunity.

**Revascularization of the Talus.** Is there any method now available to increase the blood supply to an avascular talar body? Phemister (1940) experimentally denuded the articular cartilage from the talus and found that the bone could then be revascularized much more quickly than if the articular cartilage remained. This led some surgeons to perform primary subtalar fusion in an effort to enhance the blood supply to the talar body and prevent collapse of that structure. Sporadic reports in all of the published papers do not support the clinical application of this basic principle. The results are very unpredictable, and therefore the method cannot be recommended at this time (Fig. 23.17).

Perhaps in the future direct microvascular techniques to restore the arterial supply of the talus will become possible and will eliminate avascular necrosis. An example of a direct repair of a posterior tibial artery leading to a good result in an open talar dislocation is seen in Fig. 23.18. Until vascular repair is more common, tibiocalcaneal fusion, giving a good stable hindfoot, or fusion from the tibia to the talar head (Blair fusion) are better than talectomy, except in cases of total dislocation of the talus. The condition of the talus in this injury – usually open and completely devoid of all blood supply – is such that it cannot safely be salvaged. Attempts to do so have led to an extremely high rate of sepsis and amputation. “Suitable” treatment would consist of total excision of the talus, either as definitive treatment or combined with a primary or a delayed primary tibiocalcaneal fusion. If sepsis can be avoided by proper soft tissue management, the final result should be satisfactory.



**Fig. 23.17a–f.** Avascular necrosis of the talus. **a** Anteroposterior, **b** lateral, and **c** oblique radiographs show a fracture through the talar neck with displacement (*arrow* in **a**). **d** At 24 weeks, the anteroposterior radiograph shows a dense sclerotic talar body. At this time, a triple arthrodesis was performed in an attempt to bring vascularity to the body of the talus. **e** At 2 years and **f** 3 years, some degree of collapse of the body is noted. The patient subsequently required further reconstructive surgery and had a poor result

### 23.4.3

#### Surgical Technique

##### 23.4.3.1

##### Timing

The timing of the operative procedure, if operating is indicated, is of vital importance. Obviously, if the fracture is open, immediate surgery is indicated. However, if the fracture is closed, careful assessment and planning are required. Dislocation of the body of the talus or the entire talus constitutes a surgical emergency, and if closed reduction does not succeed, immediate open reduction is called for. The soft tissues must be handled with extreme care. In this situation the wound, if under tension, must be left open.

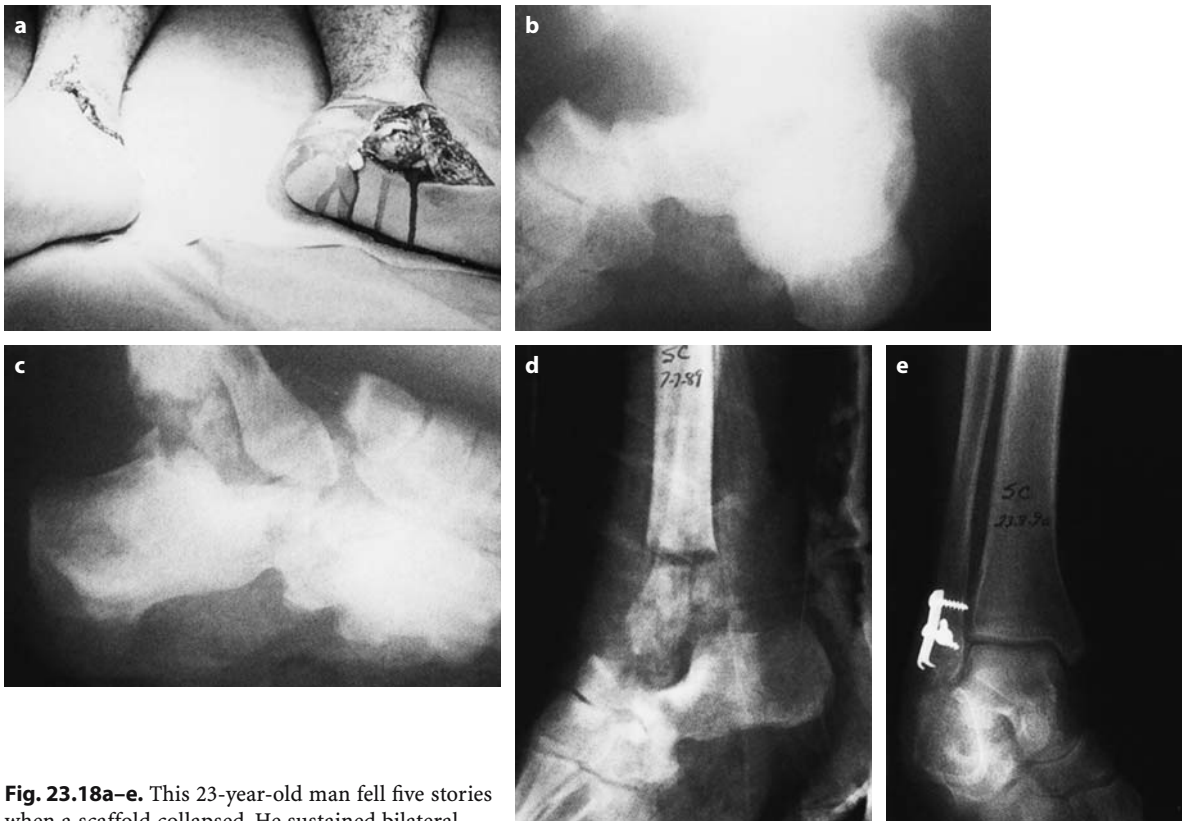In a type B fracture-dislocation, the surgeon has more leeway. If the skin is obviously traumatized, surgery should be delayed until the swelling has sub-

sided and the skin improves. Incisions should never be made through areas of fracture blister, since the inevitable outcome will be skin necrosis and sepsis (see Fig. 23.6c). In such cases, the fracture subluxation should be reduced closed, the extremity elevated, and surgery delayed until local conditions are safe.

##### 23.4.3.2

##### Antibiotics

In this area, we favor the use of prophylactic antibiotics, administration of which should be started prior to the operative procedure. A single intravenous dose of 1 g cefazolin at the time of induction of narcosis, prior to inflation of the tourniquet, will be adequate and should be used for 48 h postoperatively.



**Fig. 23.18a–e.** This 23-year-old man fell five stories when a scaffold collapsed. He sustained bilateral open talar dislocations. **a** The talus has been reduced on the right side back into the ankle mortise. On the left side the entire talus is out through the incision. **b** The dislocated talus on the right. Virtually the entire tibia plafond was missing and was on the roadway. **c** On the left side the dislocation is noted. **d** The missing distal tibia is noted. The patient subsequently had a below-knee amputation on that side. On the left side the posterior tibial artery was disrupted. This was repaired directly and the distal fibula fixed. **e** Six months following injury there is radial lucency in the talus indicating vascularity. There was still some soft tissue attachment on the medial side. Re-suture of the posterior tibial artery revascularized the talus through its deltoid branch

### 23.4.3.3

#### Tourniquet

In order to achieve an accurate anatomical reduction of the femoral neck, use of a tourniquet, though not mandatory, is desirable.

### 23.4.3.4

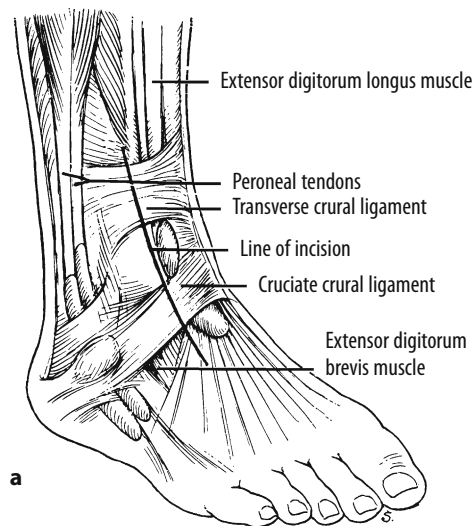
#### Skin Approaches

The skin on both the medial and lateral aspects of the foot is extremely delicate and must be handled with great care to avoid skin breakdown. The approach to each individual fracture will be dictated by the conditions of the case. Important factors are the type of fracture, the presence or absence of an open wound, and the presence of a medial malleolar fracture.

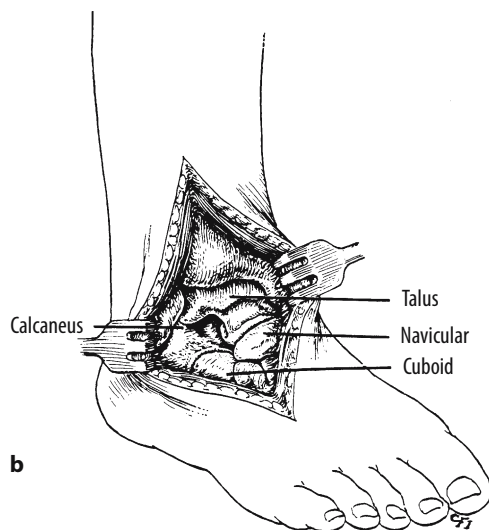
#### Lateral Approach

If there is no fracture of the medial malleolus, we favor the lateral approach to the talar neck. Two incisions are possible: anterolateral longitudinal (Fig. 23.19a) and lateral oblique.

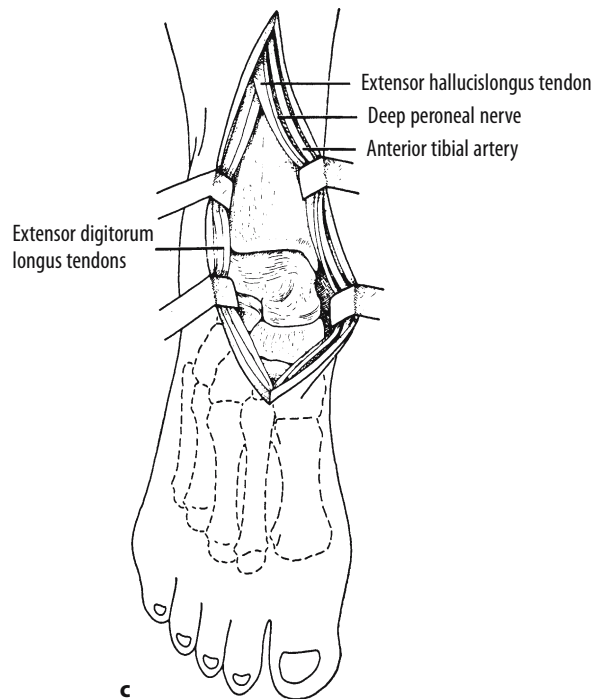
The anterior incision is safe and physiological. Unlike the lateral oblique incision, it rarely causes skin breakdown, and for this reason we strongly favor it. In the anterolateral approach, the extensor tendons and neurovascular structures are retracted medially and the ankle joint capsule is divided, allowing exposure of the entire talus (Fig. 23.19b). Access may also be gained through the interval between the extensor hallucis longus tendon together with the neurovascular bundle medially and the extensor digitorum longus tendons laterally (Fig. 23.19c), but the advantage of the increased medial exposure through this route is offset by the risk of damage to the neurovas-



a



b



c

**Fig. 23.19a–c.** Anterolateral approach to the talus. **a** Incision lateral to the extensor digitorum longus muscle. **b** Access to the talus by dividing the anterior capsule of the ankle and talonavicular joint. Extension of the incision will allow full view of the talar neck and body. **c** Alternative access to the talus may be gained through a portal between the extensor digitorum longus tendon and the extensor hallucis longus tendon with the neurovascular bundle retracted medially. (Reproduced with permission from Crenshaw 1980)

cular structures, and the lateral portal is therefore preferred.

The oblique lateral incision (Fig. 23.20) affords excellent exposure but is more apt to lead to skin breakdown and should be avoided unless access to the posterior aspect of the talus is required. This approach follows the skin lines obliquely across the talar neck, ending posterior to the fibular malleolus.

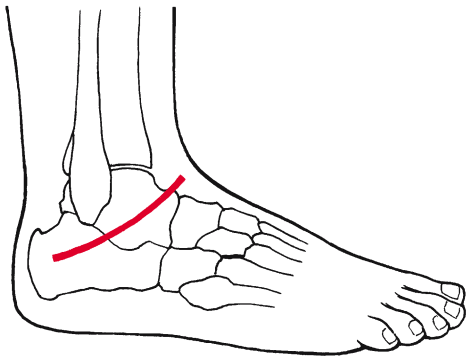
The major advantages of these lateral approaches are twofold. First, the lateral is the easiest approach to the fracture of the talar neck, since simple division of the skin and subcutaneous tissues usually leads one directly into the fracture site, as most of the deep capsular structures are torn. Second, a lateral incision avoids damage to the deltoid artery, which may be present with an intact deltoid ligament. In some cases, this may be the only blood supply to

the body of the talus, and medial approaches could damage it.

If increased exposure is required on the lateral side, a transverse osteotomy of the fibula may be carried out at the level of the mortise. Full access can then be obtained to the body of the talus. At the end of the procedure, the malleolus can be fixed with a malleolar screw through predrilled holes.

### Medial Approach

If the medial malleolus is fractured, or if the body of the talus is posteriorly dislocated, a medial approach is indicated. A longitudinal incision is made just anterior to the medial malleolus, extending distally across the talar neck, curving slightly posteriorly, long enough to give access to both the talar neck



**Fig. 23.20.** Oblique lateral approach to the talus. (Adapted from Crenshaw 1971)

and the ankle joint. The medial malleolus should be retracted posteriorly. Great care must be taken to preserve the attachment, if any, of the deltoid ligament to the malleolus and the talus. If reduction of the dislocated body is difficult, a Steinmann pin should be inserted into the calcaneus so that traction may be applied. At the end of the procedure, the medial malleolus should be fixed back with malleolar screws or tension band wires.

#### 23.4.3.5

##### Stable Internal Fixation

Whether the lateral or medial approach is chosen, stabilization of the fracture is the same. As always, it is extremely important to operate through the fracture site, great care being taken to preserve all soft tissue attachments. This is especially important in comminuted fractures. The talar neck should be reduced anatomically and provisionally fixed with 2.0-mm Kirschner wires. In cases of extreme comminution, the Kirschner wires will serve as definitive fixation, but in all cases it is preferable to fix the fracture with lag screws under compression; this is usually possible from either the medial or the lateral side. The preferable screws are 4.0-mm cancellous lag screws, which may be inserted either retrograde or antegrade depending on the incision used; two or three screws are usually adequate. (Fig. 23.21; see also Figs. 23.10, 23.12, 23.16). Biomechanically, retrograde screws offer better stability but are technically more difficult to insert (Swanson et al. 1992). Cannulated cancellous screws, which may be inserted over the Kirschner wires, are helpful in this situation. In some cases of extreme comminution, a bone graft will be required to fill the gap. In all cases, the subtalar joint should be exposed to ensure perfect congruity. Occa-

sionally, with severe comminution, a small buttress plate is required to maintain anatomic reduction (Fig. 23.22).

The cancellous fracture fixed with interfragmental compression should heal rapidly in an anatomical position.

After an osteotomy of the lateral malleolus, or if the medial malleolus is fractured, the bones affected should be stabilized using standard techniques.

Osteotomy of the medial malleolus is hazardous, and may lead to avascular necrosis, if the remaining blood supply, which runs along the inside of the deltoid ligament (see Figs. 23.2–23.4) is interrupted (Fig. 23.23).

#### 23.4.3.6

##### Postoperative Care

##### Wound Closure

In dealing with open fractures, it is best to leave the lacerated portion of the wound open. Many wounds, even in closed fractures, will be under extreme tension. In these cases, no attempt should be made to close the wound. Areas of sensitive tissue, such as tendon, should ideally be covered, but in some instances it is better even to leave the joint open than to attempt closure under tension. If possible, the patient may return to the operating room on the fifth day for wound closure or skin graft. A bulky dressing with a plaster splint immobilizing the foot in neutral rotation and the ankle at 90° should be applied.

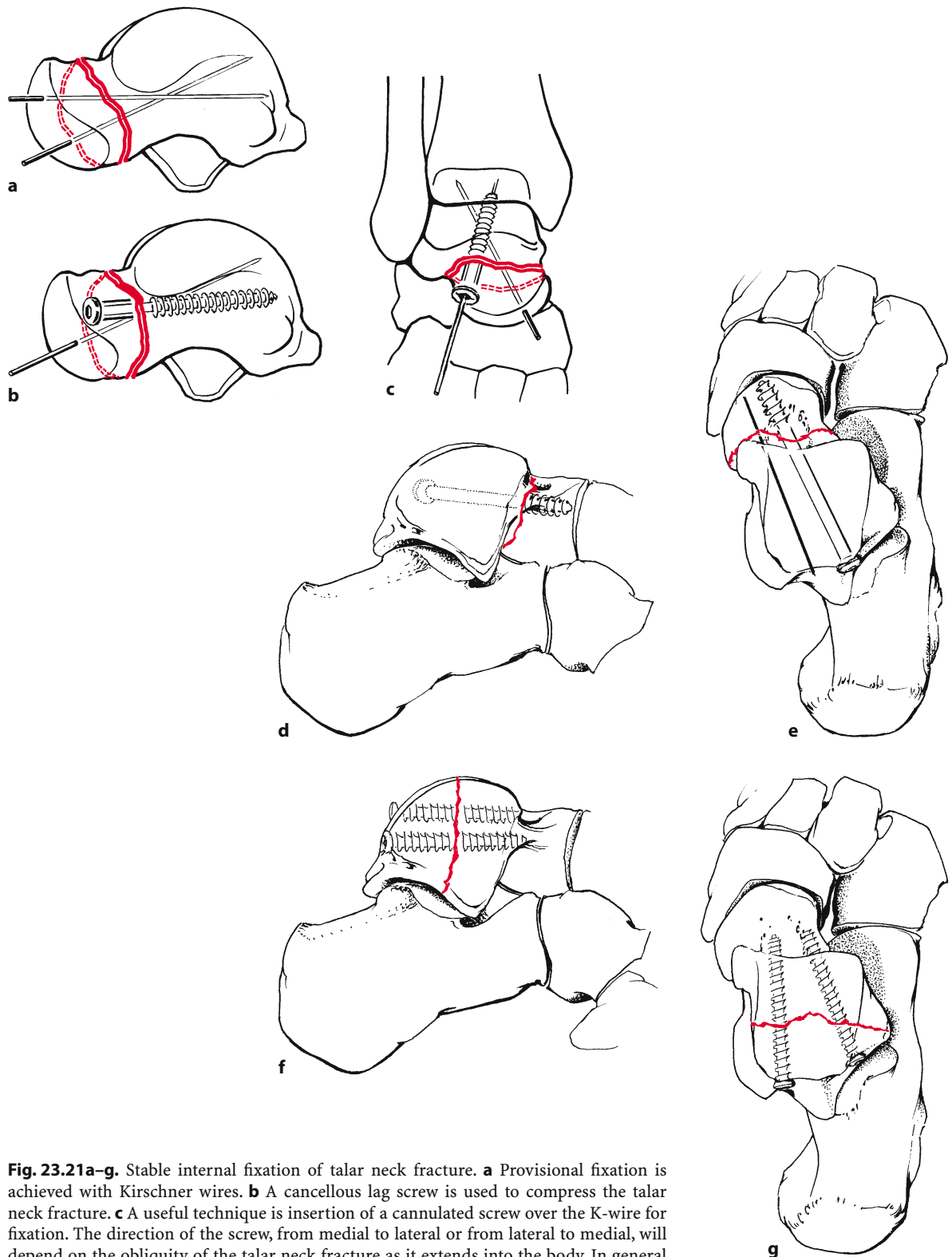
##### Follow-Up Care

##### Recognition and Management of Avascular Necrosis.

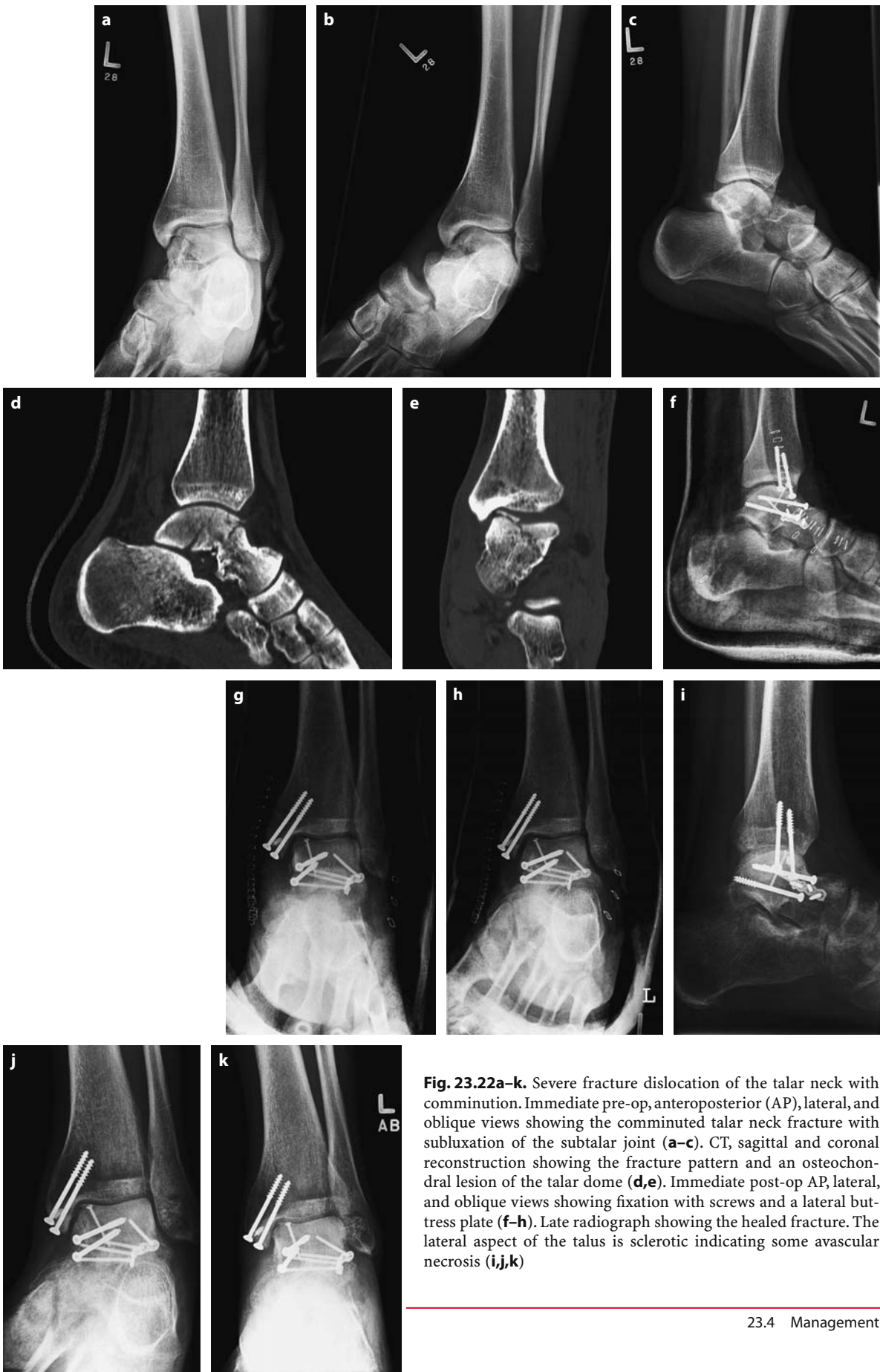The specific follow-up care of the patient will depend upon the type of injury and its management. In type A or type B talar neck fractures, the risk of avascular necrosis is minimal, whereas in type C injuries necrosis is virtually certain.

Avascular necrosis of the body of the talus may be suspected as early as 6–8 weeks following injury. Evidence of bone resorption, shown by the presence of subchondral atrophy in the dome of the talus, is de facto evidence of an intact blood supply (Fig. 23.24a,b). In cases in which the blood supply to the talar body is interrupted, bone resorption is impossible; therefore, no subchondral atrophy is seen on the early radiograph and the talar body appears relatively dense (Fig. 23.24c–e).

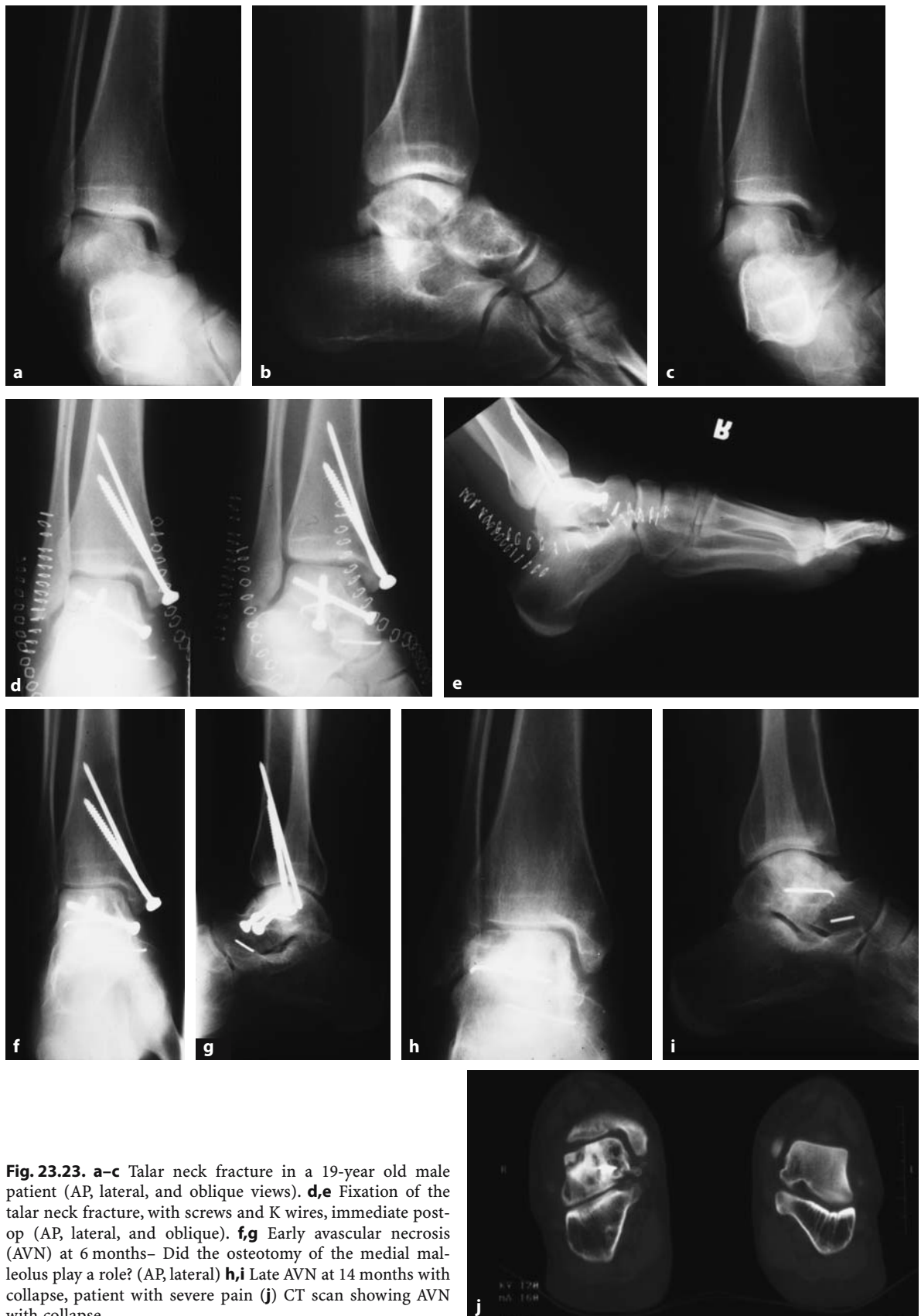Technetium polyphosphate bone scanning, if performed early, may be of some prognostic importance.



**Fig. 23.21a–g.** Stable internal fixation of talar neck fracture. **a** Provisional fixation is achieved with Kirschner wires. **b** A cancellous lag screw is used to compress the talar neck fracture. **c** A useful technique is insertion of a cannulated screw over the K-wire for fixation. The direction of the screw, from medial to lateral or from lateral to medial, will depend on the obliquity of the talar neck fracture as it extends into the body. In general the screw should cross the fracture line perpendicular to the fracture; therefore the obliquity of the fracture will guide the surgeon as to the direction of the screw. **d,e** The screw can also be inserted in a retrograde fashion as noted in the drawings. The screws may be 6.5-mm lag screws (**d,e**) or 3.5-mm cortical screws inserted as a lag screw (**f,g**)

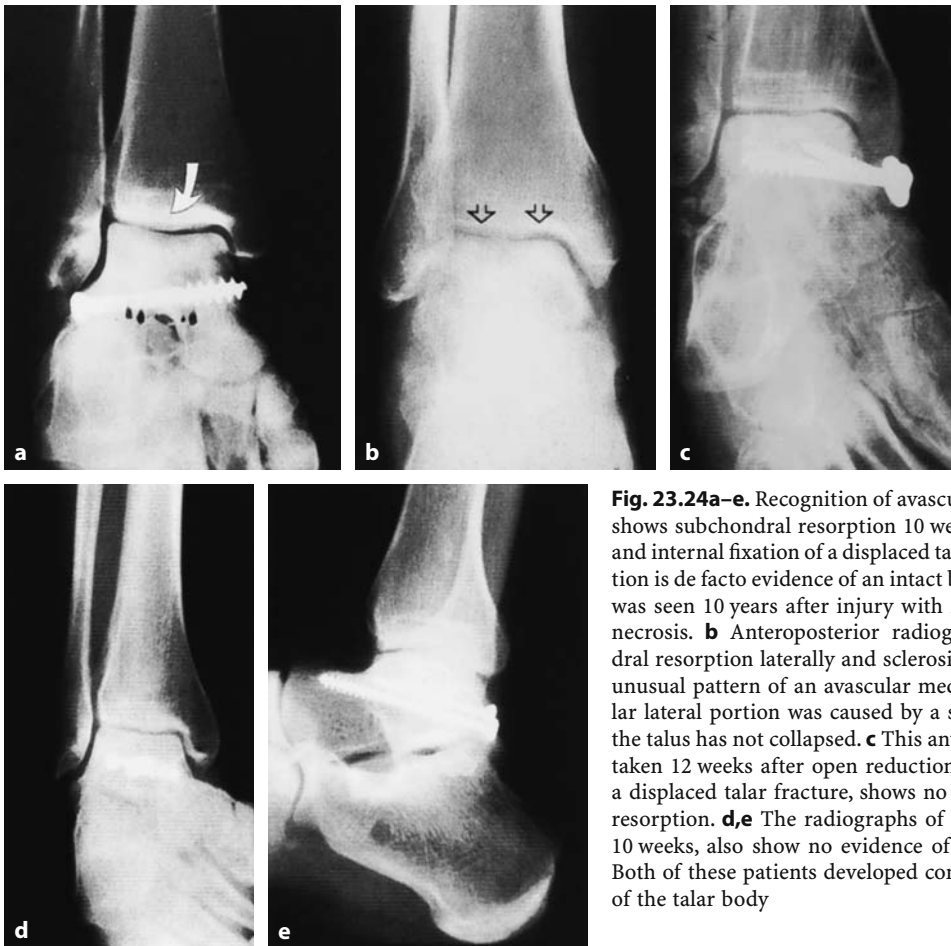

**Fig. 23.22a-k.** Severe fracture dislocation of the talar neck with comminution. Immediate pre-op, anteroposterior (AP), lateral, and oblique views showing the comminuted talar neck fracture with subluxation of the subtalar joint (**a-c**). CT, sagittal and coronal reconstruction showing the fracture pattern and an osteochondral lesion of the talar dome (**d,e**). Immediate post-op AP, lateral, and oblique views showing fixation with screws and a lateral buttress plate (**f-h**). Late radiograph showing the healed fracture. The lateral aspect of the talus is sclerotic indicating some avascular necrosis (**i,j,k**)



**Fig. 23.23.** **a–c** Talar neck fracture in a 19-year old male patient (AP, lateral, and oblique views). **d,e** Fixation of the talar neck fracture, with screws and K wires, immediate post-op (AP, lateral, and oblique). **f,g** Early avascular necrosis (AVN) at 6 months– Did the osteotomy of the medial malleolus play a role? (AP, lateral) **h,i** Late AVN at 14 months with collapse, patient with severe pain **(j)** CT scan showing AVN with collapse





**Fig. 23.24a–e.** Recognition of avascular necrosis. **a** The arrow shows subchondral resorption 10 weeks after open reduction and internal fixation of a displaced talar neck fracture. Resorption is de facto evidence of an intact blood supply. This patient was seen 10 years after injury with no evidence of avascular necrosis. **b** Anteroposterior radiograph showing subchondral resorption laterally and sclerosis medially (arrows). This unusual pattern of an avascular medial portion and a vascular lateral portion was caused by a shear injury. The body of the talus has not collapsed. **c** This anteroposterior radiograph, taken 12 weeks after open reduction and internal fixation of a displaced talar fracture, shows no evidence of subchondral resorption. **d,e** The radiographs of another patient, taken at 10 weeks, also show no evidence of subchondral resorption. Both of these patients developed complete avascular necrosis of the talar body.

Magnetic resonance imaging (MRI) is also a very sensitive indicator of avascular necrosis.

Type A talar neck fractures treated nonoperatively should remain in plaster until bony union has occurred, i.e., usually for 6–12 weeks. Weight bearing may be started early (after 2–4 weeks) if the fracture is stable.

The postoperative management of type B fractures with cancellous screw fixation will depend upon the degree of stability of the subtalar joint at the conclusion of surgery. If the joint is stable, motion may be started early, but in cases with an unstable subtalar joint, the foot must be kept in plaster for 8–12 weeks until the capsule has healed. In this group of patients, the final outcome is usually good, even if patchy avascular necrosis of the body of the talus develops. Late collapse of the body is rare, although radiographs and bone scans should nevertheless be carefully monitored. If avascular necrosis is suspected, restricted weight bearing in a patellar-bearing

caliper is advised, although these devices are not completely effective.

In type C injury, with the inevitable avascular necrosis (see Fig. 23.17), the follow-up care is controversial. At this time, there is no evidence that attempts at revascularization of the body of the talus will be successful. Bone-foreg operations and subtalar fusion have been attempted with equivocal results. In our opinion, management should be nonoperative, the patient being fitted with a weight-relieving caliper. If collapse of the body does occur, the treatment options include:

1. Excision of the body with fusion of the tibia to the head of the talus (Blair fusion; see Crenshaw 1971, p. 502)
2. Excision of the talus and tibiocalcaneal fusion
3. Tibiotalar-calcaneal fusion through a lateral approach
4. Talectomy (Gunal et al. 1993)

It is beyond the scope of this book to describe the surgical techniques of these reconstructive procedures in detail.

### 23.4.4

#### Special Problems

##### 23.4.4.1

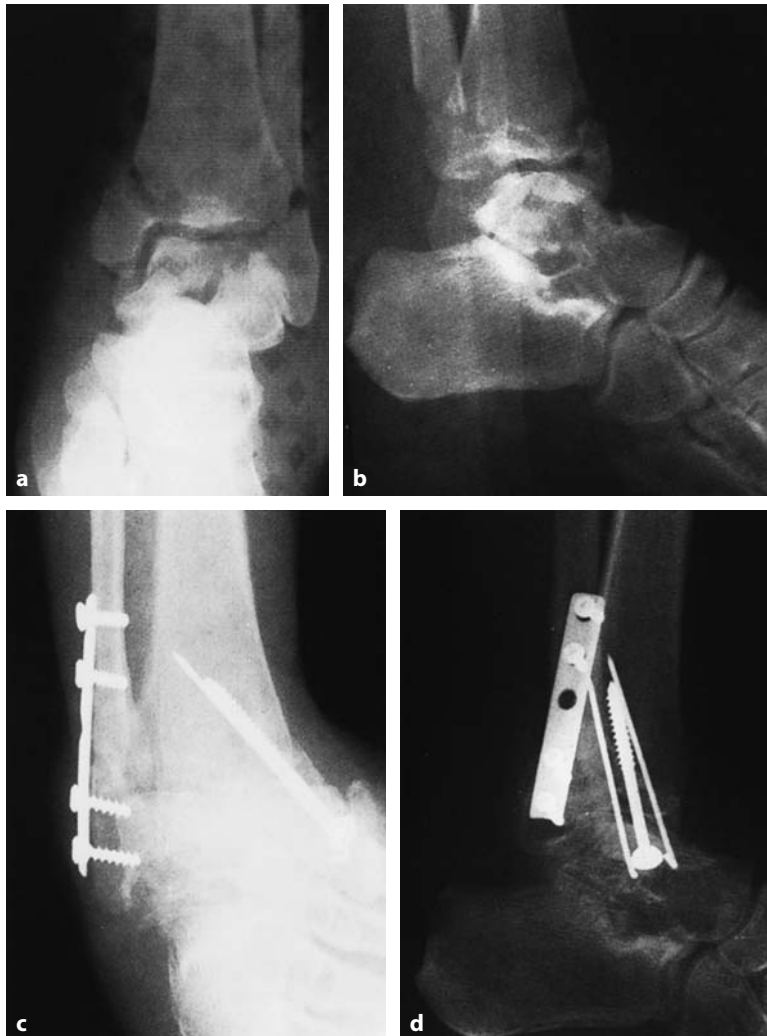#### Open Fractures and Fracture-Dislocations

Open type A and type B talar neck fractures should be managed as previously indicated. Following careful wound cleansing and débridement, the talar neck fracture should be primarily stabilized with cancellous bone screws and Kirschner wires. All soft tissue attachments to the bone must be retained. The wound should be left open and closed secondarily when possible. On occasion, it is safer to let the wound heal by

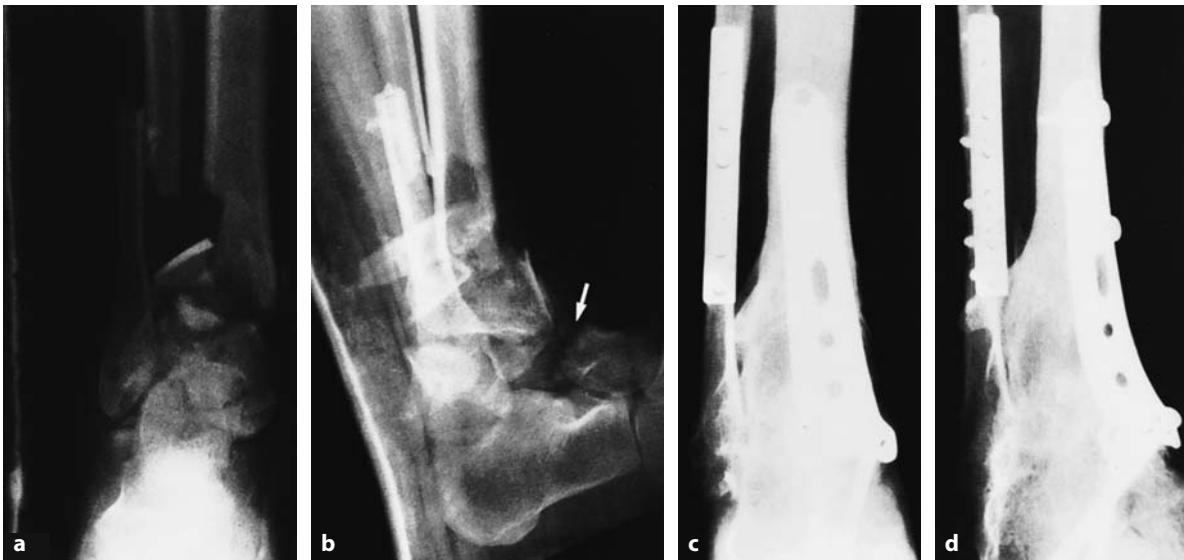secondary intent than to attempt plastic procedures or wound closure. If the fracture has been stabilized, a careful assessment should be made of the stability of the subtalar and ankle joint. If it is stable, early motion may be initiated, the fracture usually being protected with a below-the-knee splint and hinged ankle device while at rest.

In type C open fractures with total dislocation of the talus, or in open fractures with a shattered talar body, the situation changes drastically (Fig. 23.25). In these cases, with complete stripping of all soft tissues from the displaced fragments, it is safer to discard the body of the talus and proceed to a tibiocalcaneal fusion. The risk entailed by leaving a large, dead talar body in situ in a potentially contaminated wound is too great, and sepsis is a frequent outcome.

Obviously, each case is different and requires careful assessment, but, in general, the above are the principles we favor.



**Fig. 23.25a-d.** Comminuted fracture of the body of the talus. **a** Anteroposterior and **b** lateral radiographs showing severe comminution of the body of the talus as well as a fracture of the medial and lateral malleoli of the ankle. This patient also had a severe head injury. The talar fracture was open. Many small fragments of bone had to be discarded, including areas of the articular surface. **c,d** At 9 months, areas of collapse of the talus are seen on the anteroposterior and lateral radiographs. The patient's head injury precluded further reconstructive surgery



**Fig. 23.26a–d.** Tibiocalcaneal fusion. **a,b** This patient, a 40-year-old man, had a severe fracture of the distal tibia and talar neck. Note the severe displacement of the talar neck fracture (*arrow*). **c,d** He eventually developed avascular necrosis and required a tibiocalcaneal fusion

#### 23.4.4.2

#### Comminuted Fractures of the Talar Body

In closed, extremely comminuted fractures of the body of the talus, open reduction and stable internal fixation may be impossible (Fig. 23.26). The late results of this fracture are poor and in some instances, when the skin in the region allows, it is preferable to carry out a delayed primary tibiocalcaneal fusion (Fig. 23.26a,b). We favor the lateral approach, dividing the fibula 6–8 cm proximal to the ankle joint and rotating it posteriorly. This allows excellent exposure of the entire lateral aspect of the ankle and subtalar joint and the avascular, comminuted talar body can be removed. The fibula can then be used to stabilize the tibia to the os calcis. An iliac crest cancellous graft should supplement the fusion (Fig. 23.26c,d).

#### References

- Anderson HG (1919) The medical and surgical aspects of aviation. Oxford Medical, London
- Broden B (1949) Roentgen examination of the subtalar joint and fractures of the calcaneus. *Acta Radiol* 31:85–91
- Coltart WD (1952) “Aviator’s astragalus.” *J Bone Joint Surg [Br]* 34B:545–566
- Comfort TH, Behrens F, Gaither DW, Denis F, Sigmond M (1985) *Clin Orthop Res* 199
- Cooper A (1832) *Treatise on dislocations and fractures of the joints*. London, pp 341–342
- Crenshaw AG (ed) (1971) *Campbell’s operative orthopaedics*, vol 1, 5th edn. Mosby, St. Louis
- Crenshaw AG (1980) *Surgical approaches*. In: Edmunson AS (ed) *Campbell’s operative orthopaedics*, 6th edn. Mosby, St. Louis
- Detenbeck LC, Kelly PJ (1969) Total dislocation of the talus. *J Bone Joint Surg [Am]* 51A(2):283
- Grob D, Simpson LA, Weber BG, Bray T (1985) Operative treatment of displaced talus fractures. *Clin Orthop Rel Res* 199
- Gunal I, Atilla S, Arac S, Gursoy Y, Karagozlu H (1993) A new technique of talectomy for severe fracture-dislocation of the talus. *J Bone Joint Surg* 75B
- Haliburton RA, Sullivan CR, Kelly PJ, Peterson LFA (1958) The extra-osseous and intra-osseous blood supply of the talus. *J Bone Joint Surg [Am]* 40A:1115–1120
- Hawkins LG (1970) Fractures of the neck of the talus. *J Bone Joint Surg [Am]* 52A(5):991
- Kenwright J, Taylor RG (1970) Major injuries of the talus. *J Bone Joint Surg [Br]* 52B:36–48
- Kleiger B (1948) Fractures of the talus. *J Bone Joint Surg [Am]* 30A:735
- Lauro A, Purpura F (1956) La trabecolatura ossea e l’irrorazione sanguigna nell’astragalo e nel calcagno. *Minerva Chir* 11:663–667
- Lexor E, Kuliga, Turk W (1904) *Untersuchungen über Knochenarterien*. Hirschwald, Berlin
- McKeever FM (1943) Fracture of the neck of the astragalus. *Arch Surg* 46:720
- Montis S, Ridola C (1959) Vascolarizzazione dell’astragalo. *Quad Anatomia Practica* 15:574
- Mulfinger GL, Trueta J (1970) The blood supply of the talus. *J Bone Joint Surg [Br]* 52B:160–167
- Pennal GF (1963) Fractures of the talus. *Clin Orthop* 30:53–63
- Peterson L, Goldie I (1975) The arterial supply of the talus. *Acta Orthop Scand* 46:1026–1034

- Phemister DB (1940) Changes in bone and joints resulting from interruption of circulation. *Arch Surg* 41:436
- Sneed WL (1925) The astragalus: a case of dislocation excision and replacement; an attempt to demonstrate the circulation in this bone. *J Bone Joint Surg* 7:384–399
- Swanson TV, Bray TJ, Holmes GB (1992) Fractures of the talar neck. *J Bone Joint Surg* 74A
- Syme (1848) Contribution to the pathology and practice of surgery, 1st edn. Sutherland and Knox, Edinburgh, p 126
- Szyszkowitz R, Reschauer R, Seggl W (1985) Eighty-five talus fractures treated by ORIF with five to eight years of follow up study of 69 patients. *Clin Orthop Rel Res* 199
- Watson-Jones R (1946) *Fractures and joint injuries*, vol 2, 3rd edn. Livingstone, Edinburgh, pp 821–843
- Wildenauer E (1950) Die Blutversorgung des Talus. *Z Anat Entwicklungsgesch* 115:32