

# European Association of NeuroOncology Magazine

Neurology · Neurosurgery · Medical Oncology · Radiotherapy · Paediatric Neuro-oncology · Neuropathology · Neuroradiology · Neuroimaging · Nursing · Patient Issues

## Chemotherapy and Polyneuropathies

Grisold W, Oberndorfer S

Windebank AJ

*European Association of*

*NeuroOncology Magazine 2012; 2 (1)*

25-36



Homepage:

[www.kup.at/  
journals/eano/index.html](http://www.kup.at/journals/eano/index.html)

Online Database Featuring  
Author, Key Word and  
Full-Text Search



THE EUROPEAN ASSOCIATION OF  
NEUROONCOLOGY

Member of the  DOAJ

# Chemotherapy and Polyneuropathies

Wolfgang Grisold<sup>1</sup>, Stefan Oberndorfer<sup>2</sup>, Anthony J Windebank<sup>3</sup>

**Abstract:** Peripheral neuropathies induced by chemotherapy (CIPN) are an increasingly frequent problem. Contrary to haematologic side effects, which can be treated with haematopoietic growth factors, neither prophylaxis nor specific treatment is available, and only symptomatic treatment can be offered.

CIPN are predominantly sensory, duration-of-treatment-dependent neuropathies, which develop after a typical cumulative dose. Rarely motor, autonomic, or CNS involvement occurs. Typically, the appearance of CIPN is dose-dependent although in at least 2 drugs (oxaliplatin and

taxanes) immediate effects can appear, caused by different mechanisms. The substances that most frequently cause CIPN are vinca alkaloids, taxanes, platin derivatives, bortezomib, and thalidomide. Little is known about synergistic neurotoxicity caused by previously given chemotherapies, or concomitant chemotherapies. The role of pre-existent neuropathies on the development of a CIPN is generally assumed, but not clear.

Neurologists are often called in as consultants for cancer patients suffering from CIPN and have to assess whether the neuropathy is likely

to be caused by chemotherapy or other mechanisms, whether treatment needs to be modified or stopped due to CIPN, and what symptomatic treatment should be recommended.

Possible new approaches for the management of CIPN could be genetic susceptibility, as there are some promising advances with vinca alkaloids and taxanes. **Eur Assoc Neurooncol Mag 2012; 2 (1): 25–36.**

**Key words:** chemotherapy, neurotoxicity, central nervous system, prevention, therapy

## Introduction

Patients with oncological diseases need to receive the most effective anti-cancer therapy. To achieve this, usually a combination of surgery, radiotherapy (RT), and chemotherapy, also with biologicals with an increased use of targeted therapies, is applied. Like most other side effects of therapy, such as nausea, haematotoxicity can be managed but the increased use of neurotoxic drugs and the development of CIPN are becoming major dose-limiting factors.

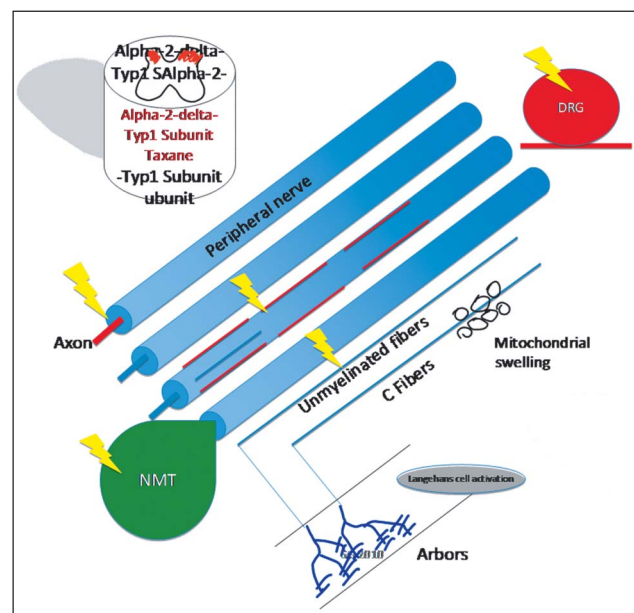
Although the biological effects of all neurotoxic substance classes are known, the precise mode of action on the peripheral nerves is not always clear, and much effort has to be made to develop strategies of prevention and treatment of CIPN. The morphologic correlates of CIPN are depicted in Figure 1. This is of particular importance as the number of long-term survivors has increased due to the success of oncologic treatments and peripheral neurotoxicity becomes a major dose-limiting factor. Patients can be exposed to dysfunctions impairing their quality of life as well as to neuropathic pain. To overcome this challenge several approaches are being made.

Several possibilities for common pathways and affected structures of sensory neurons and peripheral nerves are being discussed. The impairment of mitochondrial function (suggested by the loss of mitochondrial mobility in bortezomib, paclitaxel, and vinca alkaloid neuropathy) could be one of the key factors. Mitochondrial failure could be a mechanism causing axonal injury either by a failure to maintain ionic concentrations, or by the fact that impaired mitochondrial motility results in mitochondria being unable to move to areas of high calcium concentration in the axon, resulting in axonal dam-

age. Mitochondria in aged persons could also be a factor in distal axonal degeneration.

Sensory neurons in the dorsal root ganglia (DRG) seem to be exposed to several pathologies:

- The blood supply of the DRG by fenestrated capillaries that allow passage of drugs into the extracellular space around DRG neurons (blood-nerve-barrier less well-expressed).
- Platinum binding to nuclear DNA appears to stimulate post-mitotic neurons to enter a state resembling G1 of the cell cycle which might start processes resulting in apoptosis.
- Cutaneous sensory fibres lose their glial ensheathment as they approach the epidermis and are less protected contrary to motor fibres.



**Figure 1.** Morphologic correlates of CIPN. The DRGs can be the target of cumulative neurotoxicity as in platinum compounds. Axons, rarely the myelin, can be damaged. At the neuromuscular transmission site (NMT), the acute toxicity of oxaliplatin occurs. Unmyelinated fibers and terminal nerve arbors are the sites of acute taxane toxicity. An additional spinal mechanism at the alpha-2-delta-Typ1 subunit in neuropathic pain is assumed.

Received on September 23, 2011; accepted for publication on October 22, 2011; Pre-Publishing Online on December 15, 2011

From the <sup>1</sup>Department of Neurology, Kaiser-Franz-Josef-Spital, Vienna; the <sup>2</sup>Department of Neurology, Landeskrankenhaus St. Pölten, Austria; the <sup>3</sup>Department of Neurology, Mayo Clinic, College of Medicine, Rochester, MN, USA

**Correspondence to:** Wolfgang Grisold, MD, Department of Neurology, Kaiser-Franz-Josef-Spital, A-1110 Vienna, Kundratstraße 3; e-mail: wolfgang.grisold@wienkav.at

– Disruption of axonal transport also interferes with retrograde transport of target-derived trophic factors, recycled membrane, and other vesicular components. In the near future, based on databases containing cancer type, type, and dose of chemotherapy, phenotyping of patients with CIPN might become more easily available and provide a basis for future strategic plans and even individualized therapies.

Concerning the severity and expression of neuropathies, as well as the frequency of occurrence, there are major problems. The characterization with scales and scores is heterogeneous and is discussed by Cavaletti et al in this issue [1]. The frequency of neuropathy for each drug is even more complex, as most series rely on small studies or are the result of larger medical oncologic studies which report neuropathies only as side effects. Often, these figures provide no information on associated diseases, pre-existing neuropathies, previous drug treatments, and the combination of chemotherapies. Websites recording individually reported side effects reach large numbers, and by and large they seem to list the distribution of toxic effects, but are not sufficiently evaluated to determine neurotoxic effects. Several reviews on chemotherapy-induced neuropathies exist, which rely on the available data [2–6].

■ **Symptoms, Signs, and Investigations**

**Clinical Symptoms**

Most chemotherapy-induced neuropathies are sensory. As the CIPNs are duration-of-treatment-dependent, tingling or numbness in the feet or fingers is an early sign. Patients also report hypaesthesias, dysaesthesias or paraesthesias and neuropathic pain. Sensory symptoms such as numbness are usually irritating. But also a “plus” of symptoms, such as tingling, itching, stabbing, or pain, may occur. When symptoms progress, the sensory zone widens and progresses from the tips of the extremities to a stocking-glove-like distribution. At this stage, patients are usually already disabled: on the upper extremities by a loss of dexterity and development of clumsiness, on the lower extremities by an addition of instability, which leads to disturbed balance and falls. Neuropathic pain is an issue in some CIPNs, allodynia may develop as well. Platin compounds can induce Lhermitte’s phenomenon, which can be troublesome. Rarely, also a Tinel-like electric shock can be induced when the feet touch the ground in a “stamping” manner, resembling a Hoffmann-Tinel sign.

Rarely encountered symptoms are pruritus, Raynaud’s phenomenon, and muscle pain, which have been observed particularly in gemcitabine and taxanes. One neglected symptom is muscle cramps in small foot muscles, which are presumably a sign of distal motor involvement.

**Signs**

The signs usually consist of a loss of reflexes and disturbed sensory qualities such as touch, pinprick, and vibration (the Rydel-Seiffert tuning fork is recommended) can be noted. Two-point discrimination is rarely performed but effective. Also monitoring of the progression with Semmes-Weinstein elements is useful but may be time-consuming. Conventional tests of coordination such as finger-to-nose, knee-to-shin, and the Romberg test can become abnormal. A sensitive test is the

**Table 1.** Muscle symptoms related to chemotherapy

Rhabdomyolysis	Cytarabine
Proximal weakness	Taxanes
Radiation recall phenomenon	Gemcitabine
Necrotizing myopathy	Vincristine
Myalgia	Taxanes, gemcitabine, several others
Distal cramps	Vinca alkaloids (as neuropathy)

loss of stereotactile recognition of small figures such as coins, keys etc.

Motor function is usually not an issue in CIPN, apart from vinca alkaloids, which can induce monopareses and drop foot, and suramin which has a significant motor involvement but is infrequently used.

Autonomic signs are rare but can be seen in vinca alkaloids, resulting in intestinal symptoms, even ileus, and have also been noted in taxanes and platinum compounds.

Motor symptoms can occur as mononeuropathies or cranial nerve lesions in vinca alkaloids.

Some drugs cause muscle involvement (Table 1) with myalgia, muscle cramps, or weakness [3, 7]. This can be a proximal myopathy as seen in taxanes [8, 9] and vincristine [10]. Myalgia has been observed in a combination of taxanes and gemcitabine [11]. Cramps rarely occur, but when they do, they occur in particular in small foot and hand muscles. The radiation recall syndrome [12] has been described in gemcitabine and carboplatinum. Rhabdomyolysis has been rarely attributed to chemotherapy [13, 14]. Sarcopenia, which is a common phenomenon in advanced cancer, has also been related to drug treatment [15]. In myelomas, muscle amyloidosis occurs as well [16, 17], which is characterized by a combination of weakness and pseudohypertrophic muscles.

**Nerve Conduction Velocities (NCV)**

Nerve conduction velocity and EMG are the standard tests in clinical neurophysiology. In CIP, NCV usually shows axonal changes often focused on sensory nerves. There is a correlation in axonal neuropathies with the NCV. The clinical correlation, however, has several caveats:

- The correlation is weaker in drugs affecting the DRG, such as platinum derivatives, and also in small fibre type changes.
- The correlation is poor with regard to temporal changes within therapy.
- In the clinical situation, the classical examination with a history and findings is more significant than the NCV results. The role of imaging of peripheral nerves in CIPN, such as magnetic resonance techniques and nerve ultrasound, has not been determined.

There are some reports of mononeuropathies occurring with vinca alkaloids and CTS with aromatase inhibitors. For these lesions, it is suggested to use the common NCV criteria.

**Skin Biopsy**

The role of skin biopsy in CIPN is currently evolving [18]. There are several reports describing small-fibre changes, in

**Table 2.** Cumulative doses. The cumulative dose per square metre is known for several drugs. For many drugs, large series are available. Acute side effects occur only in 2 drugs, other particular effects are mentioned in "other effects".

Drug	Cumulative dose	Large series	Acute effects	Other effects
Cisplatin	300–400 mg/m <sup>2</sup>	+	Acute toxicity!	Coasting
Carboplatin	600 mg/m <sup>2</sup>	+		
Oxaliplatin	800 mg/m <sup>2</sup>	Acute toxicity more often described than cumulative		
Ifosfamide	?		Acute toxicity likely ?	Painful
Gemcitabine	?			Myalgia
Vincristine	5–15 mg/m <sup>2</sup>	+		Addition: cranial nerve mononeuropathies, autonomic symptoms, necrotizing myopathy
Paclitaxel	200 mg/m <sup>2</sup>	+	Acute toxicity likely ?	Myalgia, myopathy
Docetaxel	400–600 mg/m <sup>2</sup>	+		
Bortezomib	1–3 mg/m <sup>2</sup>	+		
Thalidomide	20 g (total)	+		Painful, rarely demyelinating

particular in taxane-related neuropathies. Punch skin biopsies are classified as a minimally invasive procedure. Although loss of nerve fibre density is an end-stage phenomenon in neuropathy, early changes and hopefully future markers may allow to identify prognostic factors. As yet, it can be classified as investigational in CIPN.

### Nerve Biopsy

Although most knowledge of the character of morphological changes in CIPN derives from morphological studies, whole biopsies for CIPN are not indicated unless a differential diagnosis is required to rule out inflammatory, vasculitic, neoplastic, or amyloid neuropathy. Another exception is a biopsy within a defined and approved study protocol.

## ■ Clinical Course and Development

Most CIPN are dose-dependent neuropathies, with the cumulative dose (Table 2) varying to some extent intraindividually. Usually, at the onset of chemotherapy throughout the first 1–3 cycles, CIPN symptoms appear. From cycle 3–4, usually symptoms develop. In some drugs, it has been observed that after a peak of neurotoxicity the increment of CIPN slows after the 4<sup>th</sup> or 5<sup>th</sup> cycle [19, 20]. Due to the length-dependent mechanism, the feet are usually affected first.

### General Phenomena

Two drugs can produce an immediate toxicity, even after the first dose: (1) oxaliplatin, which has been studied extensively; its CIPN is caused by channelopathy-like mechanisms. (2) Acute, painful small-fibre lesions have been described in taxanes, which are attributed to mitochondrial and small-fibre changes [21].

Once CIPN has developed and the patient suffers from symptoms, the question is usually whether cessation or replacement of the drug is compatible with the oncologic strategy. In this setting, there are 2 other important aspects:

#### Coasting

Coasting is an irritating phenomenon. It has been noted particularly with platinum compounds; even after cessation of the neuropathy symptoms can progress and there is a consid-

erable time lag until improvement. Coasting can continue for a few weeks to months. Coasting has also been observed in vinca alkaloids [22] but does not seem to be a frequent phenomenon in this drug.

#### Prognosis

The reversibility of CIPN is of increasing importance since active chemotherapies prolong survival. Although there are few long-term studies it must be assumed that CIPN is not always completely reversible. A study with taxanes has shown that even after several months to years some symptoms remain. This is important information in the consultation with patients.

### Other Influential Factors

#### Pre-existing Neuropathies

The influence of pre-existing neuropathies deriving from diabetes mellitus, alcohol abuse, or from a pre-existing hereditary neuropathy on the development of CIPN is considerable. In older patients, also a small percentage of chronic idiopathic axonal neuropathies occurs. Commonly, it is assumed that pre-existing neuropathies, and in particular hereditary neuropathies, may predict a worse course of a neuropathy. In hereditary neuropathies, even devastating effects have been observed in patients receiving chemotherapy.

Prior chemotherapy and combinations of chemotherapies are also an issue, especially since patients often receive second- or third-line therapies, also with varying drug combinations [23].

## ■ Assessment: Scales and Scores

There are several ways to classify the neurotoxic drugs causing CIPN. In clinical practice, it is equally important to note that patients receive non-neurotoxic toxic drugs as well for clinical decision-making and neurologic advice. For this review, we listed the substances according to common classifications.

For the clinical assessment, it has been agreed that the general toxicity scales used in general oncology are too imprecise for the assessment of CIPN. On the other hand, more complex neurologic scales, such as the TNS, are too complicated and

time-consuming for non-neurologists, in particular medical oncologists [6, 24–27]. In clinical practice, it would be helpful for oncologists to have a small, easily applicable scale that helps to identify patients with symptoms of neuropathy as early as possible [19, 20]. Several scores are available such as the NCI-CTC [24], ECOG [28], Ajani score, TNS [29], and the modified TNS (sTNS). Patient observations and descriptions are increasingly used and differ from the physicians' observation. The frequently used numeric rating scales are based on an ordinal setting, where differences amounting to one or two points can actually have dissimilar clinical significance. The CI-PeriNoms Study [30, 31] is an ongoing clinimetric study, which incorporates disability measures, validates quality-of-life scales, and neurophysiological testing to ascertain a better assessment of CIPN. An overview by Cavaletti and the PeriNoms study group depicting this approach can be found in this issue [1].

### ■ Substance Groups

1. Alkylators
2. Antibiotics
3. Antimetabolites
4. Mitotic spindle inhibitors
5. Topoisomerase inhibitors
6. Proteasome inhibitors
7. Others
8. Biologicals

### Alkylators

#### Platin Derivates

Three members of the drug family are currently used: cisplatin, carboplatin (mainly in lung, breast, and ovarian cancers), and oxaliplatin (in metastatic colon cancer and undergoing clinical trials for the treatment of other gastrointestinal tract malignancies).

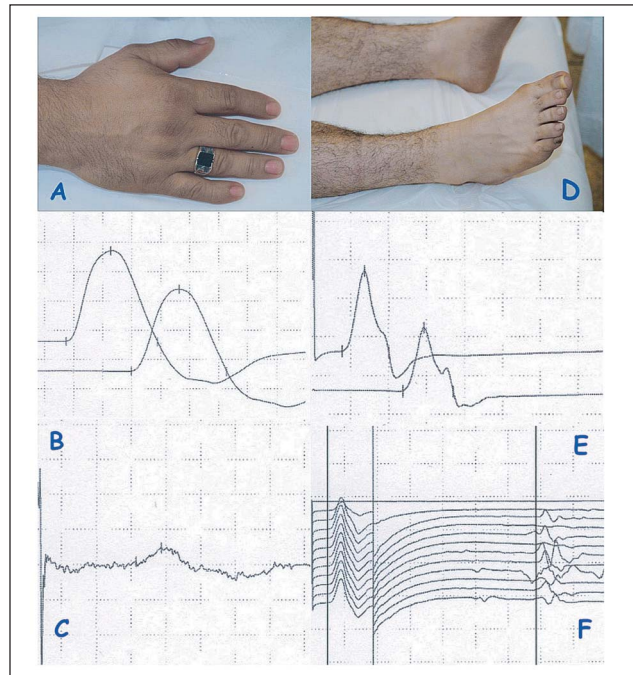
The chemotherapeutic mechanism of platinum compounds is similar to DNA-binding alkylating agents. If the DNA damage exceeds the ability to cell repair, the cell undergoes apoptotic cell death. Platinum compounds induce aberrant re-entry into the cell cycle and apoptosis [32]. Platinum compounds have a unique effect on neurons. Selective vulnerability of DRG-sensory neurons depends presumably on the structure of the blood-nerve-barrier [33, 34]. Also binding of platinum to mitochondrial DNA has been considered a potential mechanism of cell death [35]. Cell death of the sensory neuron results in permanent distal sensory loss.

#### Clinical Features

Each of the compounds produces dose-dependent sensory symptoms and a sensory neuropathy in relation to the cumulative dose.

#### Cisplatin

For cisplatin, the development of neuropathies is closely related to the total cumulative drug dose [36, 37]. In the majority of patients who receive > 400–500 mg/m<sup>2</sup> of cisplatin in typically 3–6 months [38, 39], the neuropathy is predominantly sensory with initial complaints of paraesthesias in



**Figure 2.** Cisplatin neuropathy. Clinical and electrophysiological features of a 40-year-old male with an ataxic cisplatin neuropathy. **(a)** Despite numbness and sensory ataxia no motor involvement with normal small-hand muscles. Nerve conduction velocity (NCV) measurement shows normal motor NCV, **(b)** the sensory NCV is reduced to 1 uV (pathologic). **(c)** The feet appear normal, neither atrophy nor trophic changes can be seen. **(d)** Knee-to-shin is pathologic, vibration perception is absent. **(e)** Motor NCVs of peroneal nerves are normal. The sural nerve sensory potential is absent; **(f)** the F wave is normal.

the distal parts of the extremities. Although all sensory modalities are involved, a loss of large-fibre sensory function is prominent, which often results in sensory ataxia. Lhermitte's phenomenon is common and probably an expression of spinal cord involvement. Coasting is a unique feature in cisplatin, but can also be observed after spinal radiation. Many patients experience residual pain after some improvement in their neuropathy. This may last for several years after discontinuation of the therapy and should be treated with standard approaches for the management of neuropathic pain.

Motor involvement is rare, however, autonomic neuropathy is infrequent and can cause dizziness, palpitations, or impotence [40].

Retreatment after previous cisplatin chemotherapy does not seem to be complicated by increased neurotoxicity [41].

#### Laboratory Studies

Electrophysiological features for platinum compounds are mostly axonal changes with a predominance of sensory fibres. Other laboratory studies are not informative. Nerve biopsy studies have shown a loss of large myelinated fibres [42]. A typical constellation of clinical and electrophysiological findings is presented in Figure 2.

#### Prognosis and Treatment

Neuropathic symptoms can progress up to 2 months after cessation of therapy ("coasting"). Then, gradual improvement may set in. However, because of the underlying pathology

being a ganglionopathy, recovery may be incomplete, especially in more severe cases.

#### *Carboplatin*

Carboplatin is less neurotoxic [43]. In higher cumulative doses, however, carboplatin also produces a sensory neuropathy, as does cisplatin [44]. In combination with paclitaxel, 20 % of patients develop moderate or severe sensory neuropathies [45].

#### *Oxaliplatin*

In addition to dose-dependent neuropathies, about 60–80 % of patients develop a cold-induced acute toxicity that involves paraesthesias in the throat, mouth, face, and hands occurring within 30–60 min after application and also includes muscle cramps and fasciculations.

The sensations are described as a tingling or burning induced by contact with cold surfaces or cold liquids. They appear acutely and typically remit a few days after the infusion is completed. Also, EMG-spontaneous activity has been observed during the attacks [46].

Oxaliplatin affects voltage-gated sodium channels and interferes with axonal ion conductance [47]. Oxaliplatin is transformed into oxalate, which is an intracellular calcium chelator, which produces similar effects as seen in ethylene glycol poisoning [48]. Oxalate, which is released intracellularly by oxaliplatin, chelates calcium and has an effect on inward sodium channels [49–51]. Divalent cations modify voltage-gated sodium channels [52]. Based on this mechanism, iv calcium gluconate and magnesium sulfate lower acute oxaliplatin symptoms [53].

Cumulative toxicity resembles cisplatin-induced neuropathies. Long-term use demonstrates that oxaliplatin is associated with mild, sensory, and motor axon loss [54]. Oxcarbazepine has been shown to be effective in prophylaxis [55].

#### *Platinum Hypersensitivity*

In addition to neurotoxicity, other hypersensitivity reactions such as skin rash, flush, abdominal cramps, itching in the palms, and severe cardiovascular reactions have been observed [56]. Usually, these will not be confused with neurotoxicity, except for itching and pruritus.

#### *Other Alkylating Agents*

Other alkylating agents, such as nitrosoureas, procarbazine, and thiotepa, rarely cause neuropathies, except for ifosfamide.

#### Ifosfamide

Neuropathy occurs in about 8 % of patients [57–59]. The onset is gradual, with paraesthesias and pain in the feet. The type of sensory loss is panmodal. Pre-existent neuropathies are risk factors [60]. Neuropathic pain can be an issue; tendon reflexes are reduced; weakness is rare. Recovery after termination of treatment is slow.

#### Procarbazine

Procarbazine is widely used in haematological malignancies and in the treatment of brain tumours. Mild peripheral neuro-

pathy has been described but is rarely problematic [61]. Myalgias have also been described.

#### Thiotepa

Thiotepa is an alkylating agent occasionally used to treat leptomeningeal metastases. Rarely, intrathecal thiotepa causes a myelopathy [62]. A motor neuropathy has also been described after intrathecal thiotepa chemotherapy [63]. On the whole, this is based on single observations and cannot be generalized.

### **Cytotoxic Antibiotics**

Several antibiotics have antineoplastic effects. The most prominent is doxorubicin, which is widely used in several chemotherapies. Although doxorubicin can induce DRG changes in animals, this is not an issue in clinical practice.

Other antibiotics, such as actinomycine, anthracyclines, daunorubicine, valrubicine, idarubicine, epirubicine, bleomycine, plicamycine, and mitamycine, rarely cause peripheral neurologic complications.

### **Antimetabolites**

Antimetabolites are compounds which inhibit the synthesis of key intermediary metabolites. Often, they are enzyme inhibitors and may block RNA or DNA synthesis. Most of the antimetabolites are either analogues of nucleotide bases or interfere with folic acid metabolism. They are more commonly associated with central rather than peripheral neurotoxicity. CIPN is generally not a major side effect.

#### Methotrexate

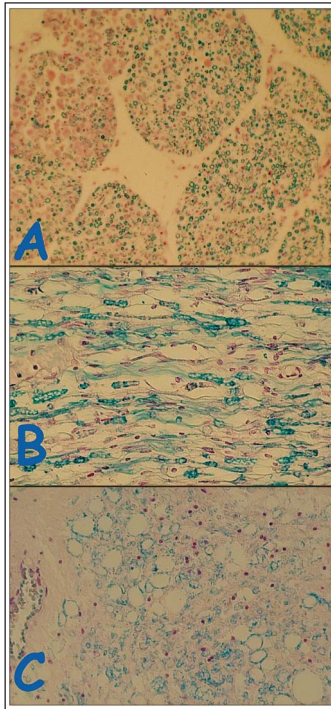
Methotrexate (MTX) is a folate antagonist that inhibits dihydrofolate reductase, a key enzyme in the synthesis of nucleotides. It is used alone or in combination chemotherapy for solid tumours and haematological malignancies in a broad spectrum of dosages (low-to-high dose) and also timings (acute as well as permanent therapies). Peripheral neurotoxicity is rare. Although IT treatment is a routine procedure it can be associated with complications, spinal arachnitis, and myelopathy.

Nelarabine is an analogue [64, 65] which does not seem to be involved in the development of CIPN.

#### Cytosine Arabinoside

Cytosine arabinoside (Ara-C) is a pyrimidine antagonist that blocks synthesis of cytosine, thymidine, and uridine. Peripheral neurotoxicity is rare. There are several case reports of various neuropathies associated with the use of high-dose Ara-C [66] and fludarabine combined with Ara-C [67]. These are only observational reports and the clinical relevance is not clear.

Depot Ara-C preparations (depocyt) are increasingly advocated for patients with meningeal carcinomatosis. Recent reports suggest that the drug may cause a cauda equina syndrome [68, 69] in some patients. Repetitive IT drug application with cytarabine treatment caused demyelination in the thoracic roots, the cauda equina, and damage to the posterior columns in a patient treated by the author (Figure 3).



**Figure 3.** Autopsy of the nerve roots, cauda equina and posterior columns of a 74-year-old woman with breast cancer and suspected meningeal carcinomatosis. She received several cycles of intrathecal cytosine arabinoside (Depo-Cyt®). The myelin appears blue with a Klüver staining. **(a)** Cauda equina. The nerve roots show loss of myelin with a patchy damage to nerve fascicles. **(b)** Spinal thoracic nerve. Diffuse demyelination. **(c)** Spinal cord and posterior column: Diffuse loss of myelinated fibres, ballooned degeneration of myelinated fibres.

### Gemcitabine

Gemcitabine is a deoxycytidine analogue structurally related to Ara-C. In many patients, it causes systemic symptoms of low-grade fever, fatigue malaise, myalgia, and arthralgia with paraesthesia. In about 10 %, sensory neuropathy with paraesthesias can develop. Autonomic involvement has also been observed.

Muscle symptoms can appear as myalgias or as “radiation recall syndrome” in pre-irradiated muscle. MRT can show oedema of the affected muscle and CK can be elevated.

Gemcitabine is often used in combination with taxanes, platinum compounds, or vinca alkaloids, all of which cause CIPN, but does not seem to increase the risk of CIPN [70].

### 5-Fluorouracil

5-Fluorouracil (5-FU) is a pyrimidine antagonist. It is used as a single agent or in combination regimens for the treatment of many tumours, especially in the gastrointestinal system. A small number of cases of CIPN have been reported after treatment with 5-FU (accompanied by radiation and levamisole) [71] and after 5-FU chemotherapy in combination with folinic acid and eniluracil [72].

The hand-foot syndrome appears in particular when treatment consisting of 5-FU and capecitabine is applied.

### Capecitabine

Capecitabine is metabolized to 5-FU. Except for observations from single cases [72], CIPN are unlikely. Cranial nerve lesions seem to appear rarely [73, 74].

The “hand-foot syndrome”, or “palmar plantar erythrodysesthesia” (PPE), has been observed in up to 10 % of patients

treated with capecitabine, but is not specific and also appears in other drugs. Administration of the drug is followed within days by palmar and plantar paraesthesias and itching followed by the development of an erythematous and occasionally bullous palmar and plantar rash. It is thought to be due to a local skin reaction, but a relationship to neuropathy or damaged small skin nerves is postulated [75].

## Mitotic Spindle Inhibitors

### Vinca Alkaloids

Vinca alkaloids are mitotic spindle inhibitors, such as taxanes and podophyllin analogues (etoposide and teniposide). The drugs interfere with microtubule assembly and mitotic spindle formation. They also influence axonal transport [76], structure, and function at many points. As with most toxic neuropathies, longer axons are more susceptible. Vinca alkaloids do not enter the blood-brain-barrier [77], which limits their use in neurological CNS disease.

Vinblastine, vincristine, and their semi-synthetic derivatives, vindesine and vinorelbine, are predominantly used for the treatment of haematologic and lymphatic malignancies and several other conditions. All are given by intravenous infusion. Vinca alkaloids produce a dose-related sensorimotor neuropathy. Vincristine and vindesine cause the most severe neurotoxicity, while vinblastine and vinorelbine are less toxic. A combination of vinorelbine with taxanes can be severe in patients previously treated with paclitaxel and has been observed in the course of a study monitoring [78].

### Clinical Features

CIPN present usually within the first 3 months of treatment. Early symptoms are paraesthesias and pain in the hands and feet as well as distally accentuated hyperaesthesia. Weakness may also occur, in particular in wrist extensors and dorsiflexors of the toes [79]. Tendon reflexes are lost early on. Muscle cramps in distal muscles (eg, feet) are frequent, often persisting long after treatment cessation. Contrary to most other CIPN, mononeuropathies (femoral, peritoneal nerves), cranial nerve lesions (with diplopia, vocal cord paralysis [80], facial nerve palsy, and sensorineural hearing loss) have been described [81, 82]. Autonomic changes can result in gastrointestinal symptoms, such as paralytic ileus or megacolon [83]. Also bladder atony, impotence, orthostatic hypotension, and cardiac problems have been reported.

Rarely, severe neuropathy with quadriparesis occurs [84]. Inherited neuropathies [85, 86] may aggravate the expression of neuropathies and need to be considered before starting chemotherapy.

### Laboratory Studies

Nerve conduction studies show axonal neuropathies with a reduced amplitude of motor and sensory action potentials with mildly reduced conduction velocities.

### Prognosis and Treatment

There are no pharmacologic treatments to reduce or prevent CIPN induced by vinca alkaloids. A pharmacological approach with lacosamide has been proposed to reduce pain and allo-

dynia in animal models [87]. Reducing dose levels and frequency of application may ameliorate the development of neuropathies. After cessation of therapy, coasting has also been described [22]. In severe cases, improvement occurs over months to several years and may be incomplete. A decreased risk of neuropathy and a more rapid recovery may exist in African Americans with at least one CYP3A5\*1 allele [88].

Physical therapy and orthoses minimize the effects of motor deficits. Skin protection and management of neuropathic pain help patients with sensory deficits.

Inadvertent intrathecal injection of any of the vinca alkaloids results in severe ascending myeloencephalopathy that is usually fatal [89, 90].

### Taxanes

Both drugs, paclitaxel and docetaxel, are widely used alone or in combination for the treatment of breast, ovarian, lung, and many other forms of cancer. Paclitaxel may produce more neuropathies than docetaxel [91]. Taxanes are frequently used in combination with other agents that cause CIPN. It is unclear whether additive or synergistic neuropathy results from this combination. There are 2 important issues concerning the transport vehicle of the drug: the transport mechanism is cremaphor [92], a non-ionic surfactant and a polysaturated castor oil which has side effects of its own, in particular allergic reactions; the other transport vehicle is abraxane, a protein-bound paclitaxel, which avoids the side effects of cremaphor but unfortunately causes CIPN in this preparation. Other preparations of paclitaxel are taxoprexin, a DHA paclitaxel (omega-3 fatty acid), and xyotax, a PG paclitaxel (poly-L- glutamic acid).

Taxanes hyperstabilize microtubule subunit cross-linking. This has the effect of increased stability of microtubules and decreased ability of the cell to dynamically reorganize the cytoskeleton. Also the formation of crystalline arrays of microtubule subunits in the cell or axon [93] occurs, which disrupts the axonal transport, the retrograde transport of target-derived trophic factors, and other vesicular components. Both processes interfere with axonal transport and result in neuropathy. In addition to microtubule changes, the ubiquitin-proteasome system (UPS) in axons with local activation of calpain/caspase cells and apoptosis may also be activated. Their mode of action is similar to epothilones.

### *Clinical Features*

Sensory symptoms are common and dose-related [94]. Both drugs induce paraesthesias, loss of sensation, and dysaesthetic pain in the feet and hands. Activities of daily life, fine motor tasks, such as buttoning and writing, can be impaired. Gait unsteadiness can be a result of sensory ataxia.

At examination, the vibratory threshold increases and perceptions of light, touch, and pin decrease in the feet more than in the hands. Deep tendon reflexes at the ankle may be lost but more proximal reflexes may be preserved.

Weakness is absent or mild, although motor neuropathies have been observed [95]. Lhermitte's phenomenon may ap-

pear. Autonomic symptoms have been described, gastrointestinal symptoms and cardiac arrhythmia may occur.

An acute toxicity, caused by mitochondrial damage and small-fibre type lesions with up-regulation of PGP9.5 in the Langerhans cells, has been described and can be attributed to acute CIPN toxicity [96]. As the lesions are restricted to the afferent axon's terminal arbour, it was suggested to name them "terminal arbour degeneration" [97].

Treatment with taxanes can also cause a proximal weakness syndrome independently of sensory symptoms. CK is normal and weakness improves after cessation of therapy. Myalgia/arthralgia syndromes are more frequent in paclitaxel and related to drug treatment, beginning 2–3 days after administration and lasting several days.

### *Laboratory Studies*

Electrophysiological testing typically demonstrates that sural nerve potentials are reduced or absent in symptomatic patients with signs of axonal neuropathy.

Concurrent cis-platinum or alcohol abuse increases the risk of CIPN. ABCB1-allelic variation negatively influences the effect of docetaxel treatment [98] and the onset of neuropathy can be delayed which will be possibly a predictive factor for the development of CIPN.

### *Prognosis and Treatment*

The sensory symptoms can be troublesome and typically remit within several weeks after treatment has been completed. Lowering the dose and lengthening the treatment may reduce difficulties in more symptomatic patients. However, long-term follow-up examinations describe a prolonged effect of CIPN in individuals with a negative effect on the quality of life [99, 100].

### Other Microtubule-Stabilizing Agents

#### *Epothilones*

Epothilones are a group of microtubule-stabilizing agents, including epothilone A, epothilone B [101], and epothilone D. Distal sensory and motor neuropathy, similar to taxanes, have been reported from phase-III clinical trials [102, 103]. Also a specific effect on vibration perception has been described.

#### *Eribulin*

Eribulin (eribulin mesylate) is a non-taxane microtubule dynamics inhibitor with tubulin-based antimetabolic activity. It is used in the treatment of patients with locally advanced or metastatic breast cancer who have previously been treated with other chemotherapies. Peripheral neuropathy (incidence 5 %) was the most common adverse event resulting in the discontinuation of eribulin treatment. In animal experiments, eribulin seems less toxic compared to other drugs [104].

#### *Podophyllin*

Podophyllin is an alkaloid extracted from the May Apple or American Mandrake and is considered both a spindle inhibitor as well as a topoisomerase inhibitor.

Etoposide (VP 16) and teniposide (VM 26) are chemotherapeutic agents derived from podophyllin. They disrupt mitotic



spindle formation and inhibit topoisomerase II as well. The drugs are extensively used in many different forms of cancer, often in combination with drugs that cause CIPN. Although peripheral toxicity is generally accepted, usually by observations and case descriptions [105], data from large studies are missing.

### Topoisomerase Inhibitors

Topoisomerase is an enzyme which interferes with repair of DNA damage and facilitates apoptosis. Topoisomerase II cuts and unwinds DNA. Type-I topoisomerase inhibitors are camptothecins (irinotecan and topotecan), and type-II inhibitors are amsacrine, etoposide, etoposide phosphate, and teniposide; they are used in several chemotherapies. For topotecan and teniposide, neuropathies of minor extent have been reported [106, 107].

### Proteasome Inhibitors

Bortezomib is a polycyclic derivative of boronic acid that inhibits the mammalian 26S proteasome. The 26S proteasome is a large complex that is part of the ubiquitin degradation pathway. It regulates the homeostatic level of many intracellular proteins including those involved in cell-cycle regulation and apoptosis. The proteasome degrades the intracellular inhibitor of NFκB (IκB). Bortezomib increases the level of the inhibitor and decreases the activity of NFκB. This down-regulates the expression of proteins that promote cell division and proliferation and enhances apoptosis. Also, secretion of cytokines in the bone marrow is suppressed. It also enhances oxidative stress by up-regulation of p53, p21, p27, p38, MAPK, and JNK. Genetic factors may be implicated in the susceptibility [108].

Carfilzomib is an irreversible proteasome inhibitor with less neurotoxic side effects [109, 110].

### Clinical Features

The neuropathy is dose-related and cumulative. It is predominantly sensory, distally accentuated, and depends on the duration of treatment. It often causes neuropathic pain probably due to small-fibre involvement. Patients experience sensory loss (numbness) and, due to small-fibre loss, pain which is perceived as burning, sharp, cold, or electric. This painful association is particularly worrying [111, 112].

Also autonomic changes with postural hypotension have been reported. Increased age is an additional risk factor. In trials, CIPN occurred in 37–44 % of patients with multiple myeloma [113]. Usually, it is a reversible duration-of-treatment-dependent neuropathy [114–116].

In a few cases, demyelinating neuropathies [117], which are probably dysimmune [118], have been observed as well.

### Laboratory

Electrophysiological changes demonstrate axonal loss as the drug has become more widely used, more prevalent, and more severe cases of neuropathy have been reported [119]. Pre-treatment with thalidomide is a serious risk factor for the development of CIPN.

A demyelinating neuropathy has also been observed [118], even in combination with thalidomide [119].

## Others

### Arsenic Trioxide

Arsenic trioxide has recently been introduced for the treatment of refractory forms of cancer [120]. It is an inorganic arsenic compound that has been known for many years to cause severe and sometimes fatal peripheral neuropathy. A recent single-agent trial, however, described few neurotoxic effects [121].

### Thalidomide and Lenalodimide

Thalidomide has a sad record of teratogenic effects due to its use in pregnant patients in the 1950s and 1960s. Since then it has been used in erythema nodosum leprosum, and as a potent VEGF inhibitor in multiple myeloma, Waldenström's macroglobulinaemia, myelodysplastic syndromes, acute myeloid leukaemia, myelofibrosis, graft versus host disease, prostate cancer, renal cell cancer, malignant brain tumours, Kaposi sarcoma, and cancer.

The type of neuropathy is predominantly sensory, with numbness and pain in hands and feet. All sensory qualities are affected, reflexes may be preserved. Cramps of small foot muscles occur. Neuropathies develop in 20–40 % of patients [122, 123]. Frequency of neuropathy increases with age and cumulative doses or duration of treatment; vulnerability in aged persons is also a major concern [124].

Lenalidomide is an analogue (alpha-3-aminophthalimidoglutaramide) and less neurotoxic in the PNS [125–127].

### Suramin

Suramin (polysulfonated naphthylurea) has been used for the treatment of tropical parasitic diseases. It can cause nephropathy and, when used in cancer patients, 2 types of CIPN: a mild distal axonal neuropathy and an acute form resembling acute polyradiculitis [128].

## Biologicals

In addition to the "classical drugs" causing CIPN, some biologicals are also mentioned, usually when administered in combination with neurotoxic drugs, which makes it difficult to assess the true effect and incidence. Three antibodies have been mentioned to cause CIPN, and except for brentuximab, where sensory neuropathies have been described, bevacizumab and trastuzumab have been considered as well. An interesting approach to this question is made by <http://www.ehealthme.com> [129], where a total of side effects is listed for a defined period of time.

### Antibodies

#### Bevacizumab

Neuropathy as a side effect of bevacizumab has not made it to the "top ten" of its most frequent side effects [129]. As of August 2011, 13,485 persons reported side effects; 16 individuals (0.12 %) had a sensory neuropathy, which occurred in the first month, which makes a cumulative effect unlikely. Other concomitant drugs were also used, which makes it difficult to evaluate. A possible association with paclitaxel has been observed. Presently, no clear evidence exists.

### *Brentuximab Vedotin (SGN-35)*

Brentuximab vedotin is an anti-CD30 monoclonal antibody in combination with monomethyl auristatin E (an antitubulin agent). It is used in the treatment of Hodgkin's lymphoma. Sensory neuropathies have been described [130]. A general opinion can not be expressed presently.

### *Trastuzumab*

Trastuzumab was analyzed on <http://www.ehealthme.com> [129] with regard to reported side effects. As of August 2011, 64,443 persons reported side effects, among them 8 individuals (0.012 %) reported a sensory neuropathy. Contrary to bevacizumab, the neuropathy was most often observed after one year (50 %) and 2 years (25 %), which makes a cumulative effect likely. Associated drugs were cyclophosphamide, gabapentine, and femara, but also other drugs, which makes the interpretation difficult. In combination with conventional chemotherapies, neuropathies have been described [131].

### Interferons

#### *Interferon- $\alpha$*

Interferon- $\alpha$  is used in the treatment of leukaemia and lymphoma as well as of hepatitis C. It can cause a distal symmetric sensory neuropathy, which can also cause pain and paraesthesia, mild loss of pain and temperature perception [132]. The NCV shows axonal loss.

### Hormones

Hormonal treatment has been assessed in comparison with chemotherapy in breast cancer. A trial of primary endocrine therapy using aromatase inhibitors (anastrozole and exemestane) in patients with ER-positive and/or PgR-positive breast cancer showed grade-2 neuropathies occurring in 30 % of patients receiving chemotherapy, while hormonal treatment was well-tolerated [133]. Focal neuropathies, such as the carpal tunnel syndrome, may increasingly occur during aromatase therapy [134].

### Radiosensitizers

#### *Misonidazole*

Misonidazole has been used as an adjunct to radiation therapy as a radiosensitizer. It causes a sensory, often painful neuropathy and is dose-related (cumulative dose > 16–18 g) [135]. The incidence can be up to 30 % if the cumulative dose has been reached [135]. The newly used radiosensitizer motexafin gadolinium has not yet been reported to cause neuropathies.

### Vitamins

Vitamin A and retinoid treatment are used in haematological diseases. Not only muscle cramps and myalgia but also sensory symptoms have been reported. The mechanisms are not fully understood.

Conversely, in animal experiments, a protective effect of retinoids in CIPN has been proposed [136].

### Tipifarnib

Tipifarnib is an oral non-peptidomimetic farnesyl transferase inhibitor used in both solid tumours and haematological malignancies such as acute myeloid leukaemia [137]. Toxicity is

predominantly haematological, mild neuropathies have been reported [138].

## ■ Cancer Type and Neuropathy: Myeloma

Two types of malignancy – lung cancer (SCLC) and myeloma – have several types of disease-associated neuropathies. In lung cancer, it is a paraneoplastic, subacute sensory neuronopathy (SSN), which usually appears at the onset of malignancy prior to chemotherapy. Neuropathies in multiple myeloma can appear at any time, due to several aetiologies, and have been subject to reviews [139]. This is of importance as the current drug treatment has a high potential for the development of neuropathies, and also because it is generally assumed that a pre-existing neuropathy may increase the risk for a CIPN. Possible factors from myeloma and also genetic factors may be responsible for the expression of a neuropathy [140, 141].

A neuropathy caused by therapy can be dose-limiting in up to 10 % [142]. Although no specific treatment is available, dose modification needs to be considered in case of paraesthesias and pain. Treatment should be modified or reduced until toxicity resolves. Treatment also consists of symptomatic management of neuropathic pain, protection against sensory loss, and physical therapy. Elderly patients may be less able to withstand the side effects associated with newer treatment regimens [143].

The rarely observed POEMS syndrome is associated with several types of neuropathies. Treatment results have been summarized in a Cochrane review [144].

## ■ Differential Diagnosis

The differential diagnosis of CIPN is mainly based on the vital question of what chemotherapy the patient has received so far and if neurotoxicity can be expected from the substance and its dose. Several drugs applied for chemotherapy do not cause CIPN, which can be an important factor in discussing a patient's symptoms and signs at evaluation.

Differential diagnosis often considers paraneoplastic neuropathies, which tend to appear early in the course of the disease and often contribute to the detection of cancer.

Acute types of neuropathies, such as the Guillain-Barré syndrome and CIDP, have been observed to appear in lymphoma and Hodgkin's disease patients [145] and are related to the tumour type. Demyelinating neuropathies have been described in suramin treatment, and also in rare cases of bortezomib administration [117].

Meningeal carcinomatosis rarely presents as a neuropathy mimic, either as cauda equina presentation or rarely as an ascending polyradicular form. Clinically, often the association with CNS symptoms is helpful. Cauda equina lesions involve the sphincteric function as well, which is not the case in CIPN. As a rule, early pain appears.

Neurolymphomatosis [146] is a rare type of lymphomatous spread in lymphoma. It can occur either isolated in the periph-

eral nerves or in a combination of peripheral nerves and CSF, which is a matter of definition. The presenting signs can vary from a symmetric CIDP type to a multiplex type and solitary peripheral nerve involvement. The diagnosis is difficult but imaging may help; finally, a biopsy is necessary. Also intravascular lymphoma can affect peripheral nerves [147].

### Neuroleukaemiosis

This is a recently coined term [148] describing often symmetric and diffuse involvement of peripheral nerves. It has also been noted to appear as a multifocal neuropathy in M4/M5 leukaemia.

Historically, it appears that autopsy series in the pre-chemotherapy era, were well aware of this phenomenon.

### Cauda Equina Syndrome

Malignant compression of the cauda equina may be caused by a tumour, vertebral collapse, lipomatosis following steroid treatment, or chemical injury by intrathecal therapy and has been reported as a side effect of cytosine arabinoside long-term application [68]. Usually, additional signs such as a sphincter's involvement or back pain make the diagnosis likely. Intramedullary metastases are extremely rare but they can also mimic a sensorimotor neuropathy.

### ■ Prevention

Preventive drugs can potentially counteract cancer therapy. This has been the problem with several previously used preventive therapies. Several drugs have been used, such as vitamins (B and E) [149], glutathione, alpha lipoic acid, acetylcysteine [150, 151], amifostine, calcium, magnesium, diethyldithiocarbamate [152], dithiocarbamate, Org 2766, oxcarbazepine [153], or erythropoietin [154–157]. For platinum drugs, a Cochrane review states that chemoprotective agents do not seem to prevent CIPN [158].

### ■ Symptomatic Treatment

Despite the failure of drugs to prevent CIPN, several symptomatic treatments are available and should be considered in each individual case.

### Oxaliplatin's Acute Toxicity

The treatment and prevention of acute oxaliplatin toxicity have been an issue. Two basic avenues exist: (1) Ca and Mg administration or (2) carbamazepine or oxcarbazepine, which impacts on the affected channels.

### Neuropathic Pain and Dysaesthesia

Pain and paraesthesia can be a severe effect of some chemotherapy regimens, in particular taxanes and bortezomib. The use of drugs directed against neuropathic pain with anticonvulsants, antidepressants, in severe cases opioids, and, recently, also topical local anaesthetics has to be decided according to the symptoms of each patient.

### Prevention

The question of whether the administration of anticonvulsants can prevent neuropathies is increasingly discussed. Consider-

ing the concept of action of anticonvulsants this may not be likely; considering the effect that less grade-3 toxicities appear during treatment, this effect of subjective improvement can in a way be regarded as prevention of higher toxicity.

### Physical and Occupational Therapies

CIPN, apart from sensory symptoms and pain, often have a loss of proprioception, which is a highly incommensurate effect in ADLs and gait. These effects are often underestimated. It is likely that the amplified application of physical and occupational therapies, which activate other senses (vision, hearing) as well, can compensate sensory deficits and might improve them through systematic training [159].

### ■ Rehabilitation and Cancer Rehabilitation

Rehabilitation for cancer patients is increasingly offered [160]. This is a tremendous success since, in the past, cancer in a patient often banned further rehabilitation. Without dwelling on the different types of cancer rehabilitation, neuropathies and sequelae of CIPN deserve particular attention [159]. Further, it is obvious from several studies (on taxanes) that often CIPN are not completely reversible and leave the patient distinctly disabled [161].

### ■ Summary

CIPN caused by cancer treatment is gaining importance, as several effective therapies damage the peripheral nerves by various mechanisms. Despite different mechanisms of drugs, it is hoped that common mechanisms in the structure or function of peripheral nerves may help to develop preventive strategies.

For the clinician, the knowledge of drugs given to the individual patient and the cumulative doses are important. Increasingly, also other substances, in particular biological substances, may play a role by influencing the metabolism.

Symptomatic treatment with regard to sensory and/or motor symptoms and pain needs to be considered as well as concepts of rehabilitation to improve a patient's functions and quality of life.

### References:

1. Cavalletti G, on behalf of the CI-PERINOMS Study Group. The Chemotherapy-Induced Peripheral Neuropathy Outcome Measures Standardization (CI-Perinoms) Study: An Answer to the Unsettled Question of Drug-Related Neuropathy Assessment in Cancer Patients. *Eur Assoc NeuroOncol Mag* 2012; 2: 37–40.
2. Bhagra A, Rao RD. Chemotherapy-induced neuropathy. *Curr Oncol Rep* 2007; 9: 290–9.
3. Giglio P, Gilbert MR. Neurologic complications of cancer and its treatment. *Curr Oncol Rep* 2010; 12: 50–9.
4. Ocean AJ, Vahdat LT. Chemotherapy-induced peripheral neuropathy: pathogenesis and emerging therapies. *Support Care Cancer* 2004; 12: 619–25.
5. Quasthoff S, Hartung HP. Chemotherapy-induced peripheral neuropathy. *J Neurol* 2002; 249: 9–17.
6. Windebank AJ, Grisold W. Chemotherapy-induced neuropathy. *J Peripher Nerv Syst* 2008; 13: 27–46.
7. Valiyil R. Drug-related myopathies of which the clinician should be aware. *Curr Rheumatol Rep* 2010; 12: 213–20.
8. Rowinsky EK, Donehower RC. Paclitaxel (Taxol). *N Engl J Med* 1995; 332: 1004–14.
9. Markman M, Kennedy A, Webster K, et al. Use of low-dose oral prednisone to prevent paclitaxel-induced arthralgias and myalgias. *Gynecol Oncol* 1999; 72: 100–1.
10. DeAngelis LM, Gnecco C, Taylor L, et al. Evolution of neuropathy and myopathy during intensive vincristine/corticosteroid chemotherapy for non-Hodgkin's lymphoma. *Cancer* 1991; 67: 2241–6.
11. Ardavanis AS, Ioannidis GN, Rigatos GA, et al. Acute myopathy in a patient with lung

- adenocarcinoma treated with gemcitabine and docetaxel. *Anticancer Res* 2005; 25: 523–5.
12. Caloglu M, Yurut-Caloglu V, Cosar-Alas R, et al. An ambiguous phenomenon of radiation and drugs: recall reactions. *Onkologie* 2007; 30: 209–14.
13. Levy RL, Sparano JA, Khan G. Rhabdomyolysis: an unusual complication of cytotoxic chemotherapy. *Med Oncol* 2003; 12: 219–22.
14. Truica CL, Frankel SR. Acute rhabdomyolysis as a complication of cytarabine chemotherapy for acute myeloid leukemia: case report and review of literature. *Am J Hematol* 2002; 70: 320–3.
15. Prado CM, Baracos VE, McCargar LJ, et al. Sarcopenia as a determinant of chemotherapy toxicity and time to tumor progression in metastatic breast cancer patients receiving capecitabine treatment. *Clin Cancer Res* 2009; 15: 2920–6.
16. Windhagen A, Buffer J, Neudecker S. Gross muscle pseudohypertrophy in myeloma associated light chain amyloidosis. *Neurology* 2005; 65: 1670.
17. Finsterer J, Wogritsch C, Pokieser P, et al. Light chain myeloma with oro-pharyngeal amyloidosis presenting as bulbar paralysis. *J Neurol Sci* 1997; 147: 205–8.
18. Lauria G, Hsieh ST, Johansson O, et al. European Federation of Neurological Societies/Peripheral Nerve Society Guideline on the use of skin biopsy in the diagnosis of small fiber neuropathy. Report of a joint task force of the European Federation of Neurological Societies and the Peripheral Nerve Society. *Eur J Neurol* 2010; 17: 903–12, e44–e49.
19. Grisold A, Grisold W, Dittrich C, et al. Chemotherapy induced polyneuropathy score (CIPS): A new tool in the diagnosis of chemotherapy induced polyneuropathy (CIPN). *Neuro-Oncology* 2010; 12: iii12.
20. Grisold A. Chemotherapie induzierte Polyneuropathie. Diplomarbeit, Medizinische Universität Wien, 2010.
21. Bennett GJ, Liu GK, Xiao WH, et al. Terminal arbor degeneration – a novel lesion produced by the antineoplastic agent paclitaxel. *Eur J Neurosci* 2011; 33: 1667–76.
22. Verstappen CC, Koepfen S, Heimans JJ, et al. Dose-related vincristine-induced peripheral neuropathy with unexpected off-therapy worsening. *Neurology* 2005; 64: 1076–7.
23. Chaudhry V, Chaudhry M, Crawford TO, et al. Toxic neuropathy in patients with pre-existing neuropathy. *Neurology* 2003; 60: 337–40.
24. Cavaletti G, Bogliun G, Marzotati L, et al. Grading of chemotherapy-induced peripheral neurotoxicity using the Total Neuropathy Scale. *Neurology* 2003; 61: 1297–300.
25. Cavaletti G, Frigeni B, Lanzani F, et al. Chemotherapy-Induced Peripheral Neurotoxicity assessment: A critical revision of the currently available tools. *Eur J Cancer* 2009; 46: 479–94.
26. Hughes R. NCI-CTC vs TNS: which tool is better for grading the severity of chemotherapy-induced peripheral neuropathy? *Nat Clin Pract Neurol* 2008; 4: 68–9.
27. Postma TJ, Heimans JJ. Grading of chemotherapy-induced peripheral neuropathy. *Ann Oncol* 2000; 11: 509–13.
28. Oken MM, Creech RH, Tormey DC, et al. Toxicity and response criteria of the Eastern Cooperative Oncology Group. *Am J Clin Oncol* 1982; 5: 649–55.
29. Cornblath DR, Chaudhry V, Carter K, et al. Total neuropathy score: validation and reliability study. *Neurology* 1999; 53: 1660–4.
30. Cavaletti G, Frigeni B, Lanzani F, et al. The Total Neuropathy Score as an assessment tool for grading the course of chemotherapy-induced peripheral neurotoxicity: comparison with the National Cancer Institute-Common Toxicity Scale. *J Peripher Nerv Syst* 2007; 12: 210–5.
31. Cavaletti G, Cornblath DR, Postma TJ, et al. CI-PERINOMS: chemotherapy-induced peripheral neuropathy outcome measures study. *J Peripher Nerv Syst* 2009; 14: 69–71.
32. Gill JS, Windebank AJ. Cisplatin-induced apoptosis in rat dorsal root ganglion neurons is associated with attempted entry into the cell cycle. *J Clin Invest* 1998; 101: 2842–50.
33. Jacobs JM. Vascular permeability and neurotoxicity. *Environ Health Perspect* 1978; 26: 107–16.
34. Screnci D, McKeage MJ, Galetti P, et al. Relationships between hydrophobicity, reactivity, accumulation and peripheral nerve toxicity of a series of platinum drugs. *Br J Cancer* 2000; 82: 966–72.
35. Podratz JL, Schlattau AW, Chen BK, et al. Platinum adduct formation in mitochondrial DNA may underlie the phenomenon of coasting. *J Peripher Nerv Syst* 2007; 12: 69.
36. Gregg RW, Molepo JM, Monpetit VJA, et al. Cisplatin neurotoxicity: the relationship between dosage, time, and platinum concentration in neurologic tissues, and morphologic evidence of toxicity. *J Clin Oncol* 1992; 10: 795–803.
37. Krarup-Hansen A, Fugleholm K, Helweg-Larsen S, et al. Examination of distal involvement in cisplatin-induced neuropathy in man. An electrophysiological and histological study with particular reference to touch receptor function. *Brain* 1993; 116: 1017–41.
38. Walsh TJ, Clark AW, Parhad IM, et al. Neurotoxic effects of cisplatin therapy. *Arch Neurol* 1982; 39: 719–20.
39. Thompson SW, Davis LE, Kornfeld M, et al. Cisplatin neuropathy. Clinical, electrophysiologic, morphologic, and toxicologic studies. *Cancer* 1984; 54: 1269–75.
40. Hansen SW. Autonomic neuropathy after treatment with cisplatin, vinblastine, and bleomycin for germ cell cancer. *BMJ* 1990; 300: 511–2.
41. van den Bent MJ, van Putten WL, Hilken PH, et al. Retreatment with dose-dense weekly cisplatin after previous cisplatin chemotherapy is not complicated by significant neuro-toxicity. *Eur J Cancer* 2002; 38: 387–91.
42. Roelofs RI, Hrushesky W, Rogin J, et al. Peripheral sensory neuropathy and cisplatin chemotherapy. *Neurology* 1984; 34: 934–8.
43. McKeage MJ. Comparative adverse effect profiles of platinum drugs. *Drug Safety* 1995; 13: 228–44.
44. Cavaletti G, Fabbrica D, Minoia C, et al. Carboplatin toxic effects on the peripheral nervous system of the rat. *Ann Oncol* 1998; 9: 443–7.
45. International Collaborative Ovarian Neoplasm Group. Paclitaxel plus carboplatin versus standard chemotherapy with either single-agent carboplatin or cyclophosphamide, doxorubicin, and cisplatin in women with ovarian cancer: the ICON3 randomised trial. *Lancet* 2002; 360: 505–15.
46. Hill A, Bergin P, Hanning F, et al. Detecting acute neurotoxicity during platinum chemotherapy by neurophysiological assessment of motor nerve hyperexcitability. *BMC Cancer* 2010; 23: 451.
47. Webster RG, Brain KL, Wilson RH, et al. Oxaliplatin induces hyperexcitability at motor and autonomic neuromuscular junctions through effects on voltage-gated sodium channels. *Br J Pharmacol* 2005; 146: 1027–39.
48. Tobé TJ, Braam GB, Meulenbelt J, et al. Ethylene glycol poisoning mimicking Snow White. *Lancet* 2002; 359: 444–5.
49. Gamelin L, Capitain O, Morel A, et al. Predictive factors of oxaliplatin neurotoxicity: the involvement of the oxalate outcome pathway. *Clin Cancer Res* 2007; 13: 6359–68.
50. Park SB, Lin CS, Krishnan AV, et al. Dose effects of oxaliplatin on persistent and transient Na<sup>+</sup> conductances and the development of neurotoxicity. *PLoS One* 2011; 6: e18469.
51. Park SB, Lin CS, Krishnan AV, et al. Long-term neuropathy after oxaliplatin treatment: challenging the dictum of reversibility. *Oncologist* 2011; 16: 708–16.
52. Armstrong CM, Cota G. Calcium block of Na<sup>+</sup> channels and its effect on closing rate. *Proc Natl Acad Sci USA* 1999; 96: 4154–7.
53. Gamelin E, Gamelin L, Bossi L, et al. Clinical aspects and molecular basis of oxaliplatin neurotoxicity: current management and development of preventive measures. *Semin Oncol* 2002; 29: 21–33.
54. Burakgazi AZ, Messersmith W, Vaidya D, et al. Longitudinal assessment of oxaliplatin-induced neuropathy. *Neurology* 2011; 77: 980–6.
55. Argyriou AA, Chroni E, Polychronopoulos P, et al. Efficacy of oxcarbazepine for prophylaxis against cumulative oxaliplatin-induced neuropathy. *Neurology* 2006; 67: 2253–5.
56. Makrilia N, Syrigou E, Kaklamanos I, et al. Hypersensitivity reactions associated with platinum antineoplastic agents: a systematic review. *Met Based Drugs* 2010; 2010: 207084.
57. Hoffman PC, Masters GA, Drinkard LC, et al. Ifosfamide plus paclitaxel in advanced non-small-cell lung cancer: a phase I study. *Ann Oncol* 1996; 7: 314–6.
58. Perry MC. Paclitaxel/ifosfamide or navelbine/ifosfamide chemotherapy for advanced non-small cell lung cancer. *CALGB 9532. Lung Cancer* 2000; 28: 63–8.
59. Shepherd FA. Phase I study of paclitaxel (taxol) and ifosfamide in previously untreated patients with advanced non-small-cell lung cancer. A study of the National Cancer Institute of Canada Clinical Trials Group. *Ann Oncol* 1996; 7: 311–3.
60. Klastersky J. Side effects of ifosfamide. *Oncology* 2003; 65 (Suppl 2): 7–10.
61. Spivack SD. Drugs 5 years later: procarbazine. *Ann Intern Med* 1974; 81: 795–800.
62. Gutin PH, Levi JA, Wiernik PH, et al. Treatment of malignant meningeal disease with intrathecal thioTEPA: a phase II study. *Cancer Treat Rep* 1977; 61: 885–7.
63. Martin Algarra S, Henriquez I, Rebollo J, et al. Severe polyneuropathy and motor loss after intrathecal thiotepa combination chemotherapy: description of two cases. *Anticancer Drugs* 1990; 1: 33–5.
64. Reilly KM, Kisor DF. Profile of nelarabine: use in the treatment of T-cell acute lymphoblastic leukemia. *Onco Targets Ther* 2009; 2: 219–28.
65. Buie LW, Epstein SS, Lindley CM. Nelarabine: a novel purine antimetabolite antineoplastic agent. *Clin Ther* 2007; 29: 1887–99.
66. Openshaw H, Slatkin NE, Stein AS, et al. Acute polyneuropathy after high dose cytosine arabinoside in patients with leukemia. *Cancer* 1996; 78: 1899–905.
67. Osborne WL, Holyoake TL, McQuaker IG, et al. Fatal peripheral neuropathy following FLA chemotherapy. *Clin Lab Haematol* 2004; 26: 295–6.
68. Ostermann K, Pels H, Kowoll A, et al. Neurologic complications after intrathecal liposomal cytarabine in combination with systemic polychemotherapy in primary CNS lymphoma. *J Neurooncol* 2011; 103: 635–40.
69. Gállego Pérez-Larraya J, Palma JA, Carmona-Iragui M. Neurologic complications of intrathecal liposomal cytarabine administered prophylactically to patients with non-Hodgkin lymphoma. *J Neurooncol* 2011; 103: 603–9.
70. Colomer R, Llombart-Cussac A, Lluh A, et al. Biweekly paclitaxel plus gemcitabine in advanced breast cancer: phase II trial and predictive value of HER2 extracellular domain. *Ann Oncol* 2004; 15: 201–6.
71. Stein ME, Drumea K, Yarnitsky D, et al. A rare event of 5-fluorouracil-associated peripheral neuropathy after oxaliplatin treatment: a report of two patients. *Am J Clin Oncol* 1998; 21: 248–9.
72. Saif MW, Wood TE, McGee PJ, et al. Peripheral neuropathy associated with capecitabine. *Anticancer Drugs* 2004; 15: 767–71.
73. Dasgupta S, Adiljee C, Bhattacharya A, et al. Capecitabine and sixth cranial nerve palsy. *J Cancer Res Ther* 2010; 6: 80–1.
74. Couch LS, Groteluschen DL, Stewart JA, et al. Capecitabine-related neurotoxicity presenting as trismus. *Clin Colorectal Cancer* 2003; 3: 121–3.
75. Stubblefield MD, Custodio CM, Kaufmann P, et al. Small-fiber neuropathy associated with capecitabine (Xeloda)-induced hand-foot syndrome: A case report. *J Clin Neuromuscul Dis* 2006; 7: 128–32.
76. Paulson JC, McClure WO. Inhibition of axoplasmic transport by colchicine, podophyllotoxin, and vinblastine: an effect on microtubules. *Ann N Y Acad Sci* 1975; 253: 517–27.
77. Schaumburg H. Vinca alkaloids. In: Schaumburg H, Spencer P (eds). *Experimental and Clinical Neurotoxicology*. 2<sup>nd</sup> ed. Oxford University Press, New York, 2000; 1232–5.
78. Fazey B, Zifko U, Meryn S, et al. Vinorelbine-induced neurotoxicity in patients with advanced breast cancer pretreated with paclitaxel – a phase II study. *Cancer Chemother Pharmacol* 1996; 39: 150–6.
79. DeAngelis LM, Gnecco C, Taylor L, et al. Evolution of neuropathy and myopathy during intensive vincristine/corticosteroid chemotherapy for non-Hodgkin's lymphoma. *Cancer* 1991; 67: 2241–6.
80. Burns BV, Shotton JC. Vocal fold palsy following vinca alkaloid treatment. *J Laryngol Otol* 1998; 112: 485–7.
81. Sanderson PA, Kuwabara T, Cogan DG. Optic neuropathy presumably caused by vincristine therapy. *Am J Ophthalmol* 1976; 81: 146–50.
82. Kalciglu MT, Kuku I, Kaya E, et al. Bilateral hearing loss during vincristine therapy: a case report. *J Chemother* 2003; 15: 290–2.
83. Low PA, Vernino S, Suarez G. Autonomic dysfunction in peripheral nerve disease. *Muscle Nerve* 2002; 27: 646–61.
84. Moudgil SS, Riggs JE. Fulminant peripheral neuropathy with severe quadripareisis associated with vincristine therapy. *Ann Pharmacother* 2000; 34: 1136–8.
85. Chauvenet AR, Shashi V, Selsky C, et al. Vincristine-induced neuropathy as the initial presentation of Charcot-Marie-Tooth disease in acute lymphoblastic leukemia: a Pediatric Oncology Group study. *J Pediatr Hematol Oncol* 2003; 25: 316–20.
86. Igarashi M, Thompson EI, Rivera GK. Vincristine neuropathy in type I and type II Charcot-Marie-Tooth disease (hereditary motor sensory neuropathy). *Med Pediatr Oncol* 1995; 25: 113–6.
87. Geis C, Beyreuther BK, Stöhr T, et al. Lacosamide has protective disease modifying properties in experimental vincristine neuropathy. *Neuropharmacology* 2011; 61: 600–7.
88. Egbelakin A, Ferguson MJ, MacGill EA, et al. Increased risk of vincristine neurotoxicity associated with low CYP3A5 expres-

- sion genotype in children with acute lymphoblastic leukemia. *Pediatr Blood Cancer* 2011; 56: 361–7.
89. Dyke RW. Treatment of inadvertent intrathecal injection of vincristine. *N Engl J Med* 1989; 321: 1270–1.
90. Qweider M, Gilsbach JM, Rohde V. Inadvertent intrathecal vincristine administration: a neurosurgical emergency. Case report. *J Neurosurg Spine* 2007; 6: 280–3.
91. Hilken PH, Verweij J, Vecht CJ, et al. Clinical characteristics of severe peripheral neuropathy induced by docetaxel (Taxotere). *Ann Oncol* 1997; 8: 187–90.
92. Scripture CD, Figg WD, Sparreboom A. Paclitaxel chemotherapy: from empiricism to a mechanism-based formulation strategy. *Ther Clin Risk Manag* 2005; 1: 107–14.
93. Apfel S. Taxoids. In: Schaumburg H, Spencer P (eds). *Experimental and Clinical Neurotoxicology*. 2<sup>nd</sup> ed. Oxford University Press, New York, 2000; 1135–9.
94. Postma TJ, Vermorken JB, Liefthoek AJ, et al. Paclitaxel-induced neuropathy. *Ann Oncol* 1995; 6: 489–94.
95. Freilich RJ, Balmaceda C, Seidman AD, et al. Motor neuropathy due to docetaxel and paclitaxel. *Neurology* 1996; 47: 115–8.
96. Siau C, Xiaow W, Bennetta GJ. Paclitaxel and vincristine-evoked painful peripheral neuropathies: Loss of epidermal innervation and activation of Langerhans cells. *Exp Neurol* 2006; 201: 507–14.
97. Bennett GJ, Liu GK, Xiao WH, et al. Terminal arbor degeneration – a novel lesion produced by the antineoplastic agent paclitaxel. *Eur J Neurosci* 2011; 33: 1667–76.
98. Sissung TM, Baum CE, Deeken J, et al. ABCB1 genetic variation influences the toxicity and clinical outcome of patients with androgen-independent prostate cancer treated with docetaxel. *Clin Cancer Res* 2008; 14: 4543–9.
99. Guastalla JP, Diéras V. The taxanes: toxicity and quality of life considerations in advanced ovarian cancer. *Br J Cancer* 2003; 89 (Suppl 3): 16–22.
100. Thornton LM, Carson WE, Shapiro CL, et al. Delayed emotional recovery after taxane-based chemotherapy. *Cancer* 2008; 113: 638–47.
101. Goel S, Goldberg GL, Kuo YS, et al. Novel neurosensory testing in cancer patients treated with the epothilone B analog, ixabepilone. *Ann Oncol* 2008; 19: 2048–52.
102. Camps C, Felip E, Sanchez JM, et al. Phase II trial of the novel taxane BMS-184476 as second-line in non-small-cell lung cancer. *Ann Oncol* 2005; 16: 597–601.
103. Lee JJ, Low JA, Croarkin E, et al. Changes in neurologic function tests may predict neurotoxicity caused by ixabepilone. *J Clin Oncol* 2006; 24: 2084–91.
104. Wozniak KM, Nomoto K, Lapidus RG, et al. Comparison of neuropathy-inducing effects of eribulin mesylate, paclitaxel, and ixabepilone in mice. *Cancer Res* 2011; 71: 3952–62.
105. Boillot A, Cordier A, Guerault E, et al. A rare case of severe toxic peripheral neuropathy: poisoning by podophyllin. Apropos of 1 case. *J Toxicol Clin Exp* 1989; 9: 409–12.
106. Garcia AA, Roman L, Muderspach L, et al. Phase I clinical trial of topotecan and pegylated liposomal doxorubicin. *Cancer Invest* 2005; 23: 665–70.
107. Giaccone G. Teniposide alone and in combination chemotherapy in small cell lung cancer. *Semin Oncol* 1992; 19 (Suppl 6): 75–80.
108. Corthals SL, Kuiper R, Johnson DC, et al. Genetic factors underlying the risk of bortezomib induced peripheral neuropathy in multiple myeloma patients. *Haematologica* 2011; 96: 1728–32.
109. Chan ML, Stewart AK. Carfilzomib: a novel second-generation proteasome inhibitor. *Future Oncol* 2011; 7: 607–12.
110. O'Connor OA, Stewart AK, Vallone M, et al. A phase 1 dose escalation study of the safety and pharmacokinetics of the novel proteasome inhibitor carfilzomib (PR-171) in patients with hematologic malignancies. *Clin Cancer Res* 2009; 15: 7085–91.
111. Cavaletti G, Nobile-Orazio E. Bortezomib-induced peripheral neurotoxicity: still far from a painless gain. *Haematologica* 2007; 92: 1308–10.
112. Farquhar-Smith P. Chemotherapy-induced neuropathic pain. *Curr Opin Support Palliat Care* 2011; 5: 1–7.
113. Cavaletti G, Jakubowiak AJ. Peripheral neuropathy during bortezomib treatment of multiple myeloma: a review of recent studies. *Leuk Lymphoma* 2010; 51: 1178–87.
114. Sonneveld P, Jongen JL. Dealing with neuropathy in plasma-cell dyscrasias. *Hematology Am Soc Hematol Educ Program* 2010; 2010: 423–30.
115. Argyriou AA, Iconomou G, Kalofonos HP. Bortezomib-induced peripheral neuropathy in multiple myeloma: a comprehensive review of the literature. *Blood* 2008; 112: 1593–9.
116. El-Cheikh J, Stoppa AM, Bouabdallah R, et al. Features and risk factors of peripheral neuropathy during treatment with bortezomib for advanced multiple myeloma. *Clin Lymphoma Myeloma* 2008; 8: 146–52.
117. Stübgen JP. Drug induced dysimmune demyelinating neuropathies. *J Neurol Sci* 2011; 307: 1–8.
118. Ravaglia S, Corso A, Piccolo G. Immune-mediated neuropathies in myeloma patients treated with bortezomib. *Clin Neurophysiol* 2008; 119: 2507–12.
119. Chaudhry V, Cornblath DR, Polydefkis M, et al. Characteristics of bortezomib- and thalidomide-induced peripheral neuropathy. *J Peripher Nerv Syst* 2008; 13: 275–82.
120. Hu J, Fang J, Dong Y, et al. Arsenic in cancer therapy. *Anticancer Drugs* 2005; 16: 119–27.
121. Zhou J, Zhang Y, Li J, et al. Single-agent arsenic trioxide in the treatment of children with newly diagnosed acute promyelocytic leukemia. *Blood* 2010; 115: 1697–702.
122. Matthews SJ, McCoy C. Thalidomide: a review of approved and investigational uses. *Clin Ther* 2003; 25: 342–95.
123. Mazumder A, Jagannath S. Thalidomide and lenalidomide in multiple myeloma. *Best Pract Res Clin Haematol* 2006; 19: 769–80.
124. Palumbo A, Bringhen S, Ludwig H, et al. Personalized therapy in multiple myeloma according to patient age and vulnerability: a report of the European Myeloma Network (EMN). *Blood* 2011; 118: 4519–29.
125. Hussein MA. Lenalidomide: patient management strategies. *Semin Hematol* 2005; 42 (Suppl 4): S22–S25.
126. Richardson PG, Weller E, Lonial S, et al. Lenalidomide, bortezomib, and dexamethasone combination therapy in patients with newly diagnosed multiple myeloma. *Blood* 2010; 116: 679–86.
127. Mateos MV. Management of treatment-related adverse events in patients with multiple myeloma. *Cancer Treat Rev* 2010; 36 (Suppl 2): S24–S32.
128. Chaudhry V, Eisenberger MA, Sinibaldi VJ, et al. A prospective study of suramin-induced peripheral neuropathy. *Brain* 1996; 119: 2039–52.
129. <http://www.ehealthme.com/>
130. Foyil KV, Bartlett NL. Brentuximab vedotin for the treatment of CD30+ lymphomas. *Immunotherapy* 2011; 3: 475–85.
131. Hussain MH, MacVicar GR, Petrylak DP, et al. National Cancer Institute. Trastuzumab, paclitaxel, carboplatin, and gemcitabine in advanced human epidermal growth factor receptor-2/neu-positive urothelial carcinoma: results of a multicenter phase II National Cancer Institute trial. *J Clin Oncol* 2007; 25: 2218–24.
132. Toyooka K, Fujimura H. Iatrogenic neuropathies. *Curr Opin Neurol* 2009; 22: 475–9.
133. Semiglazov VF, Semiglazov VV, Dashyan GA, et al. Phase 2 randomized trial of primary endocrine therapy versus chemotherapy in postmenopausal patients with estrogen receptor-positive breast cancer. *Cancer* 2007; 110: 244–54.
134. Nishihori T, Choi J, DiGiovanna MP, et al. Carpal tunnel syndrome associated with the use of aromatase inhibitors in breast cancer. *Clin Breast Cancer* 2008; 8: 362–5.
135. Melgaard B, Kähler O, Sand Hansen H, et al. Misonidazole neuropathy. A prospective study. *J Neurooncol* 1988; 6: 227–30.
136. Arrieta O, Hernández-Pedro N, Fernández-González-Aragón MC, et al. Retinoic acid reduces chemotherapy-induced neuropathy in an animal model and patients with lung cancer. *Neurology* 2011; 77: 987–95.
137. Mesa RA. Tipifarnib: farnesyl transferase inhibition at a crossroads. *Expert Rev Anticancer Ther* 2006; 6: 313–9.
138. Perez-Ruixo JJ, Chen W, Zhang S, et al. Exposure-toxicity relationships for tipifarnib in cancer patients. *Br J Clin Pharmacol* 2007; 64: 219–32.
139. Kelly JJ, Karcher DS. Lymphoma and peripheral neuropathy: a clinical review. *Muscle Nerve* 2005; 31: 301–13.
140. Broyl A, Corthals SL, Jongen JL, et al. Mechanisms of peripheral neuropathy associated with bortezomib and vincristine in patients with newly diagnosed multiple myeloma: a prospective analysis of data from the HOVON-65/GMMG-HD4 trial. *Lancet Oncol* 2010; 11: 1057–65.
141. Becker PS. Genetic predisposition for chemotherapy-induced neuropathy in multiple myeloma. *J Clin Oncol* 2011; 29: 783–6.
142. Bang SM, Lee JH, Yoon SS, et al. A multicenter retrospective analysis of adverse events in Korean patients using bortezomib for multiple myeloma. *Int J Hematol* 2006; 83: 309–3.
143. Palumbo A, Mateos MV, Bringhen S, et al. Practical management of adverse events in multiple myeloma: can therapy be attenuated in older patients? *Blood Rev* 2011; 25: 181–91.
144. Kuwabara S, Dispenzieri A, Arimura K, et al. Treatment for POEMS (polyneuropathy, organomegaly, endocrinopathy, M-protein, and skin changes) syndrome. *Cochrane Database Syst Rev* 2008; (4): CD006828.
145. Briani C, Vitaliani R, Grisold W, et al. Spectrum of paraneoplastic disease associated with lymphoma. *Neurology* 2011; 76: 705–10.
146. Grisariu S, Avni B, Batchelor TT, et al. Neurolymphomatosis: an International Primary CNS Lymphoma Collaborative Group report. *Blood* 2010; 115: 5005–11.
147. Jiang QL, Pytel P, Rowin J. Disseminated intravascular large-cell lymphoma with initial presentation mimicking Guillain-Barré syndrome. *Muscle Nerve* 2010; 42: 133–6.
148. Aregawi DG, Sherman JH, Douvas MG, et al. Neuroleukemiosis: case report of leukemic nerve infiltration in acute lymphoblastic leukemia. *Muscle Nerve* 2008; 38: 1196–200.
149. Argyriou AA, Chroni E, Koutras A, et al. Vitamin E for prophylaxis against chemotherapy-induced neuropathy: A randomized controlled trial. *Neurology* 2005; 64: 26–31.
150. Bianchi G, Vitali G, Caraceni A, et al. Symptomatic and neurophysiological responses of paclitaxel- or cisplatin-induced neuropathy to oral acetyl-L-carnitine. *Eur J Cancer* 2005; 41: 1746–50.
151. De Grandis D. Acetyl-L-carnitine for the treatment of chemotherapy-induced peripheral neuropathy: a short review. *CNS Drugs* 2007; 21: 39–43.
152. Gandara DR, Nahhas WA, Adelson MD, et al. Randomized placebo-controlled multicenter evaluation of diethyldithiocarbamate for chemoprotection against cisplatin-induced toxicities. *J Clin Oncol* 1995; 13: 490–6.
153. Lersch C, Schmelz R, Eckel F, et al. Prevention of oxaliplatin-induced peripheral sensory neuropathy by carbamazepine in patients with advanced colorectal cancer. *Clin Colorectal Cancer* 2002; 2: 54–8.
154. Kassem LA, Yassin NA. Role of erythropoietin in prevention of chemotherapy-induced peripheral neuropathy. *Pak J Biol Sci* 2010; 13: 577–87.
155. Argyriou AA, Zolota V, Kyriakopoulou O, et al. Toxic peripheral neuropathy associated with commonly used chemotherapeutic agents. *J BUON* 2010; 15: 435–46.
156. Walker M, Ni O. Neuroprotection during chemotherapy: a systematic review. *Am J Clin Oncol* 2007; 30: 82–92.
157. Wolf S, Barton D, Kottschade L, et al. Chemotherapy-induced peripheral neuropathy: prevention and treatment strategies. *Eur J Cancer* 2008; 44: 1507–15.
158. Albers JW, Chaudhry V, Cavaletti G, et al. Interventions for preventing neuropathy caused by cisplatin and related compounds. *Cochrane Database Syst Rev* 2011; (2): CD005228.
159. Grisold W, Vass A, Schmidhammer R, et al. Rehabilitation of neuropathies. *Crit Rev Physical Rehabil Med* 2007; 19: 19–53.
160. Stubblefield MD. Cancer rehabilitation. *Semin Oncol* 2011; 38: 386–93.
161. Hile ES, Fitzgerald GK, Studenski SA. Persistent mobility disability after neurotoxic chemotherapy. *Phys Ther* 2010; 90: 1649–57.