

Percutaneous pedicle screw fixation of the lumbar spine: preliminary clinical results

KEVIN T. FOLEY, M.D., AND SANJAY K. GUPTA, M.D.

Image-Guided Surgery Research Center, James Murphy Clinic and Department of Neurosurgery, University of Tennessee, Memphis, Tennessee

Object. Standard techniques for pedicle screw fixation of the lumbar spine involve open exposures and extensive muscle dissection. The purpose of this study was to report the initial clinical experience with a novel device for percutaneous posterior fixation of the lumbar spine.

Methods. An existing multiaxial lumbar pedicle screw system was modified to allow screws to be placed percutaneously by using an extension sleeve that permits remote manipulation of the polyaxial screw heads and remote engagement of the screw-locking mechanism. A unique rod-insertion device was developed that linked to the screw extension sleeves, allowing for a precut and -contoured rod to be placed through a small stab wound. Because the insertion device relies on the geometrical constraint of the rod pathway through the screw heads, minimal manipulation is required to place the rods in a standard submuscular position, there is essentially no muscle dissection, and the need for direct visual feedback is avoided. Twelve patients (six men and six women) who ranged in age from 23 to 68 years underwent pedicle screw fixation in which the rod-insertion device was used. Spondylolisthesis was present in 10 patients and osseous nonunion of a prior interbody fusion was present in two. All patients underwent successful percutaneous fixation. Ten patients underwent single-level fusions (six at L5–S1, three at L4–5, and one at L2–3), and two underwent two-level fusions (one from L3–5 and the other from L4–S1). The follow-up period ranged from 10 to 19 months (mean 13.8 months).

Conclusions. Although percutaneous lumbar pedicle screw placement has been described previously, longitudinal connector (rod or plate) insertion has been more problematic. The device used in this study allows for straightforward placement of lumbar pedicle screws and rods through percutaneous stab wounds. Paraspinal tissue trauma is minimized without compromising the quality of spinal fixation. Preliminary experience involving the use of this device has been promising.

KEY WORDS • percutaneous surgery • lumbar spine • pedicle screw • fixation

THE use of pedicle screw–assisted spinal stabilization has become increasingly popular worldwide. Pedicle screw systems engage all three columns of the spine and can resist motion in all planes. Analysis of several studies suggests that pedicle screw fixation is a safe and effective treatment for many spinal disorders.^{4,14} Standard techniques for pedicle screw placement, however, require extensive tissue dissection to expose entry points and to provide for lateral-to-medial orientation for optimum screw trajectory. Open pedicle fixation and spinal fusion have been associated with extensive blood loss, lengthy periods of hospitalization, and significant cost.¹²

The purpose of this paper is to describe a technique and instrumentation designed by the senior author (K.T.F.) for minimally invasive posterior fixation of the lumbar spine in which percutaneous screws and rods (Sextant; Medtronic Sofamor Danek, Memphis, TN) are used. Our initial clinical experience will also be included. Although the insertion of percutaneous lumbar pedicle screws has been previous-

ly reported,^{6–8} a minimally invasive technique involving insertion of a longitudinal connector for these screws has proven more challenging. The Sextant system allows for the straightforward placement of lumbar pedicle screws and rods through percutaneous stab wounds. The screws and rods are placed in an anatomical position similar to that achieved by an analogous open surgical approach. Paraspinal tissue trauma is greatly minimized without sacrificing the quality of the spinal fixation. Our preliminary experience with this technique has been promising.

Clinical Material and Methods

Patient Population

Preoperatively all patients presented with mechanical back pain. Radiculopathy, when present, was caused by entrapment of an exiting nerve root within a collapsed neuroforamen. The provision of appropriate conservative therapy had failed to relieve patients of their symptoms. There were six men and six women who ranged in age from 23 to 68 years.

Radiographically documented findings were correlated

Abbreviations used in this paper: AP = anteroposterior; MED = microendoscopic discectomy.

with clinical findings. Grade I spondylolisthesis was present in six patients, Grade II in three, and Grade III in one. Two patients presented with osseous nonunion after having undergone a previous fusion. Ten patients required a single-level fusion, and two patients required a two-level fusion. Of the single-level fusions, one was performed at L2–3, three at L4–5, and six at L5–S1. Of the two-level procedures, there was one L3–5 and one L4–S1 fusion.

Patient Positioning and Operating Room Setup

Percutaneous posterior fixation of the lumbar spine can be performed after induction of general or epidural anesthesia. Thereafter, the patient is positioned prone on top of chest rolls with the abdomen free. A C-arm fluoroscopy device is used for guidance of percutaneous screw placement. Although conventional fluoroscopy can be used for this purpose,⁵ it is associated with the following disadvantages: the inability to visualize more than one plane of view at a single time (when using a single fluoroscope), the ergonomic challenges of working around a C-arm, and radiation exposure.^{9–11} Instead, we have used virtual fluoroscopy (FluoroNav; Medtronic Surgical Navigation Technologies, Louisville, CO) for guiding screw placement because it avoids the aforementioned disadvantages (see *Virtual Fluoroscopy*). Regardless of whether one uses conventional or virtual fluoroscopic guidance for the procedure, it is important to determine whether adequate AP and lateral fluoroscopic images of the lumbar spine can be obtained before preparing and draping the patient.

Virtual Fluoroscopy

In virtual fluoroscopy an image-guided surgical computer is combined with C-arm fluoroscopy.^{1,2,10} A light-emitting diode–fitted calibration target is applied to the C-arm. An optical camera is used to track the fluoroscope as well as a spinal dynamic reference array and various spinal surgical tools including a pedicle awl, a pedicle probe, bone taps, and a screwdriver. After fluoroscopic images of the lumbar spine are obtained, they are sent to and saved in the image guidance computer, where they are automatically calibrated. The process is independent of surgical exposure and enables percutaneous spinal registration. The real-time location of the tracked tools is graphically projected onto the previously acquired fluoroscopic images. These previously acquired images can be obtained in multiple planes (that is, AP, lateral, and oblique), and the tools can be tracked simultaneously on all images. The advantages of virtual fluoroscopy over a conventional C-arm unit include this simultaneous multiplanar guidance capability, decreased radiation exposure,⁹ and the ability to quantify radiographically obtained data.^{1,2}

Initial Incision and Pedicle Identification

If virtual fluoroscopic guidance is used, a dynamic reference array is first inserted. A small incision is made over the spinous process at the level above the planned site of the segmental fusion. Lateral fluoroscopy is performed to localize this spinous process, and the incision is brought down through the fascia. A percutaneous reference array is then attached to the spinous process. Fluoroscopic images are obtained in the AP and lateral planes to ensure

that the pedicles can be adequately visualized. If necessary, oblique (owl's-eye) views can be acquired as well. These images are automatically calibrated (activated) using the FluoroNav software.

Using the FluoroNav sharp tip probe, entry points are chosen for the pedicles that are to be fitted with instrumentation. The software allows the instrument tip to be virtually extended so that an ideal trajectory, which traverses the underlying pedicle, can be chosen. An approximately 15-mm incision is made at the skin entry point and extended into the underlying subcutaneous tissue. A K-wire is used to perforate the fascia, and a series of sequential dilators are then used to dilate the fascia and to separate bluntly the underlying paraspinous muscles down to the spine.³ The dilators are removed, and both a tracked awl and a pedicle probe are used to create a pedicle pilot hole under virtual fluoroscopic guidance. Using the FluoroNav software, both the length and diameter of the pedicle screw may be chosen at this time.

Pedicle Screw Placement

Using real-time multiplanar virtual fluoroscopy image guidance, the chosen pedicles are tapped and screws are placed. A thorough knowledge of pedicle-related anatomy and the sagittal and axial angulation of the individual pedicles is mandatory for safe percutaneous screw placement.¹³ These angles are best judged using preoperative computerized tomography or magnetic resonance imaging of the lumbar region. In our experience biplanar virtual fluoroscopic guidance of the transpedicular trajectory is helpful. The pedicle is a roughly cylindrical structure. If one enters the pedicle at its lateral margin and exits the structure lateral to its medial wall (enough to accommodate the anticipated screw diameter), the pedicle can be navigated safely. Such a trajectory can be chosen using the FluoroNav software to extend the tip of the pedicle awl or probe virtually prior to traversing the pedicle. The tip is extended on the lateral fluoroscopic image until it reaches the pedicle–vertebral body junction, keeping the sagittal angulation of the instrument aligned so that its trajectory bifurcates the pedicle on the lateral view. The axial angulation of the instrument is adjusted until the extended tip is visualized within the boundaries of the pedicle on the AP view but lateral to the medial pedicle wall (Fig. 1).

Alternatively, the pedicle can be navigated by using a conventional C-arm fluoroscope that is alternated between AP, lateral, and oblique views. If this technique is chosen, one must obtain multiple sequential images of the pedicle probe in at least two planes as it is advanced down the pedicle.^{4,13} It is important to keep these trajectories in mind to ensure the accuracy of the percutaneous screw placement. One advantage of percutaneous screw placement over the conventional open procedure, however, is that it is much easier to achieve the required medial angulation because extensive soft-tissue and muscle retraction is avoided.

Rod Placement

The multiaxial Sextant pedicle screws are attached to screw extenders, which have inner and outer sleeves. The inner extender sleeve is designed to be preloaded with a lock plug, which will eventually connect the screw to the

Percutaneous pedicle screw fixation

rod. The outer sleeve actually extends over the multiaxial screw head. The inner sleeve starts in a first position that allows the lock plug to be partially advanced into the multiaxial screw head, by which the screw is connected to the extender–sleeve combination. The screw head remains mobile on its shank. Thus, the screw head can be manipulated remotely (rotated and angulated) by moving the far end of the screw extender even after the screw has been placed within the pedicle (Fig. 2 upper).

After a pair of pedicle screws, together with their attached extenders, has been inserted, a Sextant rod is placed. The Sextant rods are precontoured into a curvilinear shape that precisely matches the contour of the Sextant rod inserter. The rods are designed to fix rigidly to the inserter, forming a smooth arc. Additionally, the Sextant inserter attaches to the screw extenders. The resulting arrangement resembles the navigational device of the same name.

The screw extenders are aligned at their proximal ends. This maneuver arranges the distal ends, which are connected to the multiaxial screw heads, in a way that allows the openings in the screw heads to fit the same curvilinear path of the precontoured rod. The geometrical configuration is such that this path is identical to the arc created by the rod–Sextant rod inserter union. In fact, once the joined screw extenders are attached to the rod inserter, this geometrical relationship is constrained. The arc, subtended by the inserter–rod combination, must now follow the path connecting both screw heads (Fig. 2 center).

After the screw extenders have been connected to the Sextant rod inserter, a trochar tip is attached to the inserter. The skin is marked where this tip intersects it, and a small stab wound is made using a No. 15 blade. The trochar tip serves to open the underlying fascia. Once the fascia has been penetrated, the tip is removed and a Sextant rod is attached. The rod is inserted through the same stab wound and intersects the screw heads (Fig. 2 lower). This is



FIG. 2. Photographs. *Upper*: A multi-axial screw head can be manipulated using the screw extenders even after the screw is inserted. The screw heads are manipulated (angulated and rotated) and aligned to accommodate the trajectory of the Sextant rod. This alignment occurs automatically when the screw extenders are connected. *Center*: The inserter–rod combination follows the curvilinear path connecting both screw head openings. The precontoured rod is seated in the screw heads in a reproducible, predictable fashion. *Lower*: The rod inserter pictured after the rod is in final position. The percutaneous reference array base (arrow) is

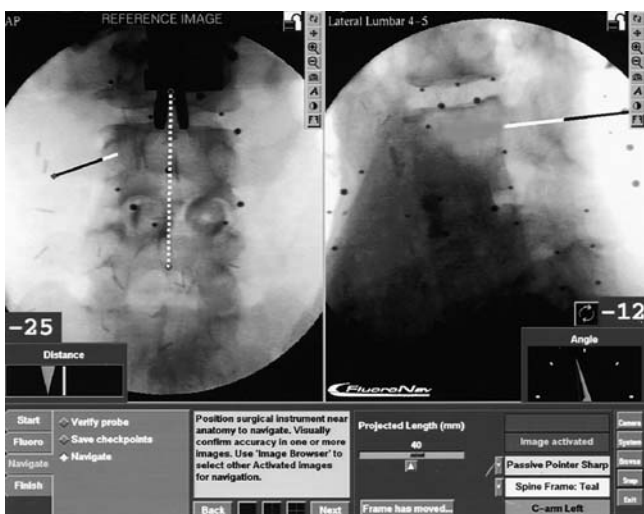


FIG. 1. Virtual fluoroscopic pedicle probe guidance. The virtual probe (black line) can be seen on the AP and lateral virtual fluoroscopic images. The probe's proposed trajectory is then extended (white line) to ensure that, as the probe reaches the base of the pedicle, it will lie safely within the pedicle cylinder on the AP and lateral views.

TABLE 1
Summary of preoperative findings and fusions levels

Characteristic	No. of Patients
male	6
female	6
preop findings	
Grade I spondylolisthesis	6
Grade II spondylolisthesis	3
Grade III spondylolisthesis	1
nonunion of prior fusion	2
no. of levels	
1	10
2	2

checked fluoroscopically. Appropriate forces (compression and/or distraction) can be applied to the construct prior to final tightening. The inner sleeves are now advanced to their second position, allowing a hex driver to be inserted and to permit tightening of the lock plugs. The lock plugs are designed with a torque-limiting breakoff, which allows simultaneous locking of the rod to the screw while the extension sleeve detaches. The Sextant itself serves as a counter-torque device. The rod is remotely released from the Sextant inserter, and the latter is removed from the field, leaving a percutaneous rod-screw combination in place. The procedure can be repeated on the contralateral side of the spine, after which the stab incisions are irrigated and closed.

Results

The initial clinical results obtained using the Sextant system for percutaneous posterior fixation of the lumbar spine have been promising. This is a new procedure, however, and the results are only preliminary. Twelve consecutive patients underwent placement of percutaneous pedicle screws and rods (Table 1). Ten of the cases involved a single motion segment. Two-level application of the system, performed in two cases, was not found to be significantly more technically demanding than single-level use. All of the percutaneous posterior fixation procedures were preceded by fusion performed during the same operative session. In 10 patients, an anterior lumbar interbody fusion was first performed;¹⁵ in one patient, interbody fusion was performed via a minimally invasive lateral retroperi-

TABLE 2
Modified Macnab criteria for characterizing outcome after spinal surgery

Result	Criteria
excellent	no pain; no restriction of mobility; return to normal work & level of activity
good	occasional nonradicular pain; relief of presenting symptoms; able to return to modified work
fair	some improved functional capacity; still handicapped & unemployed
poor	continued objective symptoms of nerve root involvement; additional op intervention needed at the index level irrespective of postop follow-up duration

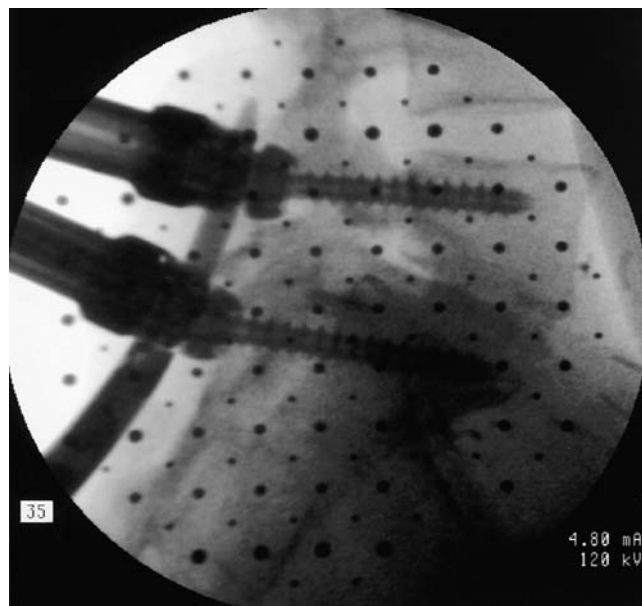


FIG. 3. Intraoperative fluoroscopic image confirming the correct placement of the percutaneous rod.

toneal approach; and in another patient, an MED tubular retractor system was used for a percutaneous onlay fusion at L5-S1.³ Data were collected in a prospective manner.

One complication was noted. In one patient a lock plug loosened early in the clinical series, and this necessitated outpatient surgery for replacement of the loosened hardware. The event was asymptomatic, noted on routine follow-up radiographs; a solid fusion resulted, and the patient experienced a good clinical outcome. Based on this incident, the lock plugs were redesigned; no other incidents of loosening have been noted.

All operations were performed using the aforementioned technique. The operative time ranged from 90 to 220 minutes; the longer times occurred early in the learning curve. Fifty percent of the patients were discharged on postoperative Day 1 or 2, and the remaining patients were discharged on postoperative Day 3. Interestingly, the longer hospital stays typically related to ileus secondary to an anterior approach for fusion.

The follow-up period ranged from 10 to 19 months (mean 13.8 months). All patients improved clinically, and outcome was classified using the modified Macnab criteria⁶ (Table 2). Results were considered excellent in six patients, good in five, and poor in one. Although this latter patient fared well clinically, he required reoperation for hardware revision as previously noted. In all patients solid fusions were documented.

Illustrative Case

This 23-year-old woman presented with recurrent mechanical low-back pain after having undergone a laparoscopic L5-S1 interbody fusion 1 year previously. Thin-section computerized tomography scanning revealed a nonunion. Revision of this lesion was undertaken in a minimally invasive fashion. A percutaneous approach to the L-5 transverse process and sacral ala was performed bilaterally by

Percutaneous pedicle screw fixation

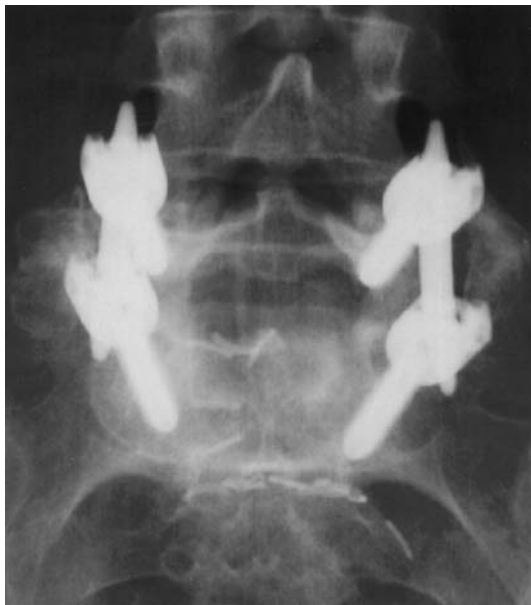

FIG. 4. Anteroposterior radiograph demonstrating acceptable screw placement and bilateral posterolateral fusion.

using the MED technique.³ Autologous bone graft was harvested by angling the MED tube toward the iliac crest via the original paramedian 3-cm incisions. Through the same tubular retractors, the L-5 transverse process and sacral ala were decorticated bilaterally, and onlay fusion was performed with the autologous graft material. The tubular retractors were removed, and percutaneous placement of Sextant screws was conducted via the same paramedian stab wounds that were used for the fusion. A fluoroscopic lateral image of the rod placement is shown in Fig. 3. Postoperative AP (Fig. 4) and lateral radiography revealed good positioning of the hardware and a bilateral posterolateral fusion mass. A photograph of the patient's incisions is shown in Fig. 5.

Discussion

Percutaneous fixation of the lumbar spine was first described by Magerl,⁷ who used an external fixator. Mathews and Long⁸ first described and performed a wholly percutaneous lumbar pedicle fixation procedure in which they used plates as the longitudinal connectors. Lowery and Kulkarni⁵ subsequently described a similar procedure in which rods were placed. Although the latter authors reported a high success rate, Mathews and Long noted a significant rate of nonunion (HH Mathews, personal communication, 2001). In all cases, the longitudinal connectors were placed either externally⁷ or superficially, just beneath the skin.^{5,8} This has several potential disadvantages. First, the superficial hardware can be irritating and requires routine removal.⁵ Second, longer screws (and thus longer moment arms) are required, producing less effective biomechanical stabilization than that achieved using standard pedicle fixation systems and thus leading to a higher implant failure-related potential.

The use of the Sextant system, with or without virtual fluoroscopy, offers several distinct advantages over con-

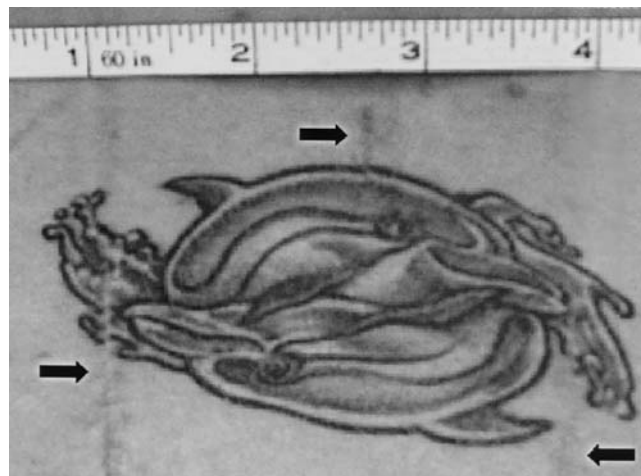


FIG. 5. Photograph demonstrating that the small stab incisions are barely discernible (*arrows*). This patient's tattoo was preserved even though it was located in the lumbar midline, directly over the operative site.

ventional pedicle screw fixation. The system eliminates the need for a large midline incision and significant paraspinous muscle dissection. Both the pedicle screws and the precontoured rod are placed through stab incisions. The paraspinous muscles are bluntly split rather than divided, leading to potentially shorter periods of hospitalization and recovery.³ Blood loss and tissue trauma are minimized. An ideal lateral-to-medial screw trajectory is much more easily accomplished, especially in larger patients, because significant paraspinous tissue retraction is avoided.

Compared with previously used percutaneous techniques, the Sextant procedure allows the screw-rod system to be placed in a standard anatomical position. This optimizes the biomechanics of the fixation and keeps the hardware in place without irritating the superficial tissues of the low back, thus avoiding routine hardware removal. In addition, this technique minimizes much of the "fiddle factor" related to connecting a percutaneous rod or plate to pedicle screws. The inserter geometrically constrains the rod's pathway, simplifying insertion of the rod. The cannulated extension sleeves allow the lock plugs to be quickly and easily seated against the rod and thereby simplifies screw-rod connection. Because the Sextant inserter remains connected to the screws and rods, appropriate forces (compression and distraction) can be applied to the construct prior to final tightening.

Minimally invasive approaches for performing lumbar fusion are in their infancy. Laparoscopic anterior lumbar interbody fusion has only been recently described.¹⁵ Other minimally invasive approaches to lumbar fusion, such as the posterolateral MED onlay technique described in this paper, are evolving. The goal of these surgeries, as for all minimally invasive procedures, is to minimize approach-related morbidity while achieving the same result as more traditional, invasive approaches. The technique involved in placing the Sextant system follows these same principles, allowing the surgeon to perform biomechanically sound internal spinal fixation with minimal tissue trauma. Combined with techniques for minimally invasive spinal

fusion and decompression,³ its clinical utility should increase. Certainly the preliminary clinical results presented in this paper are promising.

Acknowledgments

The authors acknowledge Michael Sherman and Jeff Justis, engineers at Medtronic Sofamor Danek, for their significant contributions to the development of the Sextant system.

Financial Disclosure

Research support was provided by Medtronic Sofamor Danek, to which Dr. Foley is a consultant.

References

1. Foley KT, Simon DA, Rampersaud YR: Virtual fluoroscopy. **Op Tech Orthop** 10:77–81, 2000
2. Foley KT, Simon DA, Rampersaud YR: Virtual fluoroscopy: computer-assisted fluoroscopic navigation. **Spine** 26:347–351, 2001
3. Foley KT, Smith MM: Microendoscopic discectomy. **Tech Neurosurg** 3:301–307, 1997
4. Gaines RW Jr: The use of pedicle-screw internal fixation for the operative treatment of spinal disorders. **J Bone Joint Surg (Am)** 82:1458–1476, 2000
5. Lowery GL, Kulkarni SS: Posterior percutaneous spine instrumentation. **Eur Spine J** 9:S126–S130, 2000
6. Macnab I: Negative disc exploration. An analysis of the causes of nerve-root involvement in sixty-eight patients. **J Bone Joint Surg (Am)** 53:891–903, 1971
7. Magerl F: External skeletal fixation of the lower thoracic and the lumbar spine, in Uhtoff HK, Stahl E (eds): **Current Concepts of External Fixation of Fractures**. Berlin: Springer-Verlag, 1982, pp 353–366
8. Mathews HH, Long BH: Endoscopy assisted percutaneous anterior interbody fusion with subcutaneous suprafascial internal fixation: evolution, techniques and surgical considerations. **Orthop Int Ed** 3:496–500, 1995
9. Rampersaud YR, Foley KT, Shen AC, et al: Radiation exposure to the spine surgeon during fluoroscopically assisted pedicle screw insertion. **Spine** 25:2637–2645, 2000
10. Schlenzka D, Laine T, Lund T: Computer-assisted spine surgery. **Eur Spine J** 9:S57–S64, 2000
11. Slomczykowski M, Roberto M, Schneeberger P, et al: Radiation dose for pedicle screw insertion. Fluoroscopic versus computer-assisted surgery. **Spine** 24:975–983, 1999
12. Thomsen K, Christensen FB, Eiskjaer SP, et al: 1997 Volvo Award winner in clinical studies. The effect of pedicle screw instrumentation on functional outcome and fusion rates in posterolateral lumbar spinal fusion: a prospective, randomized clinical study. **Spine** 22:2813–2822, 1997
13. Wiesner L, Kothe R, Ruther W: Anatomic evaluation of two different techniques for the percutaneous insertion of pedicle screws in the lumbar spine. **Spine** 24:1599–1603, 1999
14. Yuan HA, Garfin SR, Dickman CA, et al: A historical cohort study of pedicle screw fixation in thoracic, lumbar, and sacral spinal fusions. **Spine** 19:2279S–2296S, 1994
15. Zucherman JF, Zdeblick TA, Bailey SA, et al: Instrumented laparoscopic spinal fusion. Preliminary results. **Spine** 20:2029–2035, 1995

Manuscript received May 7, 2001.

Accepted in final form February 25, 2002.

Address reprint requests to: Kevin T. Foley, M.D., Image-Guided Surgery Research Center, 220 South Claybrook, Suite 700, Memphis, Tennessee 38104. email: kfoley@usit.net.