

Elephas maximus. By Jeheskel Shoshani and John F. Eisenberg

Published 18 June 1982 by The American Society of Mammalogists

***Elephas* Linnaeus, 1758**

- Elephas* Linnaeus, 1758:33. Type species *Elephas maximus* Linnaeus, by original designation.
- Elephantus* Geoffroy Saint-Hilaire and Cuvier, 1795:189 (not Cuvier and Geoffroy Saint-Hilaire). Type species *E. maximus* Linnaeus, by original designation.
- Pilgrimia* Osborn, 1924:2. Type species *Elephas falconeri* Busk, by original designation; fossil.
- Sivalikia* Osborn, 1924:2. Type species *Loxodonta namadica* Falconer and Cautley, by original designation (= *Elephas namadicus*); fossil.
- Palaeoloxodon* Matsumoto, 1924:257. Type species "*E. namadicus naumanni* Makiyama, 1924," by original designation (= *Elephas namadicus*); fossil.
- Leith-Adamsia* Matsumoto, 1927:214. Type species *Leith-Adamsia siwalikiensis* Matsumoto, by original designation (= *Elephas planifrons*); fossil.
- Hesperoloxodon* Osborn, 1931:21. Type species *Elephas antiquus* Falconer and Cautley, by original designation (= *Elephas namadicus*); fossil.
- Platylephas* Osborn, 1942:1358. Type species *Elephas platycephalus* Osborn, by original designation; fossil.
- Hypselephas* Osborn, 1942:1340. Type species *Elephas hysudricus* Falconer and Cautley, by monotypy; fossil.
- Stegoloxodon* Kretzoi, 1950:405. Type species *Stegoloxodon indonesicus* Kretzoi, by original designation (= *Elephas celebensis*); fossil.
- Omoloxodon* Deraniyagala, 1955:25. Type species *Elephas recki* Dietrich, by subsequent designation (Maglio, 1973:34); fossil.

CONTEXT AND CONTENT. Superorder Paenungulata, Order Proboscidea, Suborder Gomphotherioidea, Family Elephantidae, Subfamily Elephantinae. The genus *Elephas* contains ten extinct and one living species (Coppens et al., 1978; Maglio, 1973).

***Elephas maximus* Linnaeus, 1758**

Asian Elephant

- Elephas maximus* Linnaeus, 1758:33. Type locality "Zeylonae," now Sri Lanka.
- Elephas asiaticus* Blumenbach, 1797:124. Type locality "sudlichen Asien, vorzuglich auf Ceilan" (southern Asia, chiefly in Ceylon).
- Elephas indicus* Cuvier, 1798:148-149. Type locality not given.
- Elephas gigas* Perry, 1811:unnumbered page 259 and unnumbered plate 3 (in copy in Rare Book Room at the American Museum of Natural History). Type locality "Africa and Asia" (not a *nomen nudum* because figure and most of the text are based on the Asian elephant).
- Elephas sumatranus* Temminck, 1847:91. Type locality "Sumatra."

CONTEXT AND CONTENT. Context noted in generic summary above. We follow Chasen (1940) and list only three subspecies:

- E. m. indicus* Cuvier, 1798, see above (*gigas* Perry, *isodactylus* Hodgson, *heterodactylus* Hodgson, *bengalensis* de Blainville, *dauntela* Falconer and Cautley, *mukna* Falconer and Cautley, *hirsutus* Lydekker, *dakhunensis*, *asurus*, *rubridens*, *birmanicus*, *borneensis*, and *sondaicus* all of Deraniyagala are synonyms).
- E. m. maximus* Linnaeus, 1758, see above (*asiaticus* Blumenbach, *ceylanicus* de Blainville, *zeylanicus* Lydekker, *vilaliya* and *sinhaleysus* both of Deraniyagala are synonyms).
- E. m. sumatranus* Temminck, 1847, see above.

DIAGNOSIS. *Elephas maximus* has more lamellae and wider upper and lower third molars than extinct species of *Elephas* (Maglio, 1973).

The Asian elephant is smaller than the African elephant (*Loxodonta africana*) and has the highest body point at the head instead of shoulder. The head is compressed anteroposteriorly, and has two dorsal bulges and a concave forehead. The back is convex or level instead of concave. The ears of *E. maximus* are small and in mature individuals the dorsal borders are folded laterally instead of medially. The tip of the trunk has one finger-like process instead of two. There are up to 20 pairs of ribs and 34 caudal vertebrae instead of 21 and 33, respectively; there are usually five nail-like structures on each forefoot and four on each rear foot instead of four and three. Only males generally carry tusks (instead of both sexes); cheekteeth have up to 29 narrow, compressed closed loops or lamellae (instead of up to 15 lozenge-shaped plates per tooth). Skin is smoother than in *L. africana* (Carrington, 1958; Deraniyagala, 1955; Frade, 1955; Laursen and Bekoff, 1978; Sikes, 1971).

GENERAL CHARACTERS. The distinctive trunk is an elongation of nose and upper lip combined; the nostrils are at its tip. The familiar build is shown in Fig. 1. Large bulls weigh 5,400 kg and are 3.20 m at the shoulder. Record height (Pillai, 1941) is 3.43 m. Females reach 2.54 m at the shoulder and weigh 4,160 kg, average weight is 2,720 kg, and average height is 2.24 m. Boyle (1929) found that twice the forefoot circumference gave the shoulder height. The length of the body and head including trunk is 5.5 to 6.5 m; the tail is 1.2 to 1.5 m long (Benedict, 1936). Elephants are smaller in more eastern populations, smallest in Borneo. Skin color is generally gray but becomes lighter in the eastern part of the species range. Elephants from Sri Lanka to Burma display white spots and blotches; those from Malaysia have gray patches and *E. m. sumatranus* has small light spots on ears and trunk (Deraniyagala, 1955).

DISTRIBUTION. Past and present distributions of *E. maximus* are depicted in Fig. 2. Pleistocene fossils are known from Borneo (Hooijer, 1967; Medway, 1977). Distribution is patchy and mostly limited to forest-grassland ecotone (Olivier, 1978b). Estimated wild elephant population is 23,000 to 41,000;




FIGURE 1. An adult solitary bull Asian elephant, *Elephas maximus maximus*, at Yala National Park, Sri Lanka (photo by J. Shoshani).

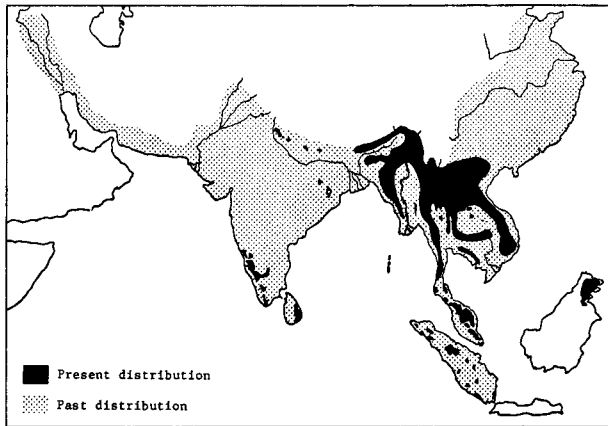


FIGURE 2. Distribution of the Asian elephant, *Elephas maximus*, after Olivier (1978a–1978c); *E. m. maximus* is confined to the island of Sri Lanka, *E. m. sumatranus* to the island of Sumatra, and *E. m. indicus* occupies the rest of the range.

crude densities within the habitat studied fall between 0.12 and 1.0 animals per km² (Eisenberg, 1980).

FOSSIL RECORD. Ten fossil species of *Elephas* were recognized; the earliest is from the middle Pliocene Ekora beds, southeastern Turkana, Kenya, formed about 4.5 million years ago (Maglio, 1973).

FORM. The skin is wrinkled and may be depigmented on the trunk, ears, head, or neck. Albino Asian elephants are regarded as sacred (Macfie, 1927). Hair in adults grows in specific tracts, 21 on the head and 10 elsewhere. Only three tracts are permanent. The longest hair is on the lips, on the elbow and knee joints, and on the end of the tail (Deraniyagala, 1955). Fetal hair pattern was described by Rajagopal and Ayer (1954). Smith (1890) distinguished hairs and bristles: the former are much finer and solid in cross section; the latter are coarse, longer, and perforated by a foramen when viewed under the microscope. Hair of *E. maximus* has a sulfur content of 4.1% and known amino acid composition (Gillespie, 1970).

The epidermis and dermis of the body average 18 mm thick (Smith, 1890). Shoshani et al. (1980) found that skin on the dorsum was 30 mm thick. The approximately hexagonal "epidermal columns" or "studs" are similar to those of *L. africana* (Horstmann, 1966). Smith (1890) noted the absence of glands in the skin; Benedict and Lee (1938) also reported that the skin is generally dry.

The mammae and temporal (musth) glands are the only known integumentary glands. Milk is 83.82% water, 11.82% albuminoids and sugar, 3.89% fat, and 0.47% ash or mineral matter. The specific gravity is 1.038 (Benedict, 1936). Peters et al. (1972) reported that elephant milk contains 1.94 to 3.0% protein, 0.63 to 6.2% fat, 4.0 to 8.36% carbohydrate, and 8.27 to 17.3% solids. The temporal gland is composed of tubular alveolar glands aggregated into lobules. It is located subcutaneously, midway between the eye and the ear on each side of the head. The gland's orifice is about 20 mm long (Fernando et al., 1963).

The skeleton constitutes about 15% of the body weight. The histology of *Elephas* bone was studied by Amprino and Godina (1947) and compared to that of *Mammuthus* by Esra and Cook (1959). The long bones lack large marrow cavities and are filled with spongy bone through which the marrow is disseminated. The epiphyses, particularly on long bones and vertebrae do not firmly fuse until about 25 to 30 years of age. The vertebral formula of *E. maximus* is: C 7, T 19–20, L 3–5, S 3–5, Cd 24–34. According to Temminck (1847), the Sumatran elephant has 20 pairs of ribs, whereas the mainland form has 19 pairs. The first six pairs of ribs contact the sternum, the rest do not. The long bones of each limb almost form a straight line perpendicular to the vertebral column. The scapula when laid on a flat surface, tilts toward the infraspinous fossa, which is about twice as large as the supraspinous fossa. The ilium is almost vertical and expanded laterally. The acetabulum faces downward. The knee joint is at the level of, or below, the body contour. Radius and ulna are separate (may be fused in old individuals) and held permanently crossed in a fixed position of pronation. Tibia and fibula are also separate;

the latter articulates with the calcaneum. Manus is larger than pes; both are short, broad, pentadactyl, and seemingly mesaxonic. The manus is semi-digitigrade, the pes is semi-plantigrade. The carpal bones of the manus are serially arranged. The astragalus is flat and does not articulate with the cuboid. Each foot, including its reduced phalanges, rests on a pad of elastic tissue and is encased in a cylindrical integument. Body weight is supported on these tough, compressible, and shock-absorbent, fibrofatty elastic connective tissues. Os centrale is present on scaphoid of young individuals. Os cordis, baculum, clavicle, astragalus foramen, and humeral entepicondilar foramen are absent. Third femoral trochanter is absent or greatly reduced (Beddard, 1902; Blair, 1710; Deraniyagala, 1955; Flower and Lydekker, 1891; Frade, 1955; Le Gros Clark and Sonntag, 1926; Osborn, 1936, 1942; Shoshani et al., 1980).

Extensive pneumatization occurs in the parietals, nasals, premaxillae, maxillae, and frontals (Fig. 3). Other features of the skull include elevated external nares, wide premaxilla-frontal contact posterior to caudal border of orbit, thickened and laterally extended squamosal portions of mandibular fossa and zygoma, small jugal forming the middle part of the zygomatic arch and extending caudally to participate in the mandibular fossa, and confluent orbit and temporal fossa. The cribriform plate is horizontal. The maxillo-turbinals are rudimentary. A secondary acoustic meatus is formed by enfolding of the squamosal bone. A condylar foramen is absent and the lacrimal foramen is either absent or rudimentary. The internal carotid canal perforates the tympanic bulla. An alisphenoid canal is present. A large infraorbital foramen (sometimes two or more) transmits the maxillary branch of the trigeminal nerve and blood vessels to the proboscis. The mandibular symphysis is spout-like. The high ascending rami terminate in transverse condyles. The coronoid process is compressed and the coronoid canal is present at its base (Beddard, 1902; Osborn, 1936, 1942).

The dental formula of *E. maximus* is identical to that of *L. africana*: i 1/0, c 0/0, dp 3/3, m 3/3, total 26. Deciduous tusks are replaced by permanent second incisors within 6 to 12 months after birth (Deraniyagala, 1955). Permanent tusks are composed of dentine and grow continuously at the rate of about 17 cm per year (Colyer and Miles, 1957). Males grow incisors of two types: a) large tusks which may protrude well beyond the lip, and b) tusks which extend barely beyond the mouth. The two conditions are apparently under genetic control. A smooth conical cap of enamel is present at the tip of the tusk until it wears off early in life. Record tusk length is 3.02 m (Smith, 1930) and record single tusk weight is 39.0 kg (John, 1928). In cross section, a tusk exhibits concentric growth lines, or 'lines of Owen,' as well as a checkered pattern of diamond-shaped areas which become progressively smaller towards the center of the tusk (Fig. 3). This pattern is unique to Proboscidea (Miles and White, 1960).

For practical field work, the cheekteeth are called molars I through VI. The plates of upper teeth diverge towards the chewing surface while the plates of lower teeth converge. The cheekteeth are hypsodont and have multiple roots. The lophodont grinding surfaces are composed of closed enamel loops whose centers are filled with dentine and which are held together by cementum (Fig. 4). The first cheektooth has a maximum of six loops, and the number increases for each successive tooth. The minimum and maximum reported numbers of laminae above and below are: 4–6/4–6, 7–10/7–10, 11–14/12–14, 15–17/14–17, 17–21/17–20, and 20–26/20–29. A sampling of lower cheekteeth weighed (in g): 9.0, 125.0, and 568.0 for the first, second, and third deciduous premolars, and 1,660.0, 3,685.4, and 5,159.6 for the first, second, and third molars (Frade, 1955; Roth and Shoshani, unpubl.).

The cheekteeth, unlike those of most mammals, move anteriorly as well as occlusally as they emerge (Fig. 3). These teeth are the dp2, dp3, dp4, M1, M2, and M3 (dp1 is rarely present). Except for the three deciduous premolars which are present from birth through the first several years, only one tooth or parts of two teeth are functional at one time. As each tooth wears away, a developing tooth from behind replaces it, until the last molar is worn out; the elephant then dies of starvation. The first tooth (dp2) is lost at about year 2, subsequent teeth at years 6, 12, 20 to 25, and at 35 (modified after Bedi, 1969). Supernumerary and deformed tusks and cheekteeth sometimes occur in wild and captive elephants (Colyer, 1936).

The hyoid bone and associated musculature were illustrated by Gasc (1967) and comparison of the stylohoidea among *E. naumanni*, *E. maximus* and *L. africana* was given by Inuzuka et al. (1975).

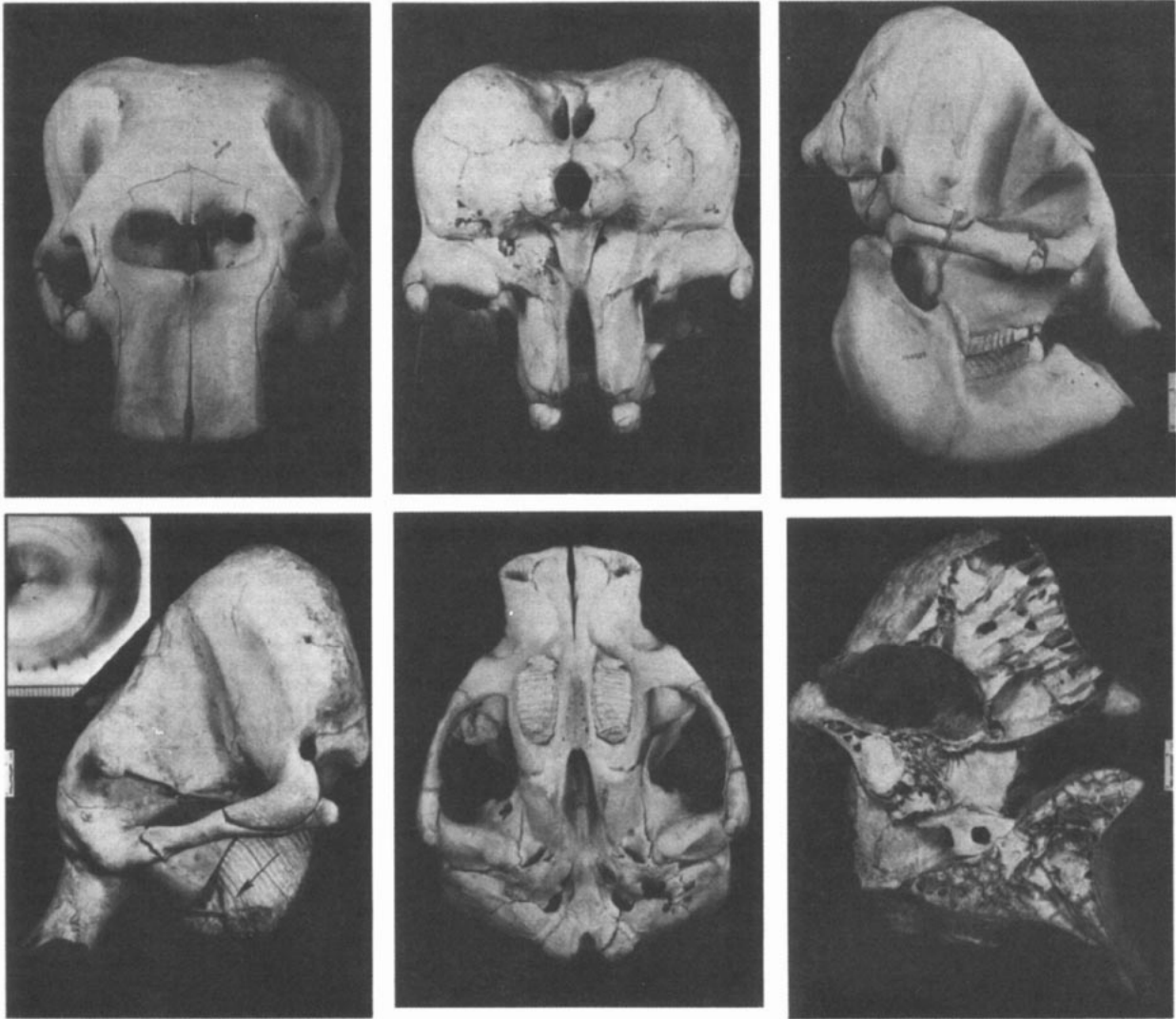


FIGURE 3. Top left, frontal view of cranium of *Elephas maximus sumatranus* (Nat. Mus. Nat. Hist. No. 240939, Washington, D.C.); top middle, posterior view of same skull; top right, side view of same skull; lower left, N.M.N.H. No. 399499 with bone cut away (arrow shows direction of tooth replacement; inset shows cross section of tusk (mm scale) of *Elephas*); lower middle, ventral view of (skull 240939; lower right, skull 399499, cut down middle to show air cells within most bones (skull photos courtesy of Smithsonian Institution); tusk cross section from Bucky Steele, photo by Kathleen Morehead). The scales (white insets) represent approximately 80 mm.

The trunk musculature consists of two major sets: 1) longitudinal and 2) radiating and transverse. The longitudinals are mostly superficial and are further subdivided into anterior, lateral, and posterior. The deeper muscles are best seen as numerous distinct fasciculi in a cross section of the trunk (Harrison, 1847; Miall and Greenwood, 1878; Shindo and Mori, 1955). Lewis (1971) claimed that the trunk contains as many as 60,000 muscles. Harrison (1850a) described a muscle extending from the back part of the bifurcation of the trachea to the forepart of the esophagus. Watson (1872a) and Miall and Greenwood (1878) found no trace of this muscle. Shoshani et al. (1980) found it in one of the three elephants they examined. Le Gros Clark and Sonntag (1926) compared the musculature and other systems among the Tubulidentata, Hyracoidea, Proboscidea, Perissodactyla, and Artiodactyla.

The heart of the Asian elephant, like that of the African species and Sirenia but unlike that of most other mammals, has a bifid apex and paired anterior venae cavae. The tricuspid valve may have one or two small additional cusps. There are two coronary arteries. The heart is connected to the pericardium at its base, and two fibrous cords pass from the dorsum of the pericardium to the tendinous center of the diaphragm (Frade, 1955; Hill, 1938; Miall and Greenwood, 1878; Sikes, 1971; Watson, 1872a). According to Benedict (1936), hearts weigh about 0.5% of total body weight. Miall and Greenwood (1878) stated that a striking peculiarity of the veins lies in the plexuses and free anas-

tomoses which occur in various parts of the body. Valves were found in some but not all plexuses. Distinct and large valves were found by one of us (JS) in the temporal plexuses of one elephant.

The blood clots rapidly. Comparing blood of *E. maximus* to that of *Homo sapiens*, Lewis (1974) found that erythrocytes were large, having a mean diameter of 9.2 microns compared to 7.4 in humans, discoid in shape, but fewer in number than in human blood. There were more leucocytes than in human blood and the platelet count was in the high-normal human range. Nirmalan and Nair (1971) analyzed *E. maximus* plasma in four groups of animals. Proteins made up 82.5 to 92.8 g/100 ml of plasma, the highest reported value for any mammal; globulin content was also the highest among mammals (maximum of 6.68 ± 1.92 g/100 ml plasma), and the albumin/globulin ratio was the lowest (0.33 ± 0.12 to 0.46 ± 0.20). Hemoglobins of both Asian and African elephants have a higher oxygen affinity than normal human hemoglobin (Brown and White, 1980). Dene et al. (1980) demonstrated that the myoglobin of *E. maximus* is unique among mammals. Amino acid sequencing of this protein revealed that position 64 (E7) does not have the distal histidine found in all other mammals studied; instead glutamine occupies this position.

At birth the brain weighs about 35% of the weight of the brain of a fully grown individual. The adult brain has a well-convoluted cerebral hemisphere, resembling that of a porpoise or a man; the hemispheres do not cover the cerebellum, however. The temporal lobes are proportionally very large, bulging out lat-

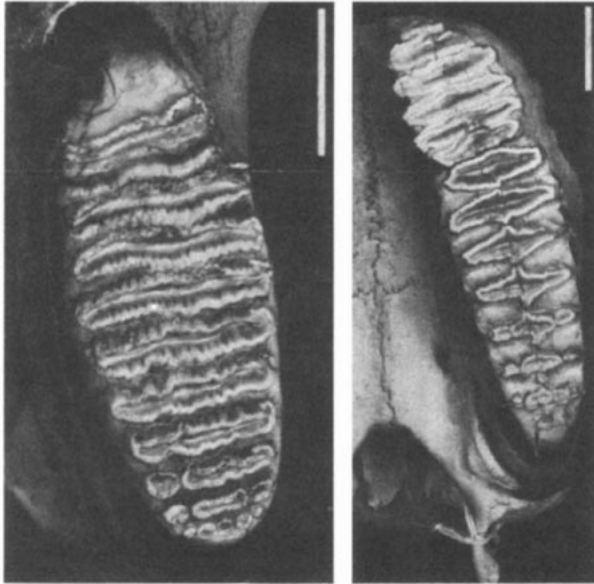


FIGURE 4. Occlusal views of upper molars of *Elephas maximus* (left) and *Loxodonta africana* (right). In both photos, anterior is at top. Scales represent 50 mm (photos courtesy of Smithsonian Institution).

erally. The olfactory lobes are also large. The trigeminal and facial nerves are large. The brain of a 9 to 10-year-old Asian elephant, which weighed 2 tons, weighed 4.5 kg (Beddard, 1902; Evans, 1910; Harrison, 1847; Mayer, 1847; Tennent, 1867). The cranial capacity of an adult *E. maximus* was 6,652 cc (Osborn, 1942).

The epiglottis is thin and flexible. The lungs are simple and slightly lobulated. Their ventral surface is attached to the diaphragm and the lateral surfaces are attached to the pleuro-peritoneum, so there is little space for a pleural cavity (Harrison, 1850a; Miall and Greenwood, 1878; Watson, 1872a). Engle (1963) noted that the acini of the lung were small but extremely numerous, providing an extensive respiratory surface.

The gape of the mouth is relatively small. The cheeks are capable of distention. Two small openings leading to Jacobson's canals are at the anterior end of the hard palate. The soft palate is short and there is no uvula. The tongue is thick and rounded at its base, tapering and pointed in front. The tip is directed downward and lies mostly in the groove formed by the lower lip. Large circumvallate papillae, about two to four or more, are found at the base of the tongue. The salivary glands include the parotid, submaxillary, and sublingual, and a gland that is situated at the internal angle of the mandible. A pharyngeal pouch is present and is supported in part by the hyoid apparatus and the associated musculature. The esophagus enters the stomach near its middle, closer to the cardiac than to the pyloric end. The stomach is simple, not ruminant. Externally, the stomach is smooth, elongated, and nearly straight; the cardiac end is much prolonged and tapering. Internally, a number of transverse, nearly circular folds project inwards from the cardiac wall. These folds almost disappear when the stomach is distended (Miall and Greenwood, 1878; Shimizu et al., 1960).

The duodenum is separate and the jejunum and ileum are composed of numerous loops. The large intestine is shorter (about 12 m) than the small intestine (about 18 m), large in diameter; the loops end in a very short, straight rectum. A number of aggregated glands were found in the rectum, and a special ileo-caecal gland was described. The caecum is large and sacculated. The proximal end of the colon is also sacculated. The inner dorsal wall of the caecum displays a median fold that might indicate an original paired condition. The anus is protected externally by an anal flap at the base of tail (Miall and Greenwood, 1878; Mitchell, 1916). The liver is simple and divided unevenly into two lobes, the left being the smaller. Villaseñor (1964) reported on a new cellular type in the liver. Many workers (e.g., Benedict, 1936; Evans, 1910) have reported on the absence of a gall bladder. Harrison (1847) stated that a gall bladder is rudimentary. Miall and Greenwood (1878) noted that the ductus choleaedocus is sacculated within the duodenum and also receives secretion from

the pancreas. The pancreas, unlike that of most mammals, does not come in contact with the spleen.

The male reproductive system includes intraabdominal testes which are almost globular and located near the kidneys. Four prostate glands, two on each side, are small; each gland opens into the urethra by a single and separate duct. The two Cowper's glands are oval and flattened; they open separately into the urethra. The penis is relatively long, a glans penis is present, and the prepuce is well marked. The orifice of the urethra is Y-shaped; the stem of the "Y" is directed ventrally. The female reproductive system includes a partly bicornuate uterus. A urogenital canal is twice as long as the actual vagina. The clitoris has a prepuce, is long, and reaches beyond the anterior end of the vulval orifice. The glans clitoris is terminal and semi-globular. The vulval orifice extends down between the female's hindlegs, similar to but not as far forward as the position of the penis. This condition has resulted in some incorrect sexing of individuals.

The urinary system includes lobulated kidneys. The urethra empties into the urogenital sinus in females. Discrepancies exist as to the number and distinctness of the lobes of the kidney and of the number of calices and their mode of entry into the ureter. Five seems to be the common number of lobes but two to nine lobes have been reported (Miall and Greenwood, 1878; Watson, 1872b). Endocrine glands include the hypophysis, thyroid, parathyroid, ovary, pancreas, and adrenal (Miall and Greenwood, 1878). The thyroid and parathyroid glands were studied by Fjuita and Kamiya (1963). Kladetzky (1952) described the hypophysis as an elongated, pear-shaped structure attached to the brain by a narrow stalk.

Watson (1874) noted a well-developed periosteal muscle in the eye, corresponding in position to a similar muscle in sheep and deer. The nictitating membrane moves transversely. No true lacrimal apparatus is present (Harrison, 1850b). Miall and Greenwood (1878) found the Harderian gland with its excretory duct opening on the surface of the nictitating membrane.

FUNCTION. The generally thick skin provides protection against bites, bumps, and adverse weather. Its folds increase surface area for heat dissipation. Because of small surface area to mass ratio, elephants, like other large mammals, can tolerate cold better than excessive heat (Benedict, 1936). The color of the skin may be masked by dirt because of dusting and wallowing, which may function in thermoregulation and provide protection against insect bites. The skin is movable and contains many nerve centers (pressure points) used by the mahout or oozie to control trained animals (Deraniyagala, 1955). Although sweat glands are not documented in literature, Carrington (1958) noted that sweat was observed on the back immediately after removal of a saddle. Wild and captive elephants require at least one bath per day. Skin temperature does not depend on ambient temperature (Benedict and Lee, 1938); skin varies from 24.0°C (at 22°C ambient) to 32.9°C (at 26°C ambient). Body temperature is the same as urine temperature and averages 35.9°C. Fecal temperature is 0.7°C higher (Benedict, 1936). The mammary glands provide milk, and may also have a tactile function used in communication between the mother and calves as well as among herd members. Newborn may consume 7.6 to 9.4 l of milk per day. Calves have been raised successfully on diluted milk of domestic cows, on human milk, and on other formulas (Evans, 1910; Ferrier, 1947; Reuther, 1969; Sikes, 1971).

The hindlimbs provide both support and propulsion, and the forelimbs function as supports. Walking gait is about 6.5 km/h, a jog is swift, and a charge may reach over 48.2 km/h (Scott, 1973). The tail protects the anal opening and may be used to drive away biting insects. When in danger, elephants often run holding their tails up, which may signal other herd members of approaching danger. Young elephants follow their mothers or older sisters by holding onto their tails. This behavior has been reinforced in circus and other captive elephants.

The short neck brings the head close to the center of gravity. Independent movements of the head are limited but the elephant can move its eyes considerably. The trunk is a multi-purpose prehensile organ. It is highly sensitive, innervated by the maxillary division of the trigeminal nerve and by the facial nerve. Pinch and grasp methods used by the trunk and laterality were described by Racine (1980). Many functions are attributed to the trunk, including feeding, watering, dusting, smelling, touching, sound production/communication, loading, defense and offense, and washing. The acute sense of smell uses both the trunk and Jacobson's organ. Elephants are crepuscular; eyesight is poor in bright light and probably best during twilight. Hearing is acute. The large pinnae intercept sound waves and aid in thermoregu-

lation. An ability to distinguish low amplitude sounds was demonstrated by Heffner and Heffner (1980). Sikes (1971) suggested that cranial pneumatization somehow improves hearing. The tongue is tactile and aids in bringing food into the mouth. Jaws move mostly backward and forward slight sideways movements are also apparent. Up to 150 kg of food and 140 l of water may be consumed in 1 day (Ishwaran, 1978; McKay, 1973; Vancuylenberg, 1977).

Tusks serve to dig for water, salt, and rocks; to debark trees; as levers for maneuvering fallen trees and branches; for work (in domestic animals); for display; for marking trees; as weapons of defense and offense; as trunk-rests; as protection for the trunk; and perhaps as a status symbol. Elephants are known to be left or right tusked. Ivory has been used in art and in implements for ages. Artists prefer ivory of the African elephant over that of the Asian; they claim it is denser and, therefore, more suitable for carving (Carrington, 1958; Kunz, 1916; Wylie, 1980).

Elephants incessantly move their trunk, ears, and tail. The rest of the body is relatively quiet, except during "weaving" (that is, when standing elephants shift their weight back and forth; Benedict, 1936). Orban and Stohl (1962) concluded that the low creatinine level in the urine is indicative of low metabolism. The total basal metabolism of one Asian elephant ("Jap") at 20°C ambient when lying and without digestive activity, was 49,000 calories/day. Jap weighed 3,672 kg and had a surface area of 23.8 m². Therefore, her basal heat production per kg was 13.3 calories/day, and 2,060 calories m⁻²day⁻¹. A large elephant produces the heat of about 30 men (Benedict, 1936).

The heart beats more slowly than that of man: 28 beats/min when standing and 35 beats/min when lying (Benedict, 1936). Elephants breathe 70% of inhaled air through their trunks. Respiration rates are 4 to 5 breaths/min in lying and calm elephants and 10 or more in standing and awake individuals (Benedict, 1936). Breathing is performed more with the aid of the diaphragm than by expanding the rib cage (Beddard, 1902). The lack of a pleural cavity seems to be an adaptation to the elephant's mode of drinking (Short, 1962).

Only about 44% of the dry matter is digested, as compared with 50 to 70% in cattle, sheep, and horses. The passage of food through the intestine takes 24 h. Chemical composition of feces is much like that of poor hay (Benedict, 1936). Palm leaves (*Caryota urens*) supply more than adequate cobalt for the production of vitamin B₁₂ by microbial synthesis (Ananthasubramanian, 1980).

ONTOGENY AND REPRODUCTION. Data on courtship, mating behavior, natality, growth, and mortality in *E. maximus* in the field are scanty. Copulation is accomplished in the usual posterior position of quadruped animals. Precopulatory behavior involves wrestling with intertwined trunks, neck biting, and attempted mounts. During copulation, the female is passive and intromission is achieved through independent movement of the penis. Intromission lasts less than 8 s and the total duration of the mount is about 30 s. The number of mounts per ejaculation by the males varies between 2 and 4, and the number of intromissions per ejaculation from 1.4 to 3.5 (Eisenberg et al., 1971).

Fertilization takes place in the uterine horn and implantation of the zygote follows. The developing embryo soon becomes enclosed in membranous sacs of maternal and foetal origins composing a non-deciduate and zonary placenta (Cooper et al., 1964; Evans, 1910). The anatomy of the foetus was studied by Hill (1938) and by Deraniyagala (1955).

Gestation usually lasts from 18 to 22 months with a minimum of 17 and a maximum of 24 (Deraniyagala, 1955; Flower, 1943). Pregnancy is not noticeable until nearly the end of gestation. Pillay (1976) diagnosed early pregnancy in elephants, using male frogs and serum of the suspected female elephants. Near the end of gestation, the mammae swell, the nipples distend and curve outwards, and a watery fluid may ooze from them (Anghi, 1962). Maberry (1962) reported that several hours prior to parturition a great deal of thick, rubbery mucus was passed from the vaginal opening. The period of labor may be short or continue for several hours and the act of parturition lasts for a short time (up to 5 min). The afterbirth is usually consumed by the cow.

Birth can occur at any season of the year. Usually one calf is born, rarely twins (Hundley, 1927) or triplets (Macfie, 1916). McKay (1973) estimated that females in favorable habitats had mean intervals between births of 2.5 to 4 years, whereas others had intervals of 5 to 8 years. Newborns weigh about 100 kg (80 to 110 kg) and measure from 75 to 90 cm (Flower, 1943; Hundley, 1934). Calves are extremely hairy compared to adults. The newly born can stand on their feet shortly after birth and can follow the

mother in her daily routines after a few days. The infant, often with maternal help, applies its mouth (not the trunk) to the nipple and may suckle from its mother or from other nursing cows. Young nurse for several months and then begin to eat grass and green foliage. They may nurse occasionally for about 18 months. Parental supervision continues for several years (Crandall, 1964; Deraniyagala, 1955; Evans, 1910).

Sexual maturity usually occurs in males at years 14 to 15 but sometimes as early as year 9. Females usually first give birth in years 15 or 16 (Flower, 1943). Evans (1910) reported a female 9 years 1 month old giving birth, and Crandall (1964) reported an 8-year-old. Male elephants can reproduce at any time, not only when they are in musth. The only indication of estrus is the uttering of low sounds by the female (Benedict, 1936; Evans, 1910). The Asian elephant is polyestrous; the estrus lasts 3 to 4 days in captivity (Asdell, 1964). The interval between estrous periods is 3 weeks, with a mean of 22 days and a range of 18 to 26 days. The mean duration of estrus for 6 females is 4 days but the cow is receptive to mounting only on 1 day (Eisenberg et al., 1971; Jainudeen et al., 1971).

Longevity in elephants has been exaggerated (Sanderson, 1962). Deraniyagala (1955) believed that elephants in the wild may live as long as 120 years, and Dollman (1937) reported on an elephant 170 years old. Alleged and actual ages of elephants in captivity were given by Flower (1948). The oldest documented age of a captive Asian elephant was that of "Jessie," in the Taronga Zoological Park, Sydney, Australia; her estimated age was 69 or 77 years (Flower, 1948; Patten, 1940).

Mortality in Asian elephants can be due to predation on young, disease and parasites, accidents, drought, stress, hunting and poaching, old age, and fighting. Mortality rate was roughly estimated by McKay (1973) for a population in southern Sri Lanka. Given a cohort of 50, mortality may be as high as two to three individuals per year during the first 10 years of life.

ECOLOGY. Formerly Asian elephants used a greater variety of habitats. Now they use the single-monsoon, dry, thornscrub forest in South India and Sri Lanka and effectively forage in suitable habitats in Malaya which would support multistratal, evergreen forests in a climax phase (Olivier, 1978a, 1978b, 1978c). Asian elephants favor an ecotone with an interdigitation of grass, low woody plants, and forests. Continuously forested areas with few clearings do not support high densities of elephants.

Elephants drink at least once a day and are never far from a permanent source of fresh water. Shade is essential during a major part of the day. Elephants radiate heat from their ears; the flapping rate of the ears varies with wind velocity, ambient temperature and cloud cover (McKay, 1973). Elephants require sodium and other trace elements (Hubback, 1939; Morris, 1933). In Sri Lanka where elephant populations occur quite close to the sea coast, use of salt licks is not as prominent as in areas where soils have little sodium (Seidensticker and McNeely, 1975).

Asian elephants may feed at any time, but two major feeding peaks occur each 24 h. Approximately 72 to 90% of an adult's activities involve moving toward food and feeding. Within a feeding bout the rate of feeding is slow until the animal has located a primary source of food (generally grass). Rapid feeding follows and gradually declines (Eisenberg, 1980). An average adult may ingest 7 kg of food in 1 h, feed 18 h/day, and, therefore, eat 150 kg of vegetable matter (wet weight) per day (Vancuylenberg, 1977). An elephant may feed on more than 75 different species of plants, but preferences are shown (Ishwaran, 1978).

Seasonal migratory movements of Asian elephants (Tennent, 1867) have been seriously disturbed by human agriculture (Olivier, 1978a). Seasonal short-range movements of 30 to 40 km still occur in parts of south India and Sri Lanka (Eisenberg and Lockhart, 1972; McKay, 1973). Movements restricted within National Parks may show a cyclic tendency, influenced by wet/dry cycles. Elephants generally do not feed more than a few days at one place. Adult males in Sri Lanka have home ranges of 10 to 17 km². A herd of 23 females and young had a wet season range of 25 km² and a dry season range of 64 km². There is no evidence of territoriality (McKay, 1973). Areas with prolonged drought cycles generally support fewer elephants, but during the wet season temporary aggregations may elevate densities to more than 7/km².

Conservation and management receive much attention as wild elephant populations are dwindling. Captive breeding programs are part of these efforts. Crandall (1964) pointed out some of the problems of managing elephants in captivity, such as difficulties in controlling mature bulls. Reproduction in captivity may be expedited by artificial insemination. Inbreeding should

be avoided as juvenile mortality of inbred young was higher than that of non-inbred young (Ralls et al., 1979). The following references also discuss health and management: Clark et al. (1980), Evans (1910), Ferrier (1947), Kane et al. (1976), Miller (1977), Pinto et al. (1973), Pyakural et al. (1976), Ratnesar (1966), and Schmidt (1978).

BEHAVIOR. Bathing and resting may occupy 12% of an animal's time, moving another 12%, and feeding the rest (Eisenberg, 1980). Younger animals may lie down when sleeping for rather protracted periods whereas adults remain vigilant or lie down only briefly (Kurt, 1960). An adult elephant is virtually immune from predation except by humans. Throughout the later phases of their evolution, humans have had a definite influence on elephant populations. During the Pleistocene, humans began to hunt elephants and mammoths; hunting elephants for food, ivory, and domestication has persisted (Williams, 1950; Wylie, 1980). Young elephants may be killed by tigers and lions; also, Smythies (1940) reported on a full-grown tusker killed by tigers. The protective formation, in which cows place themselves in a semi-circle or closed circle with the infants between them or toward the center, has probably evolved as a response to predation by large predators against their young.

Very few experiments have been conducted to measure memory (see Rensch, 1957). It may take an individual elephant many trials, but once it has mastered a task, it will "remember" that "trick" for a long time (Blond, 1962; Markowitz et al., 1975). A well trained elephant can recognize between 60 and 100 words and phrases (Lewis, 1971). An ability to perform acts that require delicate balance is familiar in captivity but also is observed in nature. Behavior in which an elephant appeared to think was described by Pillai (1941). This elephant on one occasion would not lower a pillar into a pit until a dog sleeping in the pit was roused and driven away.

Rensch and Altevogt (1953) concluded that elephants see well at close range and remember shapes of objects for some time. In subsequent studies involving tone discrimination, Rensch (1957) concluded that elephants have excellent ability to discriminate auditory signals and that their memory is far better than that of horses given similar tests. Their chemical senses, especially olfaction, are highly developed. When feeding, elephants often place themselves so that the oldest female is upwind and thus within detectable range of juveniles and subordinates. During meetings of male and female the temporal gland of the male is actively sniffed by the female and the male checks the female's estrous condition by sniffing at the opening to the urogenital sinus. This and other patterns of social behavior have been described in detail by Eisenberg et al. (1971). McKay (1973) discriminated eight basic sounds used in a variety of contacts. In general, low frequency long-distance calls maintain contact among separate herd members. Close range, high-pitched calls are employed as mood indicators; loud trumpeting indicates alarm. Low snorts indicate changes in the immediate environment, thereby serving as alerting signals.

The growth and development of behavior by young elephants have been recorded in some detail (Hundley, 1934; Reuther, 1969). Growth is relatively rapid from birth to year 6. Females exhibit a marked decrease in growth at years 10 to 12, whereas males slow their growth rate at years 15 to 20 (McKay, 1973). Coordinated use of the trunk develops gradually during the first 6 months of life and so does feeding. By month 6 some feeding on solid food occurs. Frequently the feces of the mother are ingested by the calf and symbiotic bacteria that aid the digestion of cellulose are thereby transferred to the gastro-intestinal tract of the young. Calves may learn what to eat from adults. At about year 4, young males begin independent movements away from the main herd. From years 7 to 8, young males spend less time with the cow herd and either form a subgroup on the periphery or temporarily associate with older bulls. Females tend to remain within the herd of their birth.

A herd or clan is organized along matriarchal lines and the older cow will coordinate movements (McKay, 1973). Herds of cows range in size from 8 to 21 animals (Kurt, 1974). Adult males do not attach themselves to a herd of cows unless it contains a female in estrus. More than one adult male may accompany cows, but generally the dominant bull will mate with the cows (Eisenberg et al., 1971). Younger bulls may frequently engage in "mock fighting." Bulls know the strength of other bulls from former encounters, and strong fights over access to females are extremely rare (McKay, 1973). Males do not attain full size until approximately year 17, and thereafter annual secretions from the tem-

poral gland occur. During secretion, males are more excitable. Jainudeen et al. (1972) demonstrated that the plasma testosterone level is high during the active phase of secretion. We conclude that the period of temporal gland activity is comparable to rut in other ungulates.

GENETICS. Hungerford et al. (1966) and Norberg (1969) reported a diploid chromosome number of 56 for *E. maximus*. No karyotypic difference between the two species of living elephants was found. Venkatasubba Rao and Prasad (1963) reported accessory lobes in neutrophile nuclei and perinuclear sex chromatin (Barr bodies) in the cell nuclei of epithelial cells of a female. No such features were found in a blood sample of a male.

REMARKS. *Elephas* is a Greek name of uncertain origin. The genus was named by Ray (1693; see Osborn, 1942:1308). Osborn (1942) preferred the specific name *E. indicus* instead of *E. maximus* for the Asian elephant. Deraniyagala (1955) recognized 14 subspecies of *E. maximus* but gave distinguishing characters of only 12, 8 living and 4 extinct. The Bornean elephants (*E. m. borneensis*) are believed to be feral descendants of a stock introduced in the 1750's (de Silva, 1968; Olivier, 1978b). Chasen (1940), stated that these elephants resemble the continental form rather than Sumatran elephants. The phylogenetic affinity of Proboscidea to Sirenia, Hyracoidea, and Tubulidentata was considered by Olds and Shoshani (1982).

We acknowledge Robert C. D. Olivier for making his distribution map (Fig. 1) available and to Daryl P. Domning and Charles O. Handley, Jr. for their help with the synonymy. The staff at the libraries of the American Museum of Natural History, Smithsonian Institution, University of Michigan, and Wayne State University were very helpful in obtaining pertinent literature. Typing was done by M. Pamela Bedore and Eileen D. Koglin.

LITERATURE CITED

- Amprino, R., and G. Godina. 1947. La struttura delle ossa nei vertebrati. *Pontif. Acad. Sci. Commentationes*, 11(9):1-464.
- Ananthasubramaniam, C. R. 1980. A note on the nutritional requirements of the Asian elephant (*Elephas maximus indicus*). *Elephant Suppl.*, 1:72-73.
- Anghi, Cs. G. 1962. Breeding Indian elephants, *Elephas maximus*, at the Budapest Zoo. *Internat. Zoo Yearb.*, 4:83-86.
- Asdell, S. A. 1964. Patterns of mammalian reproduction. Cornell University Press, Ithaca, 670 pp.
- Beddard, F. E. 1902. *Mammalia*. Macmillan and Co. Ltd., New York, 605 pp.
- Bedi, R. 1969. *Elephant, lord of the jungle*. National Book Trust, New Delhi, 100 pp.
- Benedict, F. G. 1936. *The physiology of the elephant*. Carnegie Inst. Washington, Washington, D.C., 302 pp.
- Benedict, F. G., and R. C. Lee. 1938. Further observations on the physiology of the elephant. *J. Mamm.*, 19:175-194.
- Blair, P. 1710. *Osteographia elephantina: or, a full and exact description of all the bones of an elephant which dy'd near Dundee, April the 27th, 1706, with their several dimensions, etc.* *Phil. Trans.*, Part I, 27(326):51-116, Part II, 27(327):117-168.
- Blond, G. 1962. *The elephants*. Andre Deutsch, London, 180 pp.
- Blumenbach, J. F. 1797. *Handbuch der Naturgeschichte*. Fifth ed. J. C. Dietrich, Gottingen, 747 pp.
- Boyle, D. 1929. Height in elephants. *J. Bombay Nat. Hist. Soc.*, 33:437.
- Brown, I. R. F., and P. T. White. 1980. Elephant blood haematology and chemistry. *Comp. Biochem. Physiol.*, 65B:1-12.
- Carrington, R. 1958. *Elephants: a short account of their natural history, evolution, and influence on mankind*. Penguin Books Ltd., Harmondsworth, 285 pp.
- Chasen, F. H. 1940. A handlist of Malaysian mammals. *Bull. Raffles Mus.*, 15:1-209.
- Clark, H. W., et al. 1980. Mycoplasma species and arthritis in captive elephants. *J. Zoo Anim. Med.*, 11:3-15.
- Colyer, F. 1936. Variations and diseases of the teeth of animals. John Bale, Sons & Danielsson, Ltd., London, 750 pp.
- Colyer, F., and A. E. W. Miles. 1957. Injury to and rate of growth of an elephant tusk. *J. Mamm.*, 38:243-247.
- Cooper, R. A., R. S. Connell, and S. R. Wellings. 1964. Placenta of the Indian elephant, *Elephas indicus*. *Science*, 146:410-412.

- Coppens, Y., et al. 1978. Proboscidea. Pp. 336-367, in *Evolution of African mammals* (V. J. Maglio and H. B. S. Cooke, eds.). Harvard Univ. Press, Cambridge, 641 pp.
- Crandall, L. S. 1964. The management of wild mammals in captivity. Univ. Chicago Press, Chicago, 769 pp.
- Cuvier, G. 1798. *Tableau elementaire de l'histoire naturelle des animaux*. Baudouin, Paris, 710 pp.
- Dene, H., M. Goodman, and A. E. Romero-Herrera. 1980. The amino acid sequence of elephant (*Elephas maximus*) myoglobin and the phylogeny of Proboscidea. *Proc. Royal Soc. London, B*, 207:111-127.
- Deraniyagala, P. E. P. 1955. Some extinct elephants, their relatives and the two living species. *Ceylon Nat. Mus. Publ.*, 161 pp.
- de Silva, G. S. 1968. Elephants of Sabah. *Sabah Soc. J.*, 3:169-181.
- Dollman, G. 1937. An elephant 170 years old. *J. Bombay Nat. Hist. Soc.*, 39:619.
- Eisenberg, J. F. 1980. Ecology and behavior of the Asian elephant. *Elephant Suppl.*, 1:36-56.
- Eisenberg, J. F., and M. Lockhart. 1972. An ecological reconnaissance of Wilpattu National Park, Ceylon. *Smithsonian Contrib. Zool.*, 101:1-118.
- Eisenberg, J. F., G. M. McKay, and M. R. Jainudeen. 1971. Reproductive behavior of the Asiatic elephant (*Elephas maximus maximus* L.). *Behavior*, 38:193-225.
- Engel, S. 1963. The respiratory tissue of the elephant (*Elephas indicus*). Second communication. *Acta Anat.*, 55:105-111.
- Eşra, H. C., and S. F. Cook. 1959. Histology of mammoth bone. *Science*, 129:465-466.
- Evans, G. H. 1910. Elephants and their diseases. Government Press, Rangoon, 343 pp.
- Fernando, S. D. A., J. B. Jayasinghe, and R. G. Panabokke. 1963. A study of the temporal gland of an Asiatic elephant. *Ceylon Vet. J.*, 11:108-111.
- Ferrier, A. J. 1947. The care and management of elephants in Burma. Williams, Lea & Co., Ltd., London, 188 pp.
- Flower, S. S. 1943. Notes on age at sexual maturity, gestation period and growth of the Indian elephant, *Elephas maximus*. *Proc. Zool. Soc. London, ser. A*, 113:21-26.
- 1948. Further notes on the duration of life in mammals. V. The alleged and actual ages to which elephants live. *Proc. Zool. Soc. London*, 117:680-688.
- Flower, W. H., and R. Lydekker. 1891. An introduction to the study of mammals, living and extinct. Adam and Charles Black, London, 763 pp.
- Frade, F. 1955. Ordre des Proboscidiens. Pp. 715-875, in *Traite de Zoologie* (P.-P. Grasse, ed.). Masson et Cie Editeurs, Paris, 17(1):1-1170.
- Fujita, T., and T. Kamiya. 1963. Zur makroskopischen und mikroskopischen Anatomie der Schilddrüse und Nebenschilddrüse des indischen Elefanten. *Anat. Anzeiger*, 111: 72-78.
- Gasc, J.-P. 1967. Squelette hyobranchial. Pp. 550-583, in *Traite de Zoologie* (P.-P. Grasse, ed.). Masson et Cie Editeurs, Paris, 16(1):1-1162.
- Geoffroy Saint-Hilaire, E., and G. Cuvier. 1795. Memoire sur une nouvelle division des Mammiferes, et sur les principes qui doivent servir de base dans cette sorte de travail, lu a la societe d'Histoire naturelle, le premier floreal de l'an troisieme. *Magazin Encyclopedique, ou J. Sci., Letters, Arts, Ann. I, Tome II, No. VI*:164-190.
- Gillespie, J. M. 1970. Mammoth hair: stability of α -keratin structure and constituent proteins. *Science*, 170:1100-1102.
- Harrison, R. 1847. On the anatomy of the elephant. *Proc. Royal Irish Acad.*, 3(61):385-398.
- 1850a. On the larynx, trachea, and oesophagus of the elephant. *Proc. Royal Irish Acad.*, 4:132-135.
- 1850b. On the anatomy of the lachrymal apparatus of the elephant. *Proc. Royal Irish Acad.*, 4:158-165.
- Heffner, R., and H. Heffner. 1980. Hearing in the elephant (*Elephas maximus*). *Science*, 208:518-520.
- Hill, W. C. O. 1938. Studies on the cardiac anatomy of the elephant: II—the heart and great vessels of a foetal Asiatic elephant. *Ceylon J. Sci. (B)*, 21(1):44-61.
- Hooijer, D. A. 1967. Indo-Australian insular elephants. *Genetica*, 38:143-162.
- Horstmann, E. 1966. Die epidermis des Elefanten. *Z. Zellforsch. Mikrosk. Anat.*, 75:146-159.
- Hubback, T. 1939. Why elephants visit salt-licks. *J. Bombay Nat. Hist. Soc.*, 40:730.
- Hundley, G. 1927. Twin elephant calves. *J. Bombay Nat. Hist. Soc.*, 32:214-215.
- 1934. Statistics of height increments of Indian calf elephants. *Proc. Zool. Soc. London*, 1934:697-698.
- Hungerford, D. A., et al. 1966. Chromosomes of three elephants, two Asian (*Elephas maximus*) and one African (*Loxodonta africana*). *Cytogenetics*, 5(3):243-246.
- Inuzuka, N., et al. 1975. On the stylohyoid bone of Naumann's elephant (*Elephas naumanni*) from Lake Nojiri. *Mem. Fac. Sci., Kyoto Univ., Ser. Geol. Mineral.*, 41:49-65.
- Ishwaran, N. 1978. Ecological studies on the population of elephants in the Gal Oya area in relation to distribution, habitat preferences, competition and food availability. Unpubl. M.S. Thesis, Univ. Sri Lanka, Peradeniya, 262 pp.
- Jainudeen, M. R., J. F. Eisenberg, and N. Tilakeratne. 1971. Oestrous cycle of the Asiatic elephant, *Elephas maximus*, in captivity. *J. Reprod. Fert.*, 27:321-328.
- Jainudeen, M. R., C. B. Katongole, and R. V. Short. 1972. Plasma testosterone levels in relation to musth and sexual activity in the male Asiatic elephant, *Elephas maximus*. *J. Reprod. Fert.*, 29:99-103.
- John, A. W. 1928. A large tusker elephant. *J. Bombay Nat. Hist. Soc.*, 32:596.
- Kane, K. K., R. M. Corwin, and W. J. Boever. 1976. Louse infestation of Asian elephants. *J. Amer. Vet. Med. Assoc.*, 169:906-908.
- Kladetzky, J. 1952. Mitteilung uber die Hypophyse eines weiblichen indischen Elefanten. *Anat. Anzeiger*, 99(4/6):75-79.
- Kretzoi, M. 1950. *Stegoloxodon* nov. gen., a loxodonta elefantok estleges azsiai ose. *Foldtani Kozlony*, 80:405-408.
- Kunz, G. F. 1916. Ivory and elephant in art, in archaeology, and in science. Doubleday, Page and Company, New York, 527 pp.
- Kurt, F. 1960. Le Sommeil des elephants. *Mammalia*, 24:259-272.
- 1974. Remarks on the social structure and ecology of the Ceylon elephant in the Yala National Park. Pp. 618-634, in *The behaviour of ungulates and its relation to management* (V. Geist and F. Walther, eds.). IUCN Publication, new series, 24:1-940.
- Laursen, L., and M. Bekoff. 1978. *Loxodonta africana*. *Mamm. Species*, 92:1-8.
- Le Gros Clark, W. E., and C. F. Sonntag. 1926. A monograph of *Orycteropus afer*—III. The skull. *Proc. Zool. Soc. London*, 30:445-485.
- Lewis, J. H. 1974. Comparative hematology: studies on elephants, *Elephas maximus*. *Comp. Biochem. Physiol.*, 49A:175-181.
- Lewis, M. 1971. Of the kingdom of Abu. Denny's Calgary Digest, Calgary Zool. Soc., 1(7):19-23.
- Linnaeus, C. 1758. *Systema naturae*. . . , Tenth ed. L. Salvii, Stockholm, 1:1-824.
- Maberry, M. B. 1962. Breeding Indian elephants at Portland Zoo. *Internat. Zoo Yearb.*, 4:80-83.
- Macfie, D. F. 1916. A case of triplet in an elephant. *J. Nat. Hist. Soc. Siam*, 1:53.
- 1927. White elephant calf. *J. Bombay Nat. Hist. Soc.*, 32:214.
- Maglio, V. J. 1973. Origin and evolution of the Elephantidae. *Trans. Amer. Phil. Soc.*, 63(3):1-149.
- Markowitz, H., et al. 1975. Do elephants ever forget? *J. Applied Behav. Anal.*, 8(3):333-335.
- Matsumoto, H. 1924. Preliminary note on fossil elephants in Japan. *J. Geol. Soc. Tokyo*, 31(371):255-272.
- 1927. On *Leith-Adamsia siwalikiensis*, a new generic and specific name of archetypal elephants. *Japanese J. Geol. Geogr.*, 5(4):214.
- Mayer, C. 1847. Beitrage zur Anatomie des Elefanten und der ubrigen Pachydermen. *Nova Acta Phys.-Med. Acad. Caes. Leop., Halle*, 22:1-88.
- McKay, G. M. 1973. Behavior and ecology of the Asiatic elephant in southeastern Ceylon. *Smithsonian Contrib. Zool.*, 125:1-113.
- Medway, L. 1977. *Mammals of Borneo*. Malayan Branch, Royal Asiatic Soc., Kuala Lumpur, 172 pp.
- Miall, L. C., and F. Greenwood. 1878. *Anatomy of the Indian elephant*. MacMillan and Co., London, 84 pp.

- Miles, A. E. W., and J. W. White. 1960. Ivory. Proc. Royal Soc. Med., 53:775-780.
- Miller, R. M. 1977. Segmental gangrene and sloughing of elephants' ears after intravenous injection of phenylbutazone. Vet. Med. Small Anim. Clin., 72(4):633-637.
- Mitchell, P. C. 1916. Further observations on the intestinal tract of mammals. Proc. Zool. Soc. London, pp. 183-251.
- Morris, R. C. 1933. Elephants eating earth. J. Bombay Nat. Hist. Soc., 36:496-497.
- Nirmalan, G., and S. G. Nair. 1971. Plasma proteins and certain non-protein nitrogenous constituents in the blood of Indian elephants (*Elephas maximus*). Brit. Vet. J., 127(5):207-213.
- Norberg, H. S. 1969. The chromosomes of the Indian female elephant (*Elephas indicus* syn. *E. maximus* L.). Hereditas, 63:279-281.
- Olds, N., and J. Shoshani. 1982. *Procavia capensis*. Mamm. Species, 171:1-7.
- Olivier, R. C. D. 1978a. On the ecology of the Asian elephant. 2 vols. Unpubl. Ph.D. Thesis, Univ. Cambridge, England, 454 pp.
- 1978b. Present status of the Asian elephant (*Elephas maximus* Linnaeus, 1758). Elephant, 1(2):15-17.
- 1978c. Distribution and status of the Asian elephant. Oryx, 14:379-424.
- Orbanyi, I., and G. Stohl. 1962. Elefant-Urin Untersuchungen. Nord. Vet.-Med., 14 (Suppl. 1):321-328.
- Osborn, H. F. 1924. *Parelephas* in relation to phyla and genera of the family Elephantidae. Amer. Mus. Novitates, 152:1-7.
- 1931. *Palaeoloxodon antiquus italicus* sp. nov., final stage in the 'Elephas antiquus' phylum. Amer. Mus. Novitates, 460:1-24.
- 1936. Proboscidea. Amer. Mus. Press, New York, 1:1-802.
- 1942. Proboscidea. Amer. Mus. Press, New York, 2:805-1675.
- Patten, R. A. 1940. "Jessie" joins her ancestors. Parks and Recreation, 23(5):200-202.
- Perry, G. 1811. Arcana; or the museum of natural history . . . George Smeeton, London, 306 pp.
- Peters, J. M., et al. 1972. Composition and nutrient content of elephant (*Elephas maximus*) milk. J. Mamm., 53:717-724.
- Pillai, N. G. 1941. On the height and age of an elephant. J. Bombay Nat. Hist. Soc., 42:927-928.
- Pillay, K. R. S. 1976. A note on the diagnosis of pregnancy in elephants. Indian Vet. J., 53:19-21.
- Pinto, M. R. M., M. R. Jainudeen, and R. G. Panabokke. 1973. Tuberculosis in a domesticated Asiatic elephant, *Elephas maximus*. Vet. Rec., 93:662-664.
- Pyakural, S., U. Singh, and N. B. Singh. 1976. An outbreak of foot-and-mouth disease in Indian elephants (*Elephas maximus*). Vet. Rec., 99:28-29.
- Racine, R. N. 1980. Behavior associated with feeding in captive African and Asian elephants. Elephant Suppl., 1:57-71.
- Rajagopal, M. D., and A. A. Ayer. 1954. Hairs and hair tracts of two foetuses of the Indian elephant (*Elephas indicus*). Anat. Soc. India, 3(1):1-10.
- Ralls, K., K. Brugger, and J. Ballou. 1979. Inbreeding and juvenile mortality in small populations of ungulates. Science, 206:1101-1103.
- Ratnesar, P. 1966. Can elephants transmit disease to man? J. Trop. Med. Hyg., 69(9):215-216.
- Rensch, B. 1957. The intelligence of elephants. Sci. Amer., 196(2):44-49.
- Rensch, B., and R. Altevogt. 1953. Visuelles Lernvermögen eines Indischen Elefanten. Zeit. Tierpsychol., 10(1):119-134.
- Reuther, R. T. 1969. Growth and diet of young elephants in captivity. Internat. Zoo Yearb., 9:168-178.
- Sanderson, I. T. 1962. The dynasty of Abu: a history and natural history of the elephants and their relatives past and present. Alfred A. Knopf Inc., New York, 376 pp.
- Schmidt, M. 1978. Elephants. Pp. 709-752, in Zoo and wild animal medicine (M. E. Fowler, ed.). W. B. Saunders Co., Philadelphia, 951 pp.
- Scott, J. D. 1973. Four tons of friendship. Internat. Wildl., 3(2):20-25.
- Seidensticker, J., and J. McNeeley. 1975. Observations on the use of natural licks by ungulates in Huai Kha Khaeng Wildlife Sanctuary, Thailand. Bull. Nat. Hist. Soc. Siam, 26:24-34.
- Shimizu, Y., T. Fujita, T. Kamiya, and S. Isokawa. 1960. Anatomy of a female Indian elephant with special reference to its visceral organs. Acta Anat. Nippon, 35(3):261-301.
- Shindo, T., and M. Mori. 1955. Musculature of Indian elephant. Part III. Musculature of the trunk, neck and head. Okajimas Folia Anat. Jap., 29:17-40.
- Short, R. V. 1962. The peculiar lungs of the elephant. New Scientist, 16:570-572.
- Shoshani, J., et al. 1980. An abstract on the dissection of a female Asian elephant (*Elephas maximus maximus* Linnaeus, 1758). Elephant, 1(4):44-46.
- Sikes, S. K. 1971. The natural history of the African elephant. Weidenfeld and Nicolson, London, 397 pp.
- Smith, F. 1890. The histology of the skin of the elephant. J. Anat. Physiol., 24:493-503.
- Smith, H. M. 1930. Large tusks in a Siamese elephant. J. Nat. Hist. Soc. Siam, 8(2):121.
- Smythies, E. A. 1940. A battle royal between tigers and an elephant. J. Bombay Nat. Hist. Soc., 41:654-655.
- Temminck, C. J. 1847. Coup-d'oeil general sur les possessions neerlandaises dans l'Inde archipelagique, Vol. 2. A. Arnz and Comp., Leide, 471 pp.
- Tennent, J. E. 1867. The wild elephant and the method of capturing and taming it in Ceylon. Longmans, Green and Co., London, 198 pp.
- Vancuylenberg, B. W. B. 1977. Feeding behaviour of the Asiatic elephant in south-east Sri Lanka in relation to conservation. Biol. Conserv., 12:33-54.
- Venkatasubba Rao, S. R., and M. R. N. Prasad. 1963. The nuclear sex in the Indian elephant, *Elephas maximus* L. Naturwissenschaften, 50(7):313.
- Villaseñor, C. C. 1964. Un nuevo tipo celular encontrado en el higado del *Elephas maximus*. Gaceta Medica de Mexico, 94(4):403-405.
- Watson, M. 1872a. Contributions to the anatomy of the Indian elephant. Part I., The thoracic viscera. J. Anat. Physiol., 6:82-94, plate VI.
- 1872b. Contributions to the anatomy of the Indian elephant (*Elephas indicus*), Part II. Urinary and generative organs. J. Anat. Physiol., 7:60-74, plate IV.
- 1874. Contributions to the anatomy of the Indian elephant (*Elephas indicus*). Part III. The head. J. Anat. Physiol., 8:85-94.
- Williams, J. H. 1950. Elephant Bill. Rupert Hart-Davis, London, 321 pp.
- Wylie, K. C. 1980. Ivory, elephants, and man: a survey. Elephant Suppl., 1:3-18.

Editors of this account were DANIEL F. WILLIAMS and SYDNEY ANDERSON. Managing editor was TIMOTHY E. LAWLOR.

J. SHOSHANI, DEPARTMENT OF BIOLOGICAL SCIENCES, WAYNE STATE UNIVERSITY, DETROIT, MICHIGAN 48202 AND J. F. EISENBERG, NATIONAL ZOOLOGICAL PARK, WASHINGTON, D.C. 20008.