

# Keratoconus

## A clinical update

**K**eratoconus can be defined as a progressive, non-inflammatory, conical deformity of the cornea. It is characterised by corneal thinning and protrusion, resulting in corneal distortion and decreased vision. In many cases, the patient is first diagnosed in their mid to late teens. The disease then tends to alternate between periods of active change and relative stability. In most cases, it stabilises by the time the patient reaches the age of 40 or 50.

Keratoconus can be classified by the degree of conicity as early or advanced, or it can be classified morphologically by the shape of the cone. In such cases, many clinicians use keratometry readings to help gauge the severity of disease. These K-readings can be derived from the keratometer, corneal topographer (Figure 1) or, rarely, from an autorefractometer:

- Mild <45D in both meridians
- Moderate 45-52D in both meridians
- Advanced >52D in both meridians

Early keratoconus usually manifests as a small island of irregular astigmatism in the inferior paracentral cornea. Advanced keratoconus has been classically subdivided into three categories – nipple, oval and globus:

- **Nipple.** The nipple form of keratoconus is comprised of a small, near-central ectasia 5mm or less in diameter. It is called the nipple form because there is sometimes, but not always, an elevated fibroplastic nodule at the apex of the cone
- **Oval.** The most common shape in advanced keratoconus is oval, which is characterised by displacement of the corneal apex below the midline, resulting in an island of inferior mid-peripheral steepening

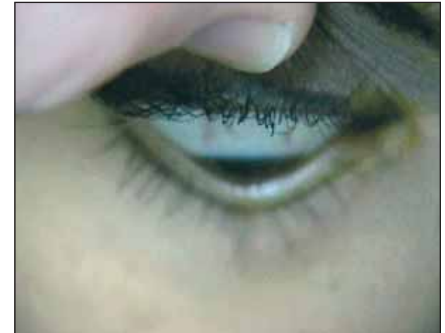- **Globus.** The globus form of keratoconus encompasses nearly three-quarters of the corneal surface and usually has no surrounding island of normal mid-peripheral cornea<sup>1</sup>

In recent years, some practitioners have abandoned the nipple-oval-globus classification due to the widespread use of corneal topographers.

### Signs and symptoms

Patients with keratoconus often complain of decreased vision, photophobia, monocular diplopia, visual distortion, asthenopia and glare around lights. You should suspect keratoconus in any young adult with irregular astigmatism, or in any patient with myopic astigmatism whose spectacle prescription is changing more frequently than normal. Your suspicions should be heightened if such a patient is not correctable to 6/6 in the phoropter with no other pathology to account for the decreased vision.

Slit lamp findings on a patient with keratoconus include Fleischer's ring, Vogt's striae, corneal thinning and Münson's sign (Figure 2). Also seen are increased visibility of corneal nerves, apical thinning, anterior stromal clearing lines, subepithelial fibrillary lines, and central or



» Figure 2  
Münson's sign

eccentric corneal protrusion.

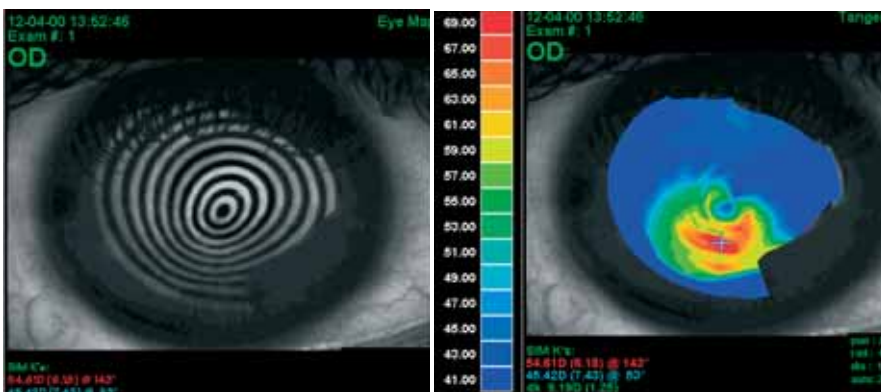
Fleischer's ring is a yellow-brown line, which demarcates the peripheral edge of the cone. Vogt's striae are vertical stress lines near the apex of the cone, appearing as a series of sharp, whitish, vertical or oblique lines just anterior to Descemet's membrane. In some patients, they may be horizontal as well. Slit lamp examination will also demonstrate displacement of the apex of the cornea below a hypothetical line bisecting the pupillary axis. The other common sign is Münson's sign, which is a bulging of the lower lid during downgaze. One additional aspect of slit lamp examination and history taking on patients with keratoconus is to watch for signs of atopic disease. Eye rubbing associated with this condition is common in this patient group and may contribute to progression of the disease. If present, it should be managed with topical anti-allergy medications.

During retinoscopy, the red reflex in a keratoconic eye often demonstrates high amounts of irregular astigmatism with a scissor motion. After dilation, keratoconic patients sometimes demonstrate a dark annular shadow surrounding the bright reflex at the apex of the cone. This shadow is caused by total internal reflection of light brought about by the conical-shaped cornea. In some patients, this can be seen without dilation, and it is almost always diagnostic of keratoconus.

A patient with keratoconus will exhibit several features on keratometry. In many cases, corneal astigmatism is so pronounced that the mires may appear oval. They are usually distorted to some degree by the irregular corneal surface. The central keratometric rings are frequently non-superimposable, suggesting irregular corneal astigmatism – a hallmark of keratoconus<sup>2</sup>. One thing you want to do on keratometry is to document differences between K-readings in primary gaze versus upgaze (which will measure inferior cornea).

» Figure 1

Corneal topography of a patient with keratoconus



On corneal topography, early keratoconus reveals a characteristic pear-shaped elongation of the central mires at the mid-periphery, below the corneal midline. As the condition progresses, the steepening usually spreads nasally to include the inferonasal cornea. Advanced keratoconus can demonstrate rotational steepening above the midline along a superotemporal path. The last area to be affected by keratoconus is usually the superior nasal quadrant of the cornea<sup>1</sup>. However, there is some variability in this presentation. Some practitioners may find that the apex of the cone is decentered below the midline and temporal.

### Treatment options

Treatment of keratoconus depends on the severity of the condition. Early in the disease, spectacles are successful in restoring vision. However, as the disease progresses, the patient will need contact lenses to provide optimal visual acuity. Lens options include soft (hydrogel) lenses, basic rigid gas permeable lenses, and specialty gas permeable lenses.

- **Soft lenses.** Unlike rigid gas permeable lenses, which help mask some of the corneal irregularity of keratoconus, soft lenses tend to drape over the cornea. Hence, soft lenses are used only in the early stages of the disease. In such cases, the lenses are usually toric, and are fitted in the same manner as they would be on a patient with myopic astigmatism. With the advent of made-to-order, high toric, planned replacement lenses and custom-made precision of lenses, many more patients do well with soft lenses.

One criterion to use to determine if soft lenses are acceptable is that they should induce no scarring. Often, soft contact lenses lead to repeated corneal abrasions, which can result in scarring. Another criterion is if the patient is happy with their vision and is able to function properly in their daily activities.

- **RGP lenses.** When soft lenses no longer work, early keratoconic patients may achieve adequate acuity with large diameter RGP lenses or aspheric lens designs. Often, the large diameter is needed to achieve sufficient centration and to obtain a good fit. Since keratoconus patients often wear their contacts all day, it is important to use lenses with high oxygen permeability, which minimise the risk of neovascularisation. The other major concern is wettability. More advanced cases may require a lens designed specifically for keratoconus.

- **Piggyback lenses.** If a keratoconic patient is intolerant to rigid lenses, a rigid lens fitted over a hydrogel lens is sometimes a viable option. This concept is referred to as a 'piggyback' fit and works well for many patients. The patient is initially fitted with a large diameter soft lens with proper centration and movement. Then keratometry readings are

taken of the 'new' corneal surface, and a RGP lens is fitted over the top of the soft lens. Because the patient is wearing two lenses simultaneously, it is even more crucial to make sure both lens materials are highly oxygen permeable. There are a few soft lens designs for keratoconus, but they may have less oxygen transmission. Many practitioners also find that these lenses demonstrate a tight fit.

- **Surgery.** Once all contact lens options have been exhausted, surgery may be needed to obtain adequate vision. The most common surgical option is a penetrating keratoplasty<sup>3</sup>. Another option is Intacs™, which can be implanted to enhance the stability of the cornea and achieve a more stable fit. Although this procedure failed as a refractive surgery option, it has been shown to help or prevent the need for a corneal transplant in many patients with keratoconus.

One relatively experimental procedure, which is available only in Europe and Mexico, is C3-R, which is collagen cross-linking with riboflavin. In many patients, it is combined with Intacs. Basically, it features the instillation of the eyedrops, followed by UV light for 30 minutes. The premise is that it halts the progression of keratoconus by helping the cornea increase in thickness. Although initial studies look promising, it is still very experimental.

To qualify for surgery, patients' vision should be poor enough to interfere with their ability to work or drive. Like cataract surgery, there is no magic number at which the keratoconic patient needs to undergo a corneal transplant. Often the decision to proceed to surgery is based on the patient's perception of his or her vision. One patient may find that they cannot do their job with 6/9 acuity, while another patient may be very satisfied with their 6/18 vision.

If a patient has a very large area of thinning toward the peripheral cornea, if a stable contact lens fit is no longer possible, or if the patient has significant corneal neovascularisation, surgery may be performed earlier than otherwise indicated by visual performance alone.

### Contact lens fits

Three of the more common gas permeable keratoconus fitting sets are the Soper Cone, McGuire and Rose K. What follows is a brief discussion of these sets and a summary of a suggested fitting process.

The principles discussed can be applied to any fitting set. There are a few soft lens designs to manage keratoconus, but they may not all allow enough oxygen to the cornea and lack the clarity of vision provided by RGP lenses. Because keratoconus patients may need a corneal transplant in the future, avoid lenses that might induce corneal neovascularisation because this condition increases susceptibility to graft rejection.

- **Soper Cone.** This is a bicurve contact lens with a fitting approach based on sagittal depth. In this lens design, the vaulting effect of the lens increases as the base curve decreases for a given diameter. This change in the steep central posterior curvature is used to fit the cone. This design is based on the notion of avoiding the apical bearing that will ultimately lead to corneal scarring in keratoconus patients.

The Soper design consists of 10 lenses, designated by the letters A to H. There are three groups for a given diameter/optic zone relationship<sup>4</sup>. A, B, C and D are designed for mild keratoconus or K-readings of less than 48.00D in either corneal meridian. E, F and G are for moderate keratoconus or K-readings of 48.00D to 54.00D in either corneal meridian. H, I and J are for the advanced stage or K-readings of 54.00D or greater<sup>3</sup>.

- **McGuire.** This keratoconic lens system was introduced in 1978 and is a modification of the Soper design<sup>4</sup>. It consists of three diagnostic lens sets, each formulated for the nipple, oval or globus type of keratoconus. The fitting strategy is aimed at achieving a three-point touch predicated upon the size of optic zone in relation to conical size. In this design, the optical zone sizes are varied from 6mm for the nipple cone to 6.5mm for the oval cone and 7mm for the globus. Each lens also incorporates a series of four peripheral curves, which are blended together to create an almost aspheric relationship. The secondary curve of the McGuire system is 0.5mm flatter than the central base curve. The third curve is 1mm flatter than the secondary curve. The fourth and final peripheral curve is 2mm flatter than the tertiary curve<sup>4</sup>.

- **Rose K.** This is a lens design with complex, computer-generated peripheral curves based on data collected by Dr Paul Rose of Hamilton, New Zealand. In order to achieve the ideal edge lift of 0.8mm, the lens incorporates three peripheral systems: standard, flat and steep. It is available in base curves of 4.75-8mm and diameters of 7.9-10.2mm. The design works by decreasing the optic zone diameter as the base curve becomes steeper. Toric curves are available on both the front and back surface, as well as peripherally, but they are rarely needed.

Rose K lenses are traditionally made in the Boston ES material, but they can be made in the Boston EO material, which provides the added benefit of increased oxygen permeability. The Rose K manufacturing process features a unique software program to help cut and blend the multiple curves, which makes replacement lenses easy to reproduce.

The newest version of this lens, the Rose K 2, incorporates a sophisticated parabolic section on the posterior surface to counteract spherical aberration. Spherical aberrations occur because the focal points of light rays far from the

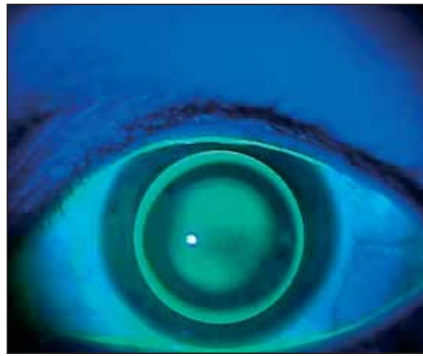
principal axis in a spherical lens are different from the focal points of rays that pass through the centre of the axis. In keratoconus, this is exaggerated further in the steep radius of curvatures. The rays of light passing through the edge of the lens bend more and focus slightly in front of those passing through the centre. The spherical aberration is counteracted by varying amounts of eccentricity across the back optic zone diameter. The fitting regimen for these lenses is the same as for Rose K. It remains to be seen how this lens performs over time, to gauge how much of an improvement it is over the original version.

### Fitting protocol

One of the most important things to do when starting a keratoconus fit is to identify the morphological shape of the cone, and thus determine the stage of the condition. Shape is easily assessed when viewing the cornea with retro-illumination after dilation. The stage of the condition can be assessed by examining K-readings. If the mean K is less than 50.00D, the cone can be considered early stage. A mean K-reading from 50.00D to 55.00D is advanced, and one of greater than 55.00D is severe. Alternatively, one can use simulated K-readings derived from a topographer.

For any new fit, instill a drop of anaesthetic in each eye prior to lens insertion. Otherwise, patients tear excessively, causing the lens to sit low and the eye to yield abnormal fluorescein patterns. Apply the lens and let the patient sit in the waiting room for at least 20 minutes before evaluating the fluorescein pattern. As with all other lenses, look at the central area, the mid-peripheral area and the periphery. Be sure that the lens is located centrally when evaluating it. If the lens lags down, use upward pressure on the lower lid to improve centration when judging fit. If you can demonstrate a good fit, you can often improve centration by increasing lens diameter.

In determining the correct base curve, start with one equivalent to the steeper of the two K-readings. Remember that the mires are often irregular in keratoconus, so the K-reading may provide only a rough gauge of the trial lens. Once the fit of the lens has been assessed (it should be too steep), continue to flatten the base curve until you get the slightest amount of apical touch. If you have a difficult time discerning where the apex of the cone is, then the lens is too steep. The patient is generally most comfortable, and will attain the best acuity, when the weight-bearing forces of the contact lens are distributed evenly on the cornea – the so-called three-point touch (Figure 3). This means that there should be minimal bearing (touch) at the apex of the cone, as well as an area of bearing between the periphery of the lens and the intermediate



» Figure 3

Example of a three-point touch

zone of the cornea. By making sure the ring of touch is incomplete, you permit freshly oxygenated tears to the central cornea when the patient blinks. By making sure the bearing is minimal at the apex of the cone, you will decrease the risk of scarring the cornea.

When selecting an optic zone diameter, measure the pupil in average illumination and add 1mm or 2mm. At the same time, make sure the optic zone fully covers the cone. If the cone is large and eccentric, it may be necessary to utilise a larger optic zone than you would based solely on pupil size but, in most cases, accounting for the pupil will cover both. If you do not fully cover the pupil, your patient will return complaining of decreased vision or glare and halos around lights. This will typically result in an optic zone diameter of roughly 7-8 mm. However, be aware that using one of the proprietary designs often precludes the option of adjusting the optic zone diameter.

The trial lenses for the Rose K fitting set come in an 8.7mm diameter, which works for most patients. When evaluating diameter, the upper edge of the lens should hit the tarsal plate of the upper lid. If it does not, measure from the top of the lens to the bottom of the upper lid, and add that number to the overall lens diameter of the lens.

When doing the over-refraction, start

with 1.00D steps initially, and then refine with 0.50D and 0.25D increments as you get closer to the final prescription. Perform the final over-refraction in normal illumination to approximate normal light conditions and pupil size. If you find you cannot obtain adequate vision with a spherical over-refraction, try a spherocylindrical. If a toric lens is ordered, the lens will be made 0.3mm larger than the diagnostic lens, and then a 0.3mm truncation is employed with 1/4 prism ballast to stabilise the lens. These toric Rose K lenses are not to be confused with bitoric RGPs, which are generally contraindicated in keratoconus.

The criteria for a successful keratoconic lens fit are no different than for a standard fit. The lens needs to be comfortable enough to wear all day long, and the vision and post-wear biomicroscopy needs to be acceptable. The only difference is that acuity for the keratoconic patient may not be 6/6, even with contact lenses, but that is not a problem if the vision is satisfactory for the patient's needs.


All keratoconic patients should return for follow-up at least every six months. Examine corneal surface integrity, evaluate lens fit, and look for changes in corneal topography. Remind them that keratoconus is a progressive disorder, and there is no way to predict when and if it will start to progress again. Also inform them they should schedule an office appointment immediately if they experience decreased vision, photophobia, decreased lens comfort, decreased lens wearing time, increased difficulty inserting or removing the lenses, or any similar symptoms. Such problems may indicate changes in the cornea that should be evaluated as soon as possible.

### Common fitting problems

One of the most common errors in contact lens management of keratoconus is fitting too tight. The CLEK study<sup>6</sup> found that the most common error was fitting excessively flat. Your goal should be to achieve a good stable fit, while allowing for enough movement to provide

» Figure 4

Central bearing and feather touch



adequate tear exchange. Otherwise, poor tear exchange leads to poor oxygen transmission to the cornea. Poor tear exchange also leads to a pooling of metabolic debris underneath the optic zone, which often shows up as dimple veiling and stipple staining around the base of the cone. This problem can be alleviated by decreasing the optic zone diameter, by flattening the existing secondary or peripheral curves, or by blending the junctions between the peripheral curves<sup>5</sup>. Conversely, a lens fitted too flat will move excessively and create discomfort. This can be fixed by steepening the base curve or the peripheral curves, which will decrease lens movement.

If you see coalesced staining of the apex of the cone, it is usually due to one of two reasons – the lens is too flat or there are excessive deposits on the posterior lens surface. Apical staining may ultimately lead to corneal scarring, so this should not be permitted. If the fit is too flat, it should be steepened. If the fit looks stable, have the patient remove the lens and observe the lens alone in the slit lamp<sup>5</sup>. If the deposits are heavy, advise the patient to start a new lens and begin aggressive enzyming and a rigorous daily cleaning schedule. In some cases, it may be necessary for patients to enzyme as often as once or twice a week to keep deposits down.

Sometimes you will see small bubbles under the lens, which indicates a steep fit. This can usually be solved by flattening the base curve until you get the slightest apical touch, increasing the edge lift, or reducing the diameter/optic zone of the lens. If the bubbles persist, the lens can be fenestrated at the juncture of the optic zone and the secondary curve. Fenestration is not something that should routinely be ordered on a lens, but it is a viable last resort.

If the lens is riding too low, centration can be improved by increasing the diameter or steepening the base curve. If you decide to change the diameter, the changes must be at least 0.3mm in most cases to see a clinical difference. If you see superior limbal staining or three and nine o'clock staining, reduce the diameter and/or increase edge lift.

### Conclusion

Although the standard treatment of keratoconus involves contact lens fitting, encourage patients to use spectacles for as long as possible. Particularly in the early stages of keratoconus, there is no need to hurry patients into contact lenses if they are happy with their vision.

A patient who has never worn 'hard' lenses before must be highly motivated to get through the adaptation period of RGPs. The best way to attain this motivation is to keep the patient in

spectacles long enough so that they will notice the greatly improved vision obtained with RGP lenses. If the patient is rushed into RGPs and they fail to notice a dramatic improvement, they may not be so willing to continue.

Before referring a patient for surgery, rethink your fitting strategy or send the patient to a colleague for a fresh approach. The vast majority of patients sent for surgery are denied that procedure and managed optically.

### References

1. Caroline P, Andre M and Norman C (1997) Corneal topography in keratoconus. *Contact Lens Spectrum* 12 (7): 36.
2. Nordan LT (1997) Keratoconus: diagnosis and treatment. *International Ophthalmology Clinics* 37 (11): 51-63.
3. Cannella A (1994) Use of contact lenses in the visual correction of keratoconus. Out of print.
4. Cutler SI (1999) Managing keratoconus with proprietary designs. *Contact Lens Spectrum* 14 (10): 21.
5. Edrington TB, Timothy B (1998) Keratoconus problem solving. *Contact Lens Spectrum* 13 (3): 18.
6. Zadnik K *et al* (1998) Collaborative Longitudinal Evaluation of Keratoconus (CLEK) Study group. Baseline findings in the CLEK study. *Invest. Ophthalmol. Vis. Sci.* 39: 2537-46.

### About the author

Deepak Gupta is the Clinical Director for the Center for Keratoconus at Stamford Ophthalmology, Stamford, USA.