



HEAD-BITING BEHAVIOR IN THEROPOD DINOSAURS: PALEOPATHOLOGICAL EVIDENCE

Darren H. TANKE

Royal Tyrrell Museum of Palaeontology, Box 7500 Drumheller, ALBERTA, T0J 0Y0, CANADA
E-mail: dtanke@dns.magtech.ab.ca

Philip J. CURRIE

Royal Tyrrell Museum of Palaeontology, Box 7500 Drumheller, ALBERTA, T0J 0Y0, CANADA

ABSTRACT: Cranial material of *Sinraptor dongi* (Upper Jurassic, Xinjiang, China), *Gorgosaurus libratus*, *Daspletosaurus torosus* (Upper Cretaceous, Alberta, Canada), and other large theropod dinosaurs exhibit similar paleopathological anomalies indicative of aggressive intra- or interspecific biting. Tooth strike trauma includes osseous lesions caused by solitary or multiple tooth punctures, or by dragging or gouging the tooth tips across the surfaces of cranial elements. Many of these lesions were undergoing active healing at the time of death. One isolated tyrannosaurid dentary bears a broken off and embedded tooth tip of another tyrannosaur. Comparison with unhealed large theropod toothmarks on prey bone suggests that sublethal wounds of these types were caused by other large theropods, possibly rival conspecifics. This may indicate aggressive head or face-biting behavior in certain theropod families. Other associated traumatic osteopathy typified as localized rib and fibula fractures were observed but cannot be directly correlated with violent intra- or interspecific behavior. Healed and healing bite wounds of the head may be related to a number of factors. Establishment of dominance within a pack and territorial behavior are considered as two of the most likely causes. Study of paleopathologies is demonstrated to be a useful tool for understanding dinosaur behavior.

INTRODUCTION

Behavior is among the most difficult aspects of dinosaurian paleobiology to study. While speculative in nature, details can be inferred with varying degrees of confidence. Trackway sites provide information on animal biomechanics (THULBORN, 1989), speed, herding or grouping behavior (CURRIE, 1983; CURRIE & DODSON, 1984; CURRIE, 1998), and possibly migration (CURRIE, 1989). Monospecific or low diversity bonebeds demonstrate social herding (CURRIE & DODSON, 1984) and protection of young. Egg localities reveal communal nesting strategies (HORNER, 1982), and nest protection or incubation (DONG & CURRIE, 1996; NORELL *et al.*, 1995). What of aggressive inter- or intraspecific interactions in dinosaurs? Where can we look to begin to understand dinosaur behaviors such as these? Surprising to some, paleopathology, the multidisciplinary study of ancient disease processes and dento- or osteopathy can also provide direct, compelling insight into some aspects of dinosaur behavior (ROTHSCHILD & TANKE, 1992). Strenuous physical activities can result in injuries to specific re-

gions of the skeleton, which can sometimes be preserved in the fossil record. This is the case for some large theropods, which show the regular occurrence of healed cranial trauma suggestive of biting injuries.

Bone injuries (including those of the cranium) caused by aggressive, biting behavior between conspecifics are not uncommon among taxonomically diverse groups of extinct and extant vertebrates (TABLE I).

Aggressive behavior amongst large theropod conspecifics has been postulated in allosaurids (MOLNAR & FARLOW, 1990) and tyrannosaurids (MOLNAR, 1991). Yet, despite their good fossil record, high number of technical publications, and popularity, there are only casual, passing mentions of possible agonistic-related osteopathy in these families.

Documented postcranial injuries of large theropods consist of healed bone fractures (ribs, gastralia, humeri, fibulae and metatarsals), gout, anomalous hypertrophic bone growths, avulsions,

TABLE I

Selected paleontological and zoological literature of head/face-biting occurrences with dental trauma or cranial osteopathy in extinct and extant vertebrates with known or proposed etiologies.

AGE/GENERA	ETIOLOGY	REFERENCES
<u>Middle Devonian:</u> <i>Dunkleosteus cf. marsaisi</i>	Territoriality, courtship.	CAPASSO <i>et al.</i> , 1996
<u>Triassic:</u> Phytosaurs	Male intraspecific territorial strife; breeding season.	ABEL, 1922
<u>Jurassic:</u> <i>Gephyrosaurus bridensis</i>	Intraspecific fight.	EVANS, 1983
<u>Early Cretaceous:</u> Elasmosaur <i>Woolungasaurus</i>	Predation by pliosaur (no healing).	THULBORN & TURNER, 1995
<u>Late Cretaceous:</u> Mosasaurs	Courtship; territorial fighting.	MONASTERSKY, 1989; ROTHSCHILD & MARTIN, 1993; BELL & MARTIN, 1995
<u>Eocene:</u> <i>Tilemsisuchus lavocati</i>	Intraspecific fight.	BUFFETAUT, 1983
<u>Oligocene:</u> <i>Merycoiodon culbertsoni</i>	Predation and failed predation attempts.	TANKE <i>et al.</i> , 1992; this paper
<i>Archaeotherium wanlessi</i> ; <i>A. scotti</i>	Intraspecific fighting.	SINCLAIR, 1922; EFFINGER, 1998
<u>Miocene:</u> <i>Carcharodon megalodon</i>	Intraspecific fighting; cannibalism.	KELLEY, 1971
<u>Pleistocene:</u> <i>Canis lupus</i> <i>Smilodon fatalis</i>	Intraspecific fight. Stabbing intraspecific bite (no healing).	COURVILLE, 1953 MILLER, 1980; AKERSTEN, 1985; ROTHSCHILD & MARTIN, 1993
<u>Extant Amphibian:</u> <i>Ceratophrys sp.</i>	Fighting for unspecified reasons.	CRAWSHAW, 1989
<u>Extant Reptiles:</u> <i>Varanus niloticus</i> <i>Chalarodon madagascariensis</i> <i>Sphenodon tuatara</i> <i>Paroedura pictus</i>	Ritualistic combat. Territoriality; Males fight. Breeding rights; males fight. Aggressive species, non-territorial fighting.	FAUST & BAYLESS, 1996 BLANC & CARPENTER, 1969 BOARDMAN & SIBLEY, 1991 BRILLET, 1986; Fig. 1
<u>Extant Mammals:</u> <i>Physeter catodon</i>	Breeding rights; intense male fighting behavior.	BERZIN, 1971; CLARKE & PALIZA, 1988
<i>Otaria byronia</i>	Territoriality and mates; males fight during breeding season.	CAMPGNA & LEBOEUF, 1988
<i>Panthera tigris</i> <i>Alouatta seniculus</i>	Breeding rights. Reproductive competition; females fight.	BURTON, 1927 CROCKETT, 1984
<i>Camelus dromedarius</i>	Fighting during rutting season.	GAHLOT <i>et al.</i> , 1989

vertebral fusions, and diffuse idiopathic skeletal hyperostosis or "Dish" (CARPENTER, 1990; LAMBE, 1917; MADSEN, 1976; PETERSEN *et al.*, 1972; ROTHSCHILD & TANKE, 1992; ROTHSCHILD *et al.*, 1997; TANKE & ROTHSCHILD, 1999). While some of these pathologies may be attributed to agonistic clashes, many are likely related to causes such as disease, advanced age, accidents, and courtship or mating trauma (FARLOW *et al.*, 1995; MOLNAR & FARLOW, 1990; NEWMAN, 1970; RUSSELL, 1970; VANCE, 1989). These osteopathies represent the normal, day to day wear and tear injuries experienced by active extinct and extant terrestrial vertebrates.

Large theropod dental trauma is known (FARLOW & BRINKMAN, 1987; FARLOW *et al.*, 1991; JACOBSEN, 1998). Tyrannosaur tooth crowns were often damaged by heavy use during life. Tips can be fractured off (TMP 79.11.158, 90.36.169, 92.36.918, 92.50.172, 96.142.7) or in extreme cases can be broken away at the base (TMP 93.66.17). Tips and the anterior edge of the tooth can be simultaneously broken away (TMP 92.36.459, 94.12.910, 96.12.2), or in rare cases, both flanks of the tooth crown (TMP 96.12.82) can be spalled off. Unbroken teeth can show heavy wear of the anterior denticles, sometimes resulting in their total obliteration. Isolated fragments of chipped teeth are occasionally found (TMP 92.36.459). Damaged crowns often show subsequent heavy wear that reduce them to short, rounded stubs (TMP 92.36.475). Most were probably broken during prey capture, or accidental tooth on bone contacts during feeding (BUFFETAUT & SUTEETHORN, 1989; ERICKSON & OLSON, 1996; ERICKSON *et al.*, 1996; FARLOW & BRINKMAN, 1987; FIORILLO, 1991a, b. An undescribed specimen collected by the Black Hills Institute of Geological Research consists of a malformed double-cusped *Tyrannosaurus* tooth that represents an additional rare dental anomaly (ANONYMOUS, 1991).

Cranial or dental lesions, particularly those resembling unhealed, healing or healed bite marks, require special consideration regarding their etiology and paleobiological significance. These are clearly incurred under unique life circumstances and paleopathology of this novel variety can help elucidate behavioral aspects of these long extinct organisms.

The toothmarking of dinosaur bone and teeth can be categorized into different types (JACOBSEN, 1998), for which the following simplified terminology is used in this paper:

TYPE 1. Punctures (partial and full penetration) are circular to oval in outline. In unhealed examples, plates of bone are folded down and inwards into the puncture hole. The tooth/teeth are pushed into the bone and extracted with no additional damage.

TYPE 2. Transverse gouges, scores or tooth drag imprints are elongate, gently curving lesions with ragged (or healing) margins. This is the most common form of large theropod toothmarking found on bone (the "pull and puncture" variety of ERICKSON & OLSON, 1996), and is also found in bone bitten by extant lions and hyenas (BLUMENSCHINE *et al.*, 1996). Gouges typically penetrate several mm into the cortical bone surface. Bone grain is redirected as the tooth is pulled across the bone (CURRIE & JACOBSEN, 1995). Advanced healing of tooth drag marks can result in a finely perforated, elongate and raised blister-like ridge. Deeper examples of toothmarks of this type can fully penetrate bone. Type 2 lesions can occur singly when only one tooth contacts bone, or in parallel series with regular spacing when more than one tooth contacts bone. In a rare variation, the tooth strikes the bone at a low angle causing a divot of bone to be partially expelled. After the trauma event, the bone divot drops back into the lesion and fuses in place during healing.

TYPE 3. Small-scale parallel groupings of shallow furrows or striations were caused when the serrated edge of the theropod's tooth was dragged across the bone or tooth surface (ABLER, 1992; KELLEY, 1971). Size, shape and spacing of the furrows correlate with species-specific characteristics of the theropod teeth, which often allows one to identify the biting animal (JACOBSEN, 1998).

TYPE 4. Combinations of the above affecting one bone. Types 2 and 3 are found in association most often in prey bone material from Dinosaur Provincial Park [DPP], Alberta.

TYPE 5. Embedded teeth or tooth fragments of the predator (AMES & MOREJOHN, 1980; CURRIE & JACOBSEN, 1995; STAEDTER, 1997) can sometimes be found in recipient bone, and may or may not show signs of healing (MARTIN & ROTHSCHILD, 1989; ROTHSCHILD & MARTIN, 1993).

The published record of cranial trauma or pathology in large theropods is sparse. The type of "*Labrosaurus ferox*" (= *Allosaurus*?, OLSHEVSKY, 1991) is a left dentary (USNM 2315) with an anomalous symphyseal region. The distal end may have been bitten off, causing extensive post-trauma healing and remodelling (GILMORE, 1920) to form a rounded, dorsally pointing hook-like process. Several tooth positions appear to have been lost pre-mortem. A node-like growth of undetermined etiology on a premaxilla of *Allosaurus* was noted by PETERSEN *et al.* (1972). MCGINNIS (1982) noted pathologies affecting *Tyrannosaurus*, including a punctured dentary with partial healing. She suggested this was caused by a bite from a conspecific. MOLNAR & FARLOW (1990) noted the presence of intraspecific-related biting injuries in *Tyrannosaurus* and *Allosaurus*.

MOLNAR (1991) described several *Tyrannosaurus* surangulars showing pathological perforations and suggested one represented a healed tooth puncture. A *Tyrannosaurus* skull (FMNH PR2081) from the Hell Creek Formation of South Dakota shows multiple-event facial trauma affecting the right jugal and angular, and bones from the opposite side of the head (ANONYMOUS, 1991; HARLAN, 1990; LARSON, 1991). It was suggested that intraspecific biting caused the wounds. *Tyrannosaurus* BHI 3033 "Stan" demonstrates similar cranial pathology (NAEYE, 1996). TANKE & CURRIE (1995) noted cranial and dental trauma in large theropods. BRATTSTROM (1974) suggested on the basis of energetics and physiology that long sustained fights between large dinosaurs was probably not possible (but see HOPSON, 1977 for a differing opinion). COOMBS (1990) considered an open-mouthed display of teeth to be within the possible repertoire of large theropod intraspecific behavior.

There are many examples in popular culture of interaction between theropods. Charles Knight's famous 1897 painting of one *Dryptosaurus* vanquishing another was many years ahead of its time (CZERKAS & GLUT, 1982). Knight not only portrayed *Tyrannosaurus* as a dangerous predator, but also as an aggressive intraspecific rival (KNIGHT, 1942). OSBORN (1913) suggested dynamic fighting poses for two rival *Tyrannosaurus*. The 1956 movie *The Animal World* featured a fight to the death between two *Ceratosaurus* disputing over a sauropod carcass (GLUT, 1980). BAKKER (in DANIS, 1973) reconstructed the tyrannosaur *Daspletosaurus* defending its fresh kill from a hungry conspecific. PAUL (in BATTAGLIA, 1979) figured interspecific combat between two *Allosaurus* and one *Ceratosaurus*. STOUT *et al.* (1981) show play fighting and practice hunting behavior in juvenile *Tyrannosaurus*. PAUL (1988) proposed that large theropods occasionally lost their lives during intraspecific fighting, but suggested that the use of teeth in these situations was minimal. He reconstructed several genera using head-butting, or striking out with the taloned feet during fights. BAKKER (in LESSEM, 1988) illustrates vigorous head-to-body butting behavior in *Tyrannosaurus*, and posits actual head-to-head butting (although see MOLNAR & FARLOW, 1990) comparable to that seen in the extant *Ovis canadensis*. SOVAK (in REID, 1990) presented a figure of two large tyrannosaurs fighting, suggesting they might have been fiercely territorial. Finally, LAMBERT (1993) figures intraspecific head-to-body butting behavior in *Carnotaurus sastrei*.

CURRIE (1985) reported and illustrated a semi-circular defect of the left sagittal crest in *Troodon formosus*, and identified the lesion as possibly formed by a cyst. In light of our findings, a well-healed bite-

mark (Type 1 puncture) could also be considered. An undescribed partial skeleton of *Sauromitholestes langstoni* (TMP 88.121.39) has several unhealed toothmarks (Types 2 and 3) affecting the left dentary and its seventh tooth. Spacing of the parallel furrows on a Type 3 lesion confirms the bites were made by a conspecific, but due to their unhealed nature, it cannot be determined whether they represent fatal fighting, predation/cannibalism or scavenging.

SERENO & NOVAS (1993) ascribed healed bite trauma (Type 1 punctures and Type 2 gouging) of the skull in the Upper Triassic *Herrerasaurus ichigualastensis* of Argentina to intraspecific fighting and biting. If true, this would be the oldest documented occurrence of head/face-biting in the Dinosauria. There are occasional references to face-biting wounds in the Upper Jurassic theropod *Allosaurus*, but other than the "*Labrosaurus*" dentary described earlier, we have failed to find conclusive evidence substantiating this claim either in the published record or by examination of material in museum collections. This is surprising, considering the good fossil record for this genus.

Here we describe multiple cranial toothstrike trauma in three large theropod specimens, in all of which the resultant lesions were in the process of healing at the time of death. Two of these animals also show skeletal injuries.

DESCRIPTION

MATERIAL

IVPP 10600, the holotype of *Sinraptor dongi*, is the skeleton of a young adult (CURRIE & ZHAO, 1993) with an estimated total length of 7 m. It has a nearly complete skull and most of the postcranium, and lacks most of forelimbs and tail. It was collected from the Upper Jurassic Shishugou Formation, 25 km northeast of Jiangjunmiao, Junggar Basin, Xinjiang, China. A high-quality RTV rubber molds and casts of the injured and healing areas of the right dentary have been catalogued as TMP 90.300.1.

TMP 91.36.500 is a subadult *Gorgosaurus libratus* with a total length of 5.1 m. It was collected in Quarry 200, Dinosaur Provincial Park (Alberta, Canada) from the Upper Cretaceous (Campanian) Dinosaur Park Formation. This nearly complete articulated skeleton lacks the left forearm, most gastralia and a few pedal phalanges.

TMP 94.143.1 is a subadult *Daspletosaurus torosus* with an estimated total length of 5 m. Collected from Quarry 215, Dinosaur Provincial Park, it is also from the Dinosaur Park Formation. It consists of a nearly complete skull that lacks the left mandible. Most of postcranial skeleton was scattered before burial, and much of this was destroyed by erosion.

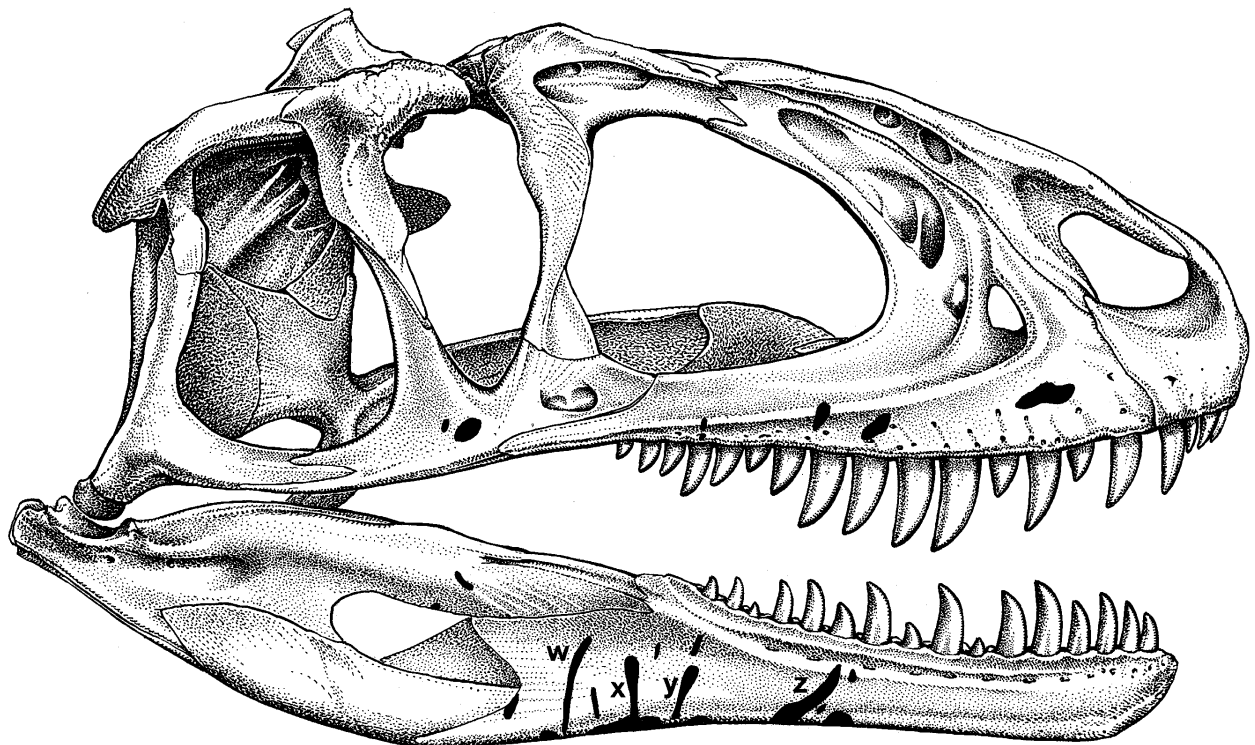
DESCRIPTION OF INJURED SPECIMENS

The skull of *Sinraptor dongi* (IVPP 10600) was partially disarticulated when found. It is well preserved with little post-depositional crushing. Some bones show non-pathological, diagenetic, pock-marked surfaces. Twenty-five partially healed bite wounds can be verified. Three additional poorly defined anomalies might also represent bite trauma, but are too small and featureless for confirmation. Their proximity to numerous better-defined lesions makes their identification as toothstrikes likely. The posterior ventral edge of the left splenial bears a small 4 mm lesion that, due to the combined effects of local bone cracking/displacement and partial bone loss during excavation/preparation, is difficult to interpret. The 28 toothstrike lesions are confined to the right side of the cranium, distributed on the maxilla, jugal, dentary, prearticular, and possibly the surangular (Fig. 1).

The right maxilla bears four toothstrike lesions. The first is situated 52 mm above the second and third teeth, measures 20 mm in length, and is up to 9 mm wide. It is shallow and shows a mildly rugose bone texture suggestive of localized bone infection. The second lesion is found above the seventh tooth, measures 16 X 6.5 mm, and is 3.5 mm deep. It ap-

wound. Normal, smooth bone was found on the floor of the other maxillary lesions. A 19 X 13 mm depression is present on the external side of the jugal near the ventral border. This 3.5 mm deep lesion also appears to represent the healed remnant of a Type 1 puncture. A small patch of slightly raised, rugose textured bone posterior to this lesion might represent another healed puncture wound.

The right surangular bears two small lesions that might also reflect healed toothstrike trauma. The distal end and anteroventral portion of the right dentary was not recovered, resulting in the loss of four anterior tooth positions. This element bore the brunt of the bite, and has fourteen discernable Type 1 and 2 lesions of varying size and depth. Some are arranged in a subparallel series on the external lower half of the bone, and are positioned behind the 10th tooth. Two of the lesions affecting the ventral margin of the dentary are relatively deep, gouging wounds, and one of these is conjoined with lesion "X" (Fig. 1). The other ventral lesion (Z) is positioned under the 12th and 13th alveoli and measures 52.5 mm long, 7 mm wide and up to 4 mm deep. This is the largest toothstrike lesion affecting the skull. All wounds show new, reactive bone growth with fine filigree texture. Ragged edges typical of unhealed tooth-marked bone had been smoothed and rounded by



pears to represent a healed Type 1 tooth puncture healing processes. Slightly raised, rimlike margins

Fig. 1 - Reconstructed skull of *Sinraptor dongi* in right lateral view with distribution of healing pathological toothstrike lesions indicated in black stippling. Preserved wounds of the prearticular and splenial not indicated. See text for discussion of lesions W, X, Y and Z. Modified from an original drawing by Donna Sloan in CURRIE & ZHAO (1993).

encircle some lesions (W, X of Fig. 1-2). One Type 2 elongate lesion fully penetrates the thin bone over a distance of 12 X ~1.5 mm (W of Fig. 1). Two large lesions (X, Y) and several smaller ones parallel lesion W. Each large lesion resembles an inverted, elongate teardrop, with the ventrally-directed point being much shallower in depth than the broader, proximal end (Fig. 2). This morphology closely matches the description of a "puncture and pull" *Tyrannosaurus* toothmark in which the wider end represents the point where the tooth first penetrated the bone (ERICKSON & OLSON, 1996). The size and spacing of lesions W, X and Y suggest they were made by tooth impacts of a similar-sized large theropod.

The prearticular has a slightly raised solitary lesion (14x13x1.5 mm) on the ventral margin, positioned at approximately mid-length. The ventral edge and medial surface of the right splenial bears several small depressed punctures (Type 1) or larger, elongate cuts (Type 2), again showing signs of healing. Some of these have raised regions of mild, reactive bone tissue in and around the wound sites. These wounds were most likely formed by the tooth tips of the aggressor animal as the bite pierced up and under the right jaw. Severity and depth of the splenial lesions probably correlates directly with the varying lengths of the teeth of the aggressor animal.

The distribution of the pathological lesions affecting IVPP 10600 provides a unique opportunity to recreate the attack event. It is unknown whether IVPP 10600 was the aggressor or victim. The positions of the lesions suggest the combatants were facing each other, and their heads were nearly parallel. Given the non-overlapping nature of the tooth-

marks, IVPP 10600 was apparently deeply bitten on the right side of the face and simultaneously on the underside of the lower jaw by the rival, who delivered the bite with the right side of its mouth. Their heads were angled in such a way as to allow the aggressor's right maxillary dentition to cause raking wounds to the right, lateral surfaces of the maxilla and dentary of the victim. The right dentary teeth of the aggressor contacted the ventral right dentary edge and medial side of the right splenial of the victim as they pierced up and inside the soft tissues of the jaw/throat region (Fig. 3). Following the bite, IVPP 10600 was able to retreat and partially heal its injuries.

Some of the ribs from this animal show healing injuries. Four of the left posterior rib heads bear traumatic fracture injuries of the neck or shaft region. Because all of these are from the same side, form a continuous series (numbers 9-12), were each injured in roughly the same place, and are in the same stage of repair, it is likely that all of the rib injuries were received simultaneously. Imperfect healing and mild infectious post-trauma healing is demonstrated by the displacement of some sections, which was followed by callus formation and moderate swelling that may indicate mild osteomyelitis. Ribs 9 and 10 each have relatively smooth, elongate calluses about 4.5 cm long, situated slightly above shaft midlength. Rib 11 was damaged during excavation, preventing determination of the full extent and distribution of pathology affecting this element. Evidently the rib was broken just below the head to form two sections. Subsequent muscle contraction pulled and misaligned the two segments which sub-




Fig. 2 - Stereopair of some of the Type 2 healing toothstrike lesions (W, X, Y) affecting right dentary of IVPP 10600. Dorsal (top), and anterior to the right. Scale = 1 cm.

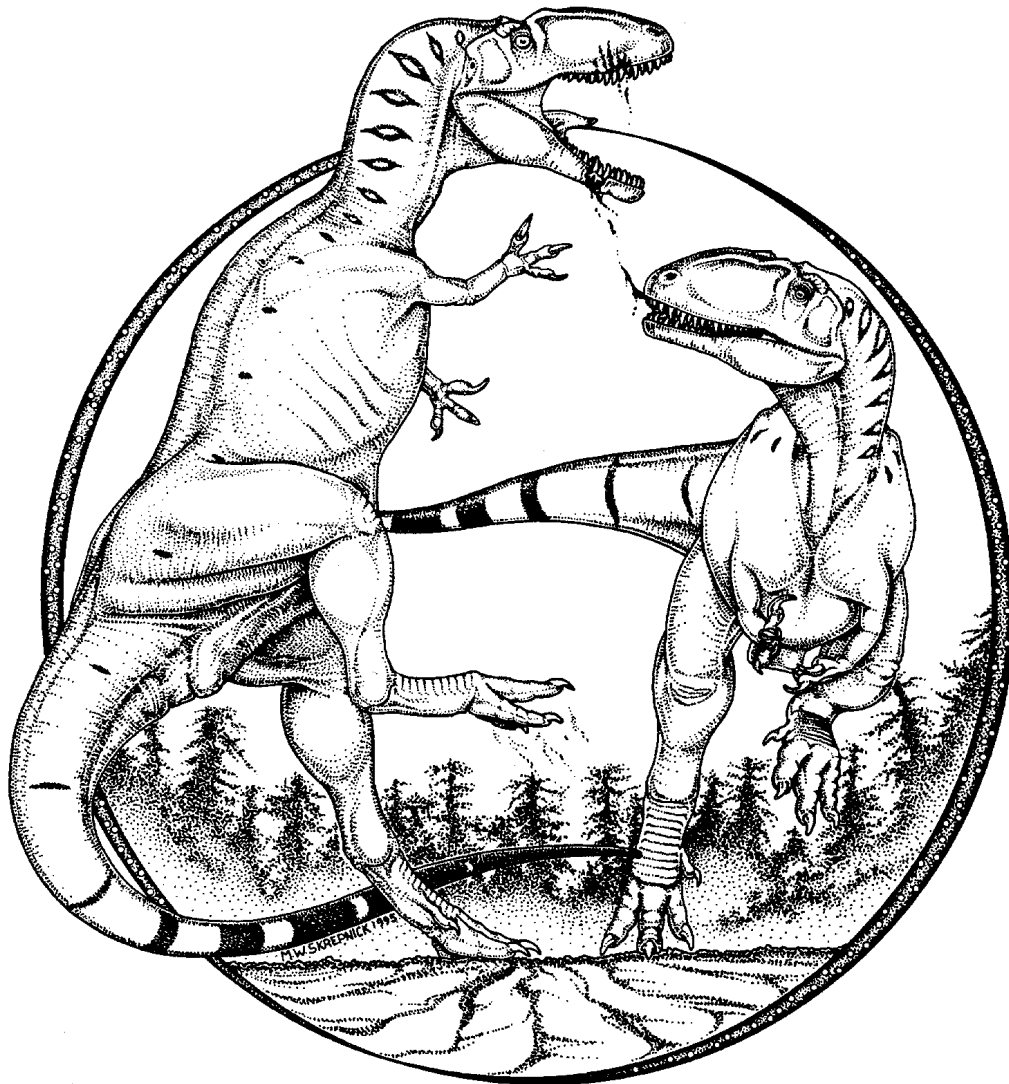


Fig. 3 - Intraspecific fighting in *Sinraptor dongi* as reconstructed from cranial injuries preserved in IVPP 10600.

sequently healed, resulting in moderate angulation with the distal segment externally overlapping the proximal one. The upper portion of this rib has a prominent distal end visible as a protruding rounded off point on the medial surface. The smoothing alteration was related to extensive post-trauma bone repair and resorption. Fracture callus development is moderate and low in relief. Unfortunately, overpreparation has obliterated the callus surface texture, making its exact extent difficult to determine. Rib 12 shows a complete break through the neck. The distal segment was pulled upwards, and is overlapped by the upper segment for a distance of approximately 4.9 cm. Repair consists of smooth gap-filling callus, and prominent, lightly rugose-textured callus. The injury site appears to have been severely swollen, suggestive of chronic osteomyelitis. However, this is largely due to the excess amount of reparative bone

deposited in the gap between the two injured rib segments. The vertebrae to which the injured ribs were articulated show no pathological conditions.

Because of their lateral positions and elongate, gracile morphology, broken and healing or healed ribs are frequently found in the fossil record (ROTHSCHILD & TANKE, 1992; TANKE & ROTH-SCHILD, 1997, 1999). This is also true of extant animals, particularly those with active lifestyles. The presence of multiple rib injuries in IVPP 10600 therefore holds no special significance, and no behavioral implications can be derived from them. In all likelihood, the ribs were broken as a result of a bad fall (ALEXANDER, 1996; FARLOW *et al.*, 1995). The rib injuries appear to be in a more advanced state of repair than the skull injuries, suggesting that they occurred at an earlier time.

The skull and skeleton of TMP 91.36.500 (*Gorgosaurus libratus*) were found in near perfect articulation with minimal post-depositional crushing. The skull is slightly crushed laterally and the jaws gape widely at about a 45° angle. There are several pathologies, some similar to IVPP 10600.

The sixth right maxillary tooth was broken off close to its base and was lost premortem. A short stump of exposed dentine has been worn smooth. Centrally located on the external surface of the right maxilla, 4 cm above the tooth stump, a small circular "punched-out" lesion can be seen. This is similar to the Type 1 puncture lesions affecting the *Sinraptor* skull. The bone texture of this lesion differs from that of the surrounding bone in being chalky in appearance, suggesting restructuring of the normally hard bone surface. Rounded, depressed lesions of this type on isolated maxillae or dentaries are most commonly interpreted as resorption pitting, differential preservation, or fungal infections, but could also represent trauma-related injuries. Additional evidence of injury from adjacent bones is usually necessary to demonstrate a pattern. The lesion in TMP 91.36.500 also exhibits a marked color difference. The skull is dark brown in color, but the lesion and the immediate surrounding area are pale yellow. Without this color variance the maxillary lesion would be difficult to see. A solitary, elongate Type 2 toothmark lesion on the right dentary and its surrounding halo of yellow-colored bone support the idea that the puncture represents a tooth strike. However, a similar, but previously undescribed effect is observed in several turtle families, especially the Baenidae, where this phenomenon is quite common in specimens from Dinosaur Park. Virtually every baenid shell shows pathological scars. In Tertiary and extant chelonians, microbial activities or parasites burrowing under the horny epidermis with resultant bone irritation have been suggested (HUTCHINSON & FRYE, 1989) as the source of the lesions. Like TMP 91.36.500, the pathologic shell lesions of Dinosaur Park baenid turtles can fossilize with a noticeable color difference (brown vs. pale yellow). This is emphasized in some sun-bleached specimens where the normal bone fades to tan or grey, and the lesions become bright white. These previously unreported coloration variations possibly reflect differences in bone microstructure between pathologic and normal bone, which led to differences in mineralization during fossilization. A similar effect surrounding a small, circular pathological defect of unknown etiology was observed depressed into the dorsal surface of a cf. *Stegoceras* skullcap (TMP 97.99.3) collected from the Late Cretaceous Foremost Formation of Chin Coulee, Alberta. The identification of the marks in TMP 91.36.500 is further complicated in that not all tyrannosaur specimens show this coloration variance. In some specimens, all lesions are yellowish,

while in others the lesions have the same brown coloration as the surrounding bone. Some cases even show brown and yellow coloration of different lesions affecting the same element. Without detailed discussion, SAWYER & ERICKSON (1998: 11, 14, fig. 8a) note and illustrate osteopathy with color variation affecting the humerus of the Late Paleocene crocodile *Leidyosuchus formidabilis*. Here the normal bone was of a darker shade than that of the lesion. Further study is required of these unusual preservational and taphonomic processes.

The right dentary has a single elongate Type 2 lesion (approximately 5 mm in length) positioned under the eleventh tooth. The bone also exhibits disruptive external surface bone texture below and between the seventh and ninth teeth, and a disruption in the size and alignment of the curving row of foramina. Normally, the elongate fibres forming the surface bone grain texture are aligned with the longitudinal axis of the jaw. Here these are deflected dorsally and ventrally on both flanks of the injury site. Together, these anomalies suggest a massive but well-healed trauma event, possibly a unilateral jaw fracture. The injury happened well before death, and lengthy bone repair masked the wound site to the point that now it is barely visible. When the mouth is closed, the broken sixth maxillary tooth and the possible right dentary fracture site are almost aligned. Also, the occluding eighth right dentary tooth (at the postulated jaw fracture site) is a still-emerging replacement tooth. The possible jaw fracture along with the broken teeth may represent one event in which the jaw was fractured and the occluding teeth were broken and lost. CT scanning of the area proved inconclusive, presumably because of the advanced nature of the healing.

Postcranial pathology can be seen in several bones of TMP 91.36.500. The shaft of the right humerus appears somewhat swollen and the surface of the bone has an unusual texture. A well-healed fracture is suggested by this, but radiological or CT images are required for confirmation. The right fibula has a fracture at mid-length with good alignment, and was in the process of healing at the time of death. A spur-like exostosis protrudes posteriorly from the uninfected fracture callus, hooks slightly medially, and contacts the tibia (where it caused a subperiosteal irritation). This resulted in a moderate tibial osteopathy manifested as a subcircular rugosity. A distally pointing mushroom-like growth affects right pedal phalanx II-2, proximal to the lateral ligament pit. This lesion appears to represent a ligament avulsion. Nearby, the ungual (phalanx 4) of digit III was found positioned dorsad to its penultimate phalanx. Ungual orientation is correct, but about half of the proximal length is now positioned above the phalanx. This anomalous positioning may represent a

dislocation. Soon after death, this pes was buried. All bones from this side of the body and many from the opposite side were found in perfect articulation, which make the dislocation hypothesis seem plausible. We cannot envision how else the ungual could have changed position. Pseudoarthrosis of a distal caudal neural spine with no associated osteopathy may represent a congenital defect. All injuries were restricted to the right side of the body, the significance of which cannot be determined.

TMP 94.143.1 (*Daspletosaurus torosus*) includes most of a partially disarticulated skull, which is in a splendid state of preservation. While preparation of this skull is still in progress, at least 50 dental and osseous lesions or abnormalities have already been documented. These include three tooth crown fractures, split carinae (ERICKSON, 1995) affecting six teeth, a wide assortment of tooth punctures and gouges largely on the back of the head and snout regions, and indications of mild osteomyelitis. One serious Type 1 puncture lesion affects the bridge of the nose. Evidently the tooth of another large theropod, possibly a conspecific, split and unfolded the dorsal and lateral margins of right premaxilla near the nasal/premaxilla suture. TMP 94.143.1 is unique in showing evidence of well healed and healing cranial wounds, indicating that several attack events occurred over an extended period of time. A more detailed description of this interesting specimen is in preparation. The postcranial skeleton is incomplete, but no osteopathy was observed during its preparation.

Inspection of other tyrannosaurid cranial elements disclosed additional specimens bearing healing injuries from the teeth of other tyrannosaurids. A more detailed study is in progress, but a few of these will be noted here. TMP 85.62.1, a large *Daspletosaurus* from Dinosaur Provincial Park, includes much of the skeleton and skull, but lacks the snout. The partially prepared skull shows extensive Type 1 partially penetrating punctures and Type 2 gouges affecting the lower half of the right jugal along its entire length. TMP 96.5.13 is the symphyseal region of a fragmentary left dentary of an unidentified Dinosaur Provincial Park tyrannosaur. Below the fourth alveolus near the ventral border, the 6 mm long tip of a tyrannosaurid non-premaxillary tooth was found embedded in the bone. The tooth entered the bone at nearly a 90 degree angle in relation to the dorsoventral axis of the dentary and broke off flush with the bone surface. No signs of healing are evident. This Type 5 lesion is extremely rare; it is the only known example of a tyrannosaur tooth embedded in bone recovered from Dinosaur Provincial Park.

Several other adult tyrannosaurid dentaries and jaw fragments (TMP 67.9.164, 86.49.29, 81.27.87, 93.26.188) show multiple Type 2 gouging lesions

with signs of healing. An adult *Tarbosaurus bataar* skull (PIN 551-1) has healing toothstrike trauma on the external, ventral surface of the right jugal.

The left dentary of IVPP 84019 (*Monolophosaurus jiangi*, ZHAO & CURRIE, 1993) has a series of nine poorly defined, elongate and raised blister-like lesions. The parallel dorsoventral orientation of several of the lesions, like those in the *Sinraptor* skull, are suggestive of healed bite trauma. Face-bite lesions have also been found on the maxilla and nasals of an Early Cretaceous *Carcharodontosaurus saharicus* skull (SGM-Din 1) from Morocco (ANONYMOUS, 1996; H. Larsson, pers. comm., 1997).

Other evidence for interactions between large theropods may be found in isolated tyrannosaur teeth gouged or toothmarked by other tyrannosaur teeth (our Type 3 toothmark lesion). These were first described and figured in large theropods by ABLER (1992), who suggested such occurrences were inflicted by one animal biting another during feeding, fighting, or courtship. These markings consist of fine, parallel furrows or striae formed when the finely serrated edges of one tooth were dragged across the tooth enamel of another. The injuries form short straight lines of parallel striations, or gently meandering elongate striae groups related to the movement(s) of the animal(s) involved at the time of biting. The fresh appearance (suggesting immediate post-trauma loss), distribution and orientation of these marks in some specimens are inconsistent with that expected of an opposing or occluding tooth (SCHOWALTER, 1995). Production of the marks may have been made by the colliding teeth of two interacting individuals. Similar striated tooth markings have been preserved in shark species having serrated teeth. Here, head-to-head intraspecific biting is believed to cause these lesions (CIGALA-FULGOSI, 1990; DEMERE & CERUTTI, 1982; KELLEY, 1971; SCHWIMMER & WILLIAMS, 1991). One broken tooth (TMP 93.109.47) shows a toothmark in the form of parallel striae positioned on the exposed dentine face across the tooth's entire base.

For some large theropod examples, the teeth could also have been shed into a carcass during feeding and subsequently bitten by the same or other animals. Presumably these loose teeth would have usually been lost among the mass of meat being ingested. If so, they should show chemical etching from digestive acids (ARGAST *et al.*, 1987), but the samples before us do not indicate this has occurred. Therefore, it is postulated that the toothmarked tyrannosaur teeth represent a byproduct of intraspecific facial biting.

DISCUSSION

Elongate, ragged-edged, gently curving gouges, and simple punctures typical of large theropod and small theropod toothmarking on prey bone (FIORILLO 1991a, b; JACOBSEN, 1998) are documented in our sample. The possible face-bite wounds differ significantly in not having rough, unhealed margins, but demonstrate varying degrees of healing. The rough edges of toothstrike wounds have been rounded over by subsequent osseous tissue development. The floor of the lesions and surrounding areas exhibit a mosaic of features indicating mild necrosis, osteomyelitis of varying severity, bone scarring and partial osseous healing. In some cases thinner bone has been fully punctured, and the resultant holes show healing margins. These specimens document survival after being bitten. Despite the seriousness of deep penetrating bite wounds, the unfortunate individuals escaped their tormentors and survived long enough to repair some of the damage incurred.

POSSIBLE REASONS FOR FACE-BITING

Postulated head or face-biting behavior among conspecifics is not uncommon in the fossil record (TABLE I). Upper Cretaceous marine mosasaurs fre-

quently show this, and half of nearly 50 specimens bear evidence of facial trauma (BELL & MARTIN, 1995; MONASTERSKY 1989; ROTHSCHILD & MARTIN, 1993).

Large theropods are often compared with crocodylians (FARLOW, 1976). Severe cranial and bodily injuries have been recorded in extant and fossil members of this group (Fig. 4; BRAZAITIS, 1981; BUFFETAUT, 1983; COTT, 1961; ERICKSON, 1996; GILMORE, 1946; SAWYER & ERICKSON, 1985, 1998; WEBB & MANOLIS, 1989; WEBB & MESSEL, 1977). These include trauma related to intraspecific interactions, sometimes affecting the skull and lower jaws, and often with serious but non-fatal consequences. Large theropods were better equipped than crocodylians to deliver deep, slashing bites. It would be interesting to see if primitive crocodylomorphs, rauisuchids, and other archosaurs with theropod-like skulls and teeth had similar marks (deep, slashing bites).

There are many reasons why theropods may have fought with each other during the establishment of territories or dominance within social groups, during predation or cannibalism, or as part of mating rituals or play.

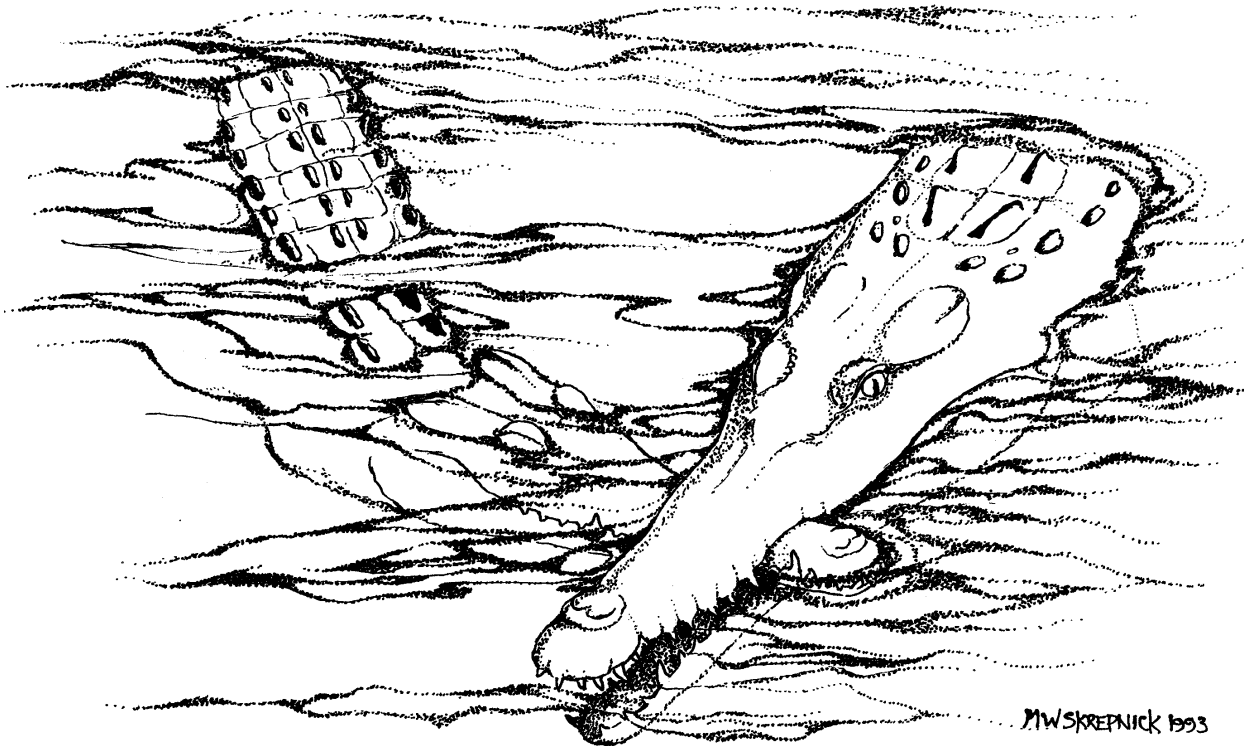


Fig. 4 - Intraspecific fighting in two unidentified conspecific crocodylians; Arnhem Land, Northern Australia. One bites and clamps the others jaws shut. The animal on the right succeeded in drowning the other by holding its head underwater. Redrawn from (BASCHET, 1982: 109).

Territoriality

Large theropods are generally credited as being social animals (CURRIE, 1998). It is possible that, like social mammalian carnivores, some large theropods established and actively defended territories at certain times of the year in order to procure food, acquire/retain mates, establish nesting sites, and protect juveniles, family or hunting units. Such territories may have been vigorously defended against other large theropods, or intruding subadult conspecifics trying to establish territories of their own. A repertoire of head/body displays, vocalizations and, ultimately, fighting and vigorous biting could have been utilized to coerce an invader to leave.

Courtship/Mating

A wide variety of extant vertebrates bite the head, neck or body of the opposite sex during copulation. Typically the male bites and holds the female by the nose, head or nape of the neck. Soft tissue injuries and even death of the female can occur (FOOTT, 1970; LE BOUEF & MESNICK, 1990; MESTEL, 1994; STAEDLER & RIEDMAN, 1993). Aggressive courtship or mating behavior could have led to cranial injuries. However, the half-grown tyrannosaurids discussed here were probably sexually immature. In extant reptiles, animals usually reach 70-75% of average adult body size before reproductive capabilities are attained (D. Bethel, Reptile World, Drumheller, pers. comm., 1997). The case for courtship or mating trauma as the cause of the cranial injuries is a weak one.

Play

Conspecific interactive play is an important component in the early development of juvenile extant mammalian carnivores. Engaging in this activity encourages development of important social and hunting skills necessary during adulthood. Play hunting activities include biting littermates. BYERS (1987) described accidental, self-induced and injurious play behavior in captive *Capra* and questioned whether dinosaurs could have also played. Vigorous, rough and tumble play is not typical behavior in adult-sized, free-ranging animals today. *Sinraptor* and some of the tyrannosaurids examined were close to adult size, and probably no longer indulged in play. Also, play biting in extant vertebrates usually involves simple mouthing or gentle nipping of the opponent without strong jaw clamping. It does not include deep, penetrating bites causing bone injuries like those seen here.

Predation/Cannibalism

Failed attempts at interspecies predation or cannibalism could also explain the presence of healed facial trauma. POLIS (1981) provides a good review

and discussion of intraspecific predation. TRACY (1976) and NAEYE (1996) suggested tyrannosaurs may have been cannibalistic. In the Dinosaur Provincial Park fauna, three tyrannosaurid genera are recognized (*Aublysodon*, *Daspletosaurus*, *Gorgosaurus*), and intergeneric antagonistic interactions may have been regular occurrences. Perhaps during lean times, the carnivores turned cannibalistic. However, the case for active intra- or interspecific predation among tyrannosaurs and other large theropods is not established. TMP 91.36.500 remained largely articulated, with only the gastralium, left forelimb and left pes being disarticulated due to postmortem decay and fluvial transport. IVPP 10600 also shows no signs of predation. If these animals were killed by conspecifics or large theropods of other taxa, they were not eaten. This evidence, however, does not exclude potential cannibalistic behavior in tyrannosaurids. They did occasionally feed upon each other, as evidenced by rare examples of tyrannosaur bones bearing tyrannosaur toothmarks (JACOBSEN, 1998). One of these, a large tyrannosaur III-1 pedal phalanx (TMP 84.82.1) collected from the Horseshoe Canyon Formation near Scollard, Alberta, bears a prominent elongate Type 2 toothmark. Whether this animal was killed and eaten by a conspecific, or was just scavenged as a carcass is unknown. Lack of healing shows the animal was dead when (or soon after) the bite was made. In TMP 94.143.1 (*Daspletosaurus*), the left side of the face (posterior maxilla region) was broken away from an otherwise articulated anterior skull section and a series of four short, unhealed parallel Type 2 gouges were observed on medial surface of the lingual shelf of the right dentary beneath the 14th to 17th tooth positions. Various lines of evidence disclosed that this specimen was in an advanced state of decay and truly scavenged, probably by another tyrannosaurid. In another example, NAISH (1998) reported that a large tibia of an unidentified Lower Cretaceous theropod has five unhealed toothmarks. Here again, active predation, cannibalism or scavenging activities cannot be established with confidence.

Tyrannosaur toothmarks on ornithischian dinosaur prey bones are not uncommon (RYAN *et al.*, 1995; JACOBSEN, 1998), but unhealed tyrannosaur toothmarks on tyrannosaurid bones are rare (JACOBSEN, 1998). We have not yet observed unhealed tyrannosaur bite marks on conspecific cranial elements. In extant carnivores, if the predator is able to catch its prey (and deliver serious bites to the head), it is rare the prey animal will escape and survive. Prey animals with healed cranial bite wounds are rare but known (TANKE *et al.*, 1992; Fig. 5). The high frequency of healed cranial lesions in large theropods, and the rarity of large theropod bones bearing

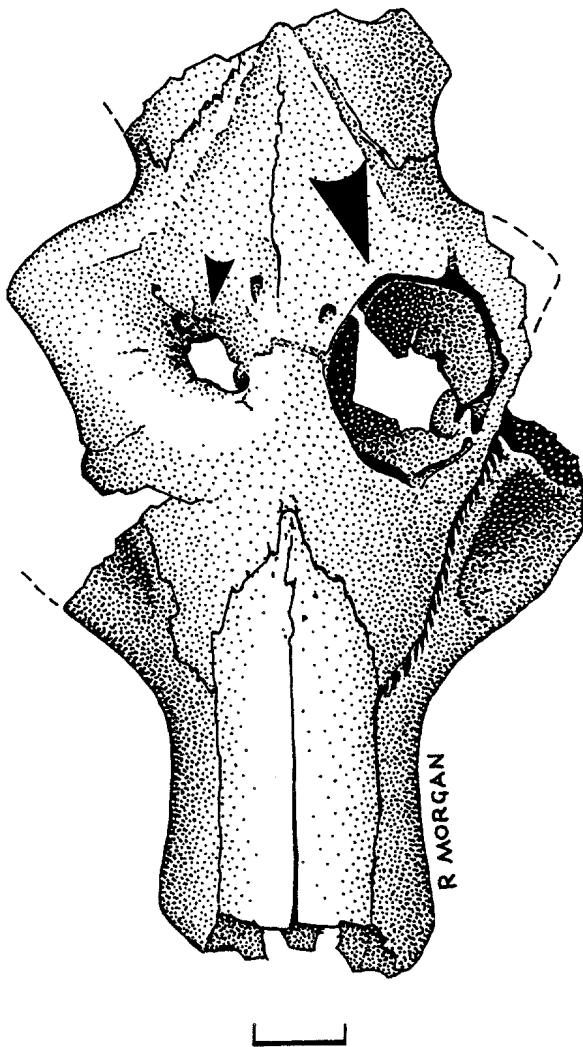


Fig. 5 - Partial skull of the Oligocene oreodont *Merycodon culbertsoni*, BHI 1150 (Cast = TMP 92.3.13). Brule Formation (Orellan), South Dakota, USA. Dorsal view, showing large, circular unhealed Type 1 tooth puncture (large arrow) and smaller healed Type 1 tooth puncture lesion (small arrow). Scale = 1 cm.

unhealed toothmarks does not lend support to the idea they were caused by failed predation.

Intrapack Dominance

Extant lower reptiles are capable of complex inter- and intraspecific display behavior (HOPSON, 1977). Large theropods could have engaged in similar if not more complex activities. COOMBS (1990) suggested theropods may have opened their mouths to display their teeth at conspecifics, but at times they would also have used their teeth on each other. Intraspecific behavior tends to be more complex in gregarious animals, and there is evidence to suggest that some species of large theropods and smaller theropods were social animals (COLBERT,

1989; CURRIE, 1998; FARLOW, 1976). Such social packs might even have been as highly structured socially as in extant terrestrial mammalian predators like *Canis lupus* (BALLARD *et al.*, 1987; PETERSON *et al.*, 1984; RAUSCH, 1967), *Crocota crocuta* (KRUUK, 1972), and *Panthera leo* (SCHALLER, 1972). Some of these animals engage in intraspecific or inter-pack/pride fighting and biting, resulting in cranial injuries. Dominant individuals within a group will fight with subordinates over mating privileges, hierarchical status, or food rights around a kill site. Young theropods of lower social rank may have been attacked and injured by larger, more dominant group members over such issues.

Perhaps the face or head-biting behavior was a consequence of tyrannosaur strategies to catch and kill prey. CARPENTER (1988; 1998) reported on a series of pathological caudal vertebrae in *Edmontosaurus* that he ascribed to a *Tyrannosaurus* bite. Hadrosaur cranial elements like jugals and dentaries bearing unhealed tyrannosaur toothmarks are occasionally found in Dinosaur Provincial Park, suggesting that perhaps tyrannosaurs grabbed their victims by the head/neck region to subdue them with quick, powerful, crushing bites. When attacking conspecifics their biting strategies may have been similar. The thickened frontoparietal complex in tyrannosaurids may have helped to protect the brain from fatal penetrating bites.

Subadult Dispersal

Half-grown tyrannosaurids may have been forced out of family/hunting units at the onset of the breeding season, as is seen in many extant mammalian carnivores (SCHALLER, 1972). Perhaps they were persuaded to leave by being bitten by dominant group members. Once they left the security of the pack, these relatively young, socially inexperienced animals may have had decreased chances of survival. However, full adults have similar injuries, suggesting that this is not the most likely scenario.

OTHER EXPLANATIONS FOR FACIAL PATHOLOGIES

Other pathological conditions could potentially lead or contribute to cranial injuries. A malformed or malpositioned maxillary tooth could rub against the bone of the dentary. However, the distribution of the multiple lesions observed in some specimens (such as inside the lower jaw of the *Sinraptor*), and the rarity of malformed or maloccluding large theropod teeth (ROTHSCHILD, 1997) argue against this hypothesis. The lesions might also have been caused by the sharp-edged, broken bones of the animals being eaten. However, fresh prey bones are unlikely to have caused such deep injuries on the outside of the jaws. Parasite damage might also be the source

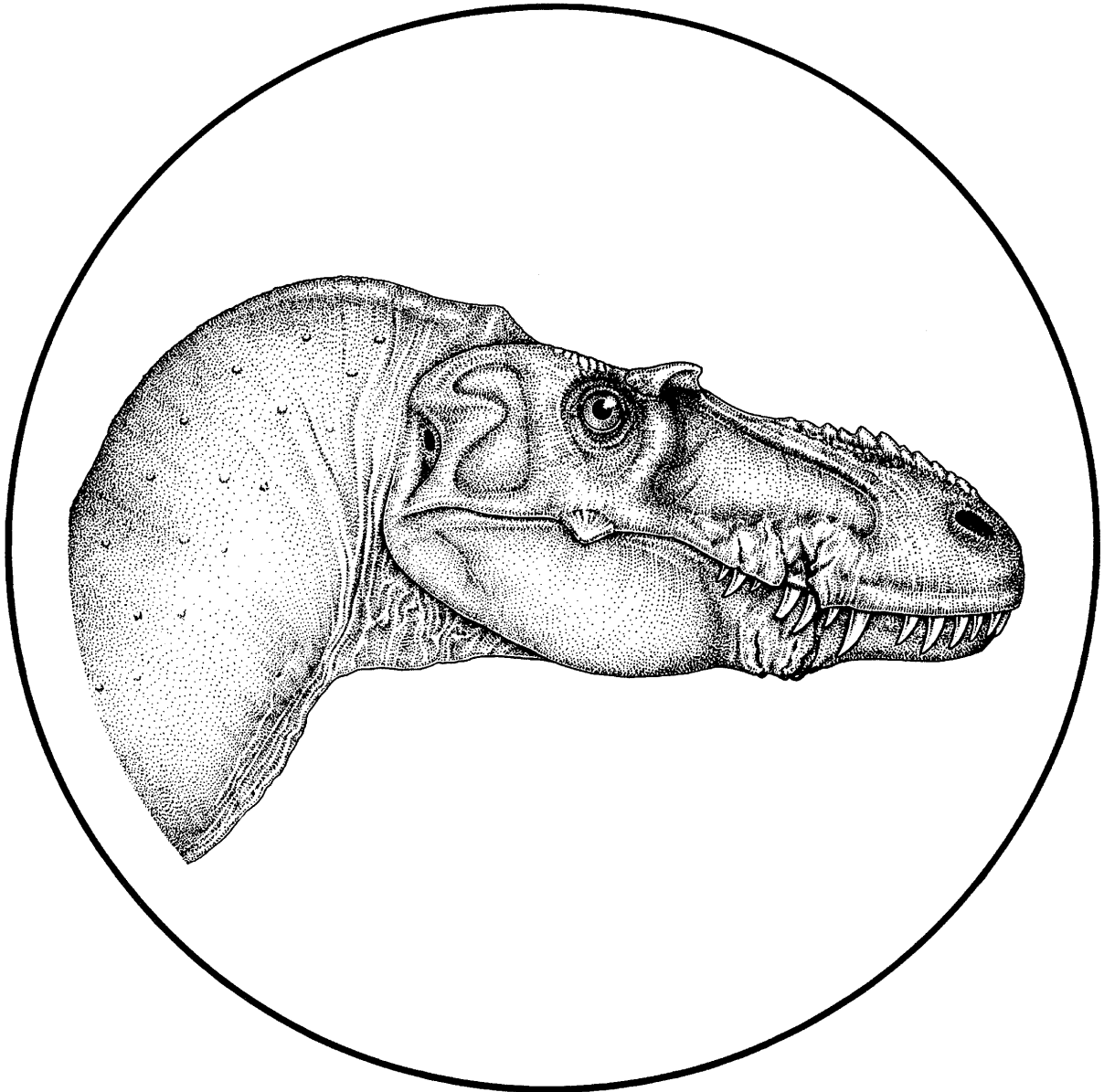


Fig. 6 - Reconstructed head of the Late Cretaceous subadult tyrannosaurid *Gorgosaurus libratus* showing bone, tooth and soft tissue injuries following facial bite delivered by a conspecific.

of the healed/healing injuries, although the unilateral occurrence and subparallel arrangement of lesions in *Sinraptor* (Fig. 1) cannot be explained so easily by this hypothesis.

COMPLICATIONS ARISING FROM FACIAL WOUNDS

When these animals suffered serious bone injuries, there would also have been associated trauma to the overlying soft tissues. Muscle masses, nerves and other soft tissues would have been severed, bruised or otherwise traumatized. Skin tissue was lacerated, leaving the wounds open to bacterial/fungal infection, or attacks by insects (Fig. 6).

A variety of infectious bacterial agents may have been carried between the tooth serrations (ABLER, 1992). These pathogens could have been transferred to a conspecific through biting. The prey of the extant Komodo dragon *Varanus komodoensis* sometimes escapes after being bitten. However, the septic bite causes the eventual death of the victim, leaving its carcass available for other Komodo dragons (AUFFENBERG, 1981). This might explain why large theropod facial wounds usually only show partial healing. In this scenario, the theropod would survive and escape a clash with another, heal its wounds to varying degrees, but would die shortly thereafter. Injured large theropods might also have

accidentally infected their own wounds by scavenging rotting, infectious carcasses. Other post-trauma mortality factors could include starvation, dipsosis, shock, secondary soft tissue injuries, or exposure.

AGGRESSION IN TYRANNOSAURIDS

While the lesions described here can tell us much about large theropod osteopathy and possible behavior, they can enlighten us on other specific aspects of large theropod paleobiology as well. Tyrannosaurs are considered by some workers as being either active pursuit predators, or obligate scavengers of carcasses. Although the truth is almost certainly between the two extremes, discussion of which feeding mechanism predominated has been one of the ongoing debates about large theropod paleobiology (FARLOW, 1994; HORNER, 1994; HORNER & LESSEM, 1993; LAMBE, 1917). While we support the concept that tyrannosaurs were capable, active predators, there is also good evidence in Alberta for scavenging at mass death sites of *Centrosaurus* (CURRIE & DODSON, 1984), *Pachyrhinosaurus*, and *Edmontosaurus* (RYAN *et al.*, 1995). At these sites, shed tooth crowns of theropods and toothmarked prey bone (with no healing) are found amongst the disarticulated skeletal remains of herbivores that appear to have died of other causes. Healing cranial bite trauma similar to the examples described in this paper is known (but poorly documented) in *Tyrannosaurus* (LARSON, 1991; MOL-

NAR, 1991). The lesions are larger than those in *Sinraptor* and the Judithian tyrannosaurids. After more than a century of collecting, *T. rex* is still the only Llanian theropod large enough to inflict this damage. Therefore, it is likely that cranial wounding in this species could only have been made by other *T. rex* individuals. If *T. rex* engaged in potentially injurious or lethal fights with equal-sized conspecifics, then there is no reason why a hungry *T. rex* could not have been capable of biting and bringing down large and comparatively helpless prey such as hadrosaurs. Scavenging was likely when carcasses were available, although this source of food was probably unreliable.

SUMMARY

A preliminary review of paleopathology of some Upper Jurassic and Late Cretaceous large theropod cranial elements suggests intra- and/or interspecific face/head-biting behavior in sinraptorids, tyrannosaurids and possibly other theropod families. There are striking similarities between the lesions and unhealed theropod toothmarks on prey bone. This point leads us to conclude that these lesions are remnants of a previous agonistic, biting encounter with another large predator, perhaps conspecifics. Whether these bites were acquired during fights over food, territory, mates, or during some elaborate courtship behavior cannot be determined. Territoriality, injuries to dispersing subadults, and fights over

TABLE II

Articulated or associated tyrannosaurid skeletal material from the Late Cretaceous of Alberta, Canada housed in TMP collections; wholly/partly prepared and with certain pathological conditions noted. Unprepared TMP specimens not listed.

IDENTIFICATION	AGE	FACE BITES	INJURED TEETH?	INJURED FIBULA?
<i>Albertosaurus</i> TMP 81.10.1	Adult	No	No	[2](0)
<i>Albertosaurus</i> TMP 85.98.1	Adult	No	No	^
<i>Albertosaurus</i> TMP 86.64.1	Subadult	Yes	No	?
<i>Daspletosaurus</i> TMP 85.62.1	Adult	Yes	Not preserved	[2](0)
<i>Daspletosaurus</i> TMP 94.143.1	Subadult	Yes	Yes	?
<i>Gorgosaurus</i> ROM 1247	Subadult	+	No	[2](1)
<i>Gorgosaurus</i> TMP 68.3.1	Adult	No skull	No	[0] (0)
<i>Gorgosaurus</i> TMP 73.30.1	Subadult	No skull	No	[2] (0)
<i>Gorgosaurus</i> TMP 86.144.1	Subadult	No	No	[1] ?
<i>Gorgosaurus</i> TMP 91.36.500	Subadult	Yes	Yes	[2](1)
<i>Gorgosaurus</i> TMP 94.12.155 (2 dentaries, 1 surangular)	Juvenile	No	No	[0] (0)
<i>Gorgosaurus</i> TMP 94.12.602	Adult	Skull fragmented	Unknown; dentition incomplete	[1*](1)
<i>Tyrannosaurus</i> TMP 81.6.1	Adult	No	No	?

[] - Number of fibulae found in quarry. () - Number of fibulae showing healed/healing fractures. * - Field excavation still unfinished. ? - Preparation uncompleted/ongoing. + - Cast of poor quality, lesions (if present) unobservable. ^ - Currently in long-term storage and unavailable for inspection.

food resources seem most plausible. The relative frequency of head or face-biting wounds in tyrannosaurids cannot be established with certainty at present because of small sample size, but the phenomenon does not seem to have been rare. Of all relatively complete, prepared tyrannosaurid skulls in Tyrrell Museum collections (TABLE II), four of nine (44%) show varying degrees of healed bite trauma, with subadults affected most often (three of five, or 60%). References to similar pathologies in allosaurids remain largely unsubstantiated and the significance of this apparent rarity needs to be addressed.

The causes of death for the theropods investigated in this study are unknown. The bites were not immediately fatal, and bone fracture and trauma repair rates are unknown for theropods. Therefore the lengths of time the animals lived after their respective injuries cannot be determined. Incomplete healing of the cranial injuries suggests that death occurred within relatively short periods (perhaps several weeks) after wounding. Possibly the injuries became infected, or perhaps the jaw injuries interfered with feeding capabilities.

Head or face-biting behavior might be related to intraspecific territoriality, social dominance, courtship, feeding, or an as yet unknown aspect of large theropod behavior. Large theropods have long been regarded as dangerous and aggressive animals. Unhealed toothmarks on prey bone cannot support this hypothesis alone, as they could have resulted from scavenging of carcasses. The pathological evidence of healing head wounds in the large theropods described here is the first evidence that confirms their aggressive capabilities. Therefore, not only can the under-utilized study of paleopathology provide data on ancient injuries and disease processes, it can also be a powerful tool for the better understanding and interpretation of behavioral aspects of extinct vertebrates.

ABBREVIATIONS

BHI - Black Hills Institute, Hill City, South Dakota, USA; DPP - Dinosaur Provincial Park, Alberta, Canada; FMNH - Field Museum of Natural History, Chicago, Illinois, USA; IVPP - Institute of Vertebrate Paleontology and Paleoanthropology, Beijing, China; PIN - Paleontological Institute, Moscow, Russia; ROM - Royal Ontario Museum, Toronto, Ontario, Canada; SGM - Ministère de l'Énergie et des Mines, Rabat, Morocco; TMP - Royal Tyrrell Museum of Paleontology, Drumheller, Alberta, Canada; USNM - United States National Museum of Natural History, Smithsonian Institution, Washington, D.C., USA.

NOTES ADDED IN PROOF

As this paper goes to press, the senior author is engaged in the preparation of a new *Gorgosaurus libratus* specimen from Dinosaur Provincial Park, TMP 99.33.1. While work on this subadult skeleton has not been completed, one side of the skull shows lesions typical of intraspecific biting. Details of dental and fibula pathology remain to be determined, although several of the gastralia show well-healed fractures.

ACKNOWLEDGEMENTS

We thank Tracy Ford and George Olshevsky for their comments on the "*Labrosaurus*" dentary, and Mike Brett-Surman who arranged for access to the specimen. Kent Wallis spent many hundreds of hours carefully preparing the *Sinraptor* skull. Brady Rennie and Shane Leuck of Medicine Hat, Alberta brought TMP 96.5.13 to our attention. Rod Morgan (Calgary, Alberta) prepared Figure 5, and Michael Skrepnick (Okotoks, Alberta) prepared Figures 3, 4 and 6. We thank Mike Todor Photography (Drumheller, Alberta) for Figure 2. Dan Brinkman, Lindsay Cook, Clive Coy, Jim Farlow, Mark Mitchell, Ralph Molnar, Patty Ralrick, Allison Tumarkin and Matt Vickaryous offered useful suggestions as the manuscript developed. We are grateful to Dr. Thomas R. Holtz, Jr. for reviewing this article.

REFERENCES

- ABEL, O. (1922) - Die Schnauzenverletzungen der Parasuchier und ihre Biologische Bedeutung. *Paleontol. Zeit.*, **5**(1): 26-57.
- ABLER, W.L. (1992) - The Serrated Teeth of Tyrannosaurid Dinosaurs, and Biting Structures in Other Animals. *Paleobiology*, **18**: 161-183.
- AKERSTEN, W.A. (1985) - Canine Function in *Smilodon* (Mammalia; Felidae; Machairodontidae). *Contrib. Sci., Nat. Museum Los Angeles County*, **356**: 1-22.
- ALEXANDER, R.M. (1996) - *Tyrannosaurus* on the Run. *Nature*, **379**: 121.
- AMES, J.A. & MOREJOHN, G.V. (1980) - Evidence of White Shark, *Carcharodon carcharias*, Attacks on Sea Otters, *Enhydra lutris*. *Calif. Fish Game*, **66**: 196-209.
- ANONYMOUS (1991) - The Largest *T. rex* Discovered. *Geol. Today*, **7**(1): 11-12.
- ANONYMOUS (1996) - Two New African Theropods. *Dinosaur Discoveries*, **1**: 3.
- ARGAST, S.; FARLOW, J.O.; GABET, R.M. & BRINKMAN, D.L. (1987) - Transport-Induced Abrasion of Fossil Reptilian Teeth: Implications for the Existence of Tertiary Dinosaurs in the Hell Creek Formation, Montana. *Geology*, **15**: 927-930.
- AUFFENBERG, W. (1981) - *The Behavioral Ecology of the Komodo Dragon*. University of Florida, Gainesville, 406 pp.
- BALLARD, W.B.; WHITMAN, J.S. & GARDNER, C.L. (1987) - Ecology of an Exploited Wolf Population in South-Central Alaska. *Wildl. Mono.*, **98**: 1-54.
- BASCHET, E. (1982) - *The Camera Never Lies - A Book of Extraordinary and Bizarre Photographs*. Webb & Bower, Exeter, 119 pp.

- BATTAGLIA, C.A. (1979) - In Defense of Dinosaurs. *Johns Hopkins Mag.*, **30**(2): 20-27.
- BELL, G.L., JR. & MARTIN, J.E. (1995) - Direct Evidence of Aggressive Intraspecific Competition in *Mosasaurus conodon* (Mosasauridae:Squamata). *J. Vertebr. Paleontol.*, **15**(3): 18A.
- BERZIN, A.A. (1971) - *The Sperm Whale (Kashalot)*. Tikhookeanskii Nauchno-Issledovatel'skii Institut Rybnogo Khozyaistva I Okeanografii (Pacific Scientific Research Institute of Fisheries and Oceanography). Izdatel'stvo "Pishchevaya Promyshlennost", Moskva. Translated from Russian, Israel program for scientific translations, Jerusalem, 1972, 394 pp.
- BLANC, C.P. & CARPENTER, C.C. (1969) - Studies on the Iguanidae of Madagascar III. Social and Reproductive Behavior of *Chalarodon madagascariensis*. *J. Herpetol.*, **3**(3-4): 125-134.
- BLUMENSCHINE, R.J.; MAREAN, C.W. & CAPALDO, S.D. (1996) - Blind Tests of Inter-Analyst Correspondence and Accuracy in the Identification of Cut Marks, Percussion Marks, and Carnivore Tooth Marks from Bone Surfaces. *J. Archaeol. Sci.*, **23**: 493-507.
- BOARDMAN, W.S.J. & SIBLEY, M.D. (1991) - The Captive Management, Diseases and Veterinary Care of the Tuatara. *Ann. Proc. Am. Assoc. Zoo Vet., Calgary, Alta.*, Sept. 28-Oct. 3: pp. 159-167.
- BRAATTSTROM, B.H. (1974) - The Evolution of Reptilian Social Behavior. *Am. Zool.*, **14**: 35-49.
- BRAZAITIS, P. (1981) - Maxillary Regeneration in a Marsh Crocodile, *Crocodylus palustris*. *J. Herpetol.*, **15**(3): 360-362.
- BRILLET, C. (1986) - Comportement Agonistique et Structure Sociale du Lezard Nocturne Malgache *Paroedura pictus* (PETERS, 1854) (Sauria, Gekkonidae) Etude au Laboratoire. *Amphibia-Reptilia*, **7**: 237-258.
- BUFFETAUT, E. (1983) - Wounds on the Jaw of an Eocene Mesosuchian Crocodylian as Possible Evidence for the Antiquity of Crocodylian Intraspecific Fighting Behavior. *Palaeontol. Z.*, **57**: 143-145.
- BUFFETAUT, E. & SUTEETHORN, V. (1989) - A Sauropod Skeleton Associated with Theropod Teeth in the Upper Jurassic of Thailand: Remarks on the Taphonomic and Paleoeological Significance of Such Associations. *Palaeogeog., Palaeoclimatol., Palaeoecol.*, **73**: 77-83.
- BYERS, J.A. (1987) - Why the Deer and the Antelope Play. *Nat. Hist.*, **96**(5): 54-60.
- CAMPAGNA, C. & LE BOEUF, B.J. (1988) - The Breeding Biology of the Southern Sea Lion. *Behavior*, **104**: 233-261
- CAPASSO, L.; BACCHIA, F.; RABOTTINI, N.; ROTHSCHILD, B.M. & MARIANI-CONSTANTINI, R. (1996) - Fossil Evidence of Intraspecific Aggressive Behavior of Devonian Giant Fishes (Arthrodira, Dinichthyidae). *J. Paleopathol.*, **8**(6): 153-160.
- CARPENTER, K. (1988) - Evidence of Predatory Behavior by *Tyrannosaurus*. Inter. Symp. Vert. Behav. As Derived from the Fossil Rec., Museum of the Rockies, Bozeman, Montana, Sept. 8-10, no pagination.
- CARPENTER, K. (1990) - Variation in *Tyrannosaurus rex*, in CARPENTER, K. & CURRIE, P.J., *Dinosaur Systematics- Approaches and Perspectives*, Cambridge University Press, Cambridge. pp. 141-145.
- CARPENTER, K. (1998) - Evidence of Predatory Behavior by Carnivorous Dinosaurs. *Gaia*, **15** (this volume).
- CIGALA-FULGOSI, F. (1990) - Predation (or Possible Scavenging) by a Great White Shark on an Extinct Species of Bottlenosed Dolphin in the Italian Pliocene. *Tertiary Res.*, **12**(1): 17-36.
- CLARKE, R. & PALIZA, O. (1988) - Intraspecific Fighting in Sperm Whales. *Int. Whaling Comm. Rep.*, **38**: 235-241.
- COLBERT, E.H. (1989) - The Triassic Dinosaur *Coelophysis*. *Museum Northern Arizona, Bull.*, **57**: 160 pp.
- COOMBS, W.P., JR. (1990) - Behavior Patterns of Dinosaurs, in D.B. WEISHAMPEL; P. DODSON & OSMOLSKA H. (Eds.), *The Dinosauria*, Univ. California Press, Berkeley, pp. 32-42.
- COTT, H.B. (1961) - Scientific Results of an Inquiry into the Ecology and Economic Status of the Nile Crocodile (*Crocodylus niloticus*) in Uganda and Northern Rhodesia. *Trans. Zool. Soc. London*, **29**: 211-337.
- COURVILLE, C.B. (1953) - Cranial Injuries in Prehistoric Animals with Special Notes on a Healed Wound of the Skull in the Dire Wolf *Canis [Aenocyon] dirus* [Leidy] and a Mortal Wound in the California Black Bear (*Ursus americanus*). *Bull. Los Angeles Neurol. Soc.*, **18**(3): 117-126.
- CRAWSHAW, G.J. (1989) - Medical Care of Amphibians. *Ann. Proc. Am. Assoc. Zoo Vet.*, Greensboro, North Carolina, Oct. 14-19: pp. 155-165.
- CROCKETT, C.M. (1984) - Family Feuds. *Nat. Hist.*, **93**(8): 54-63.
- CURRIE, P.J. (1983) - Hadrosaur Trackways from the Lower Cretaceous of Canada. *Acta Palaeontol. Polonica*, **28**: 63-73.
- CURRIE, P.J. & DODSON, P. (1984) - Mass Death of a Herd of Ceratopsian Dinosaurs, in REIF, W.-E. & WESTPHAL, F. (Eds.), *Third Symposium on Mesozoic Terrestrial Ecosystems, Short Papers*, Tubingen, pp.61-66.
- CURRIE, P.J. (1985) - Cranial Anatomy of *Stenonychosaurus inequalis* (Saurischia, Theropoda) and Its Bearing on the Origin of Birds. *Can. J. Earth Sci.*, **22**: 1643-1658.
- CURRIE, P.J. (1989) - Long Distance Dinosaurs. *Nat. Hist.*, **6**: 60-65.
- CURRIE, P.J. & ZHAO, X.-J. (1993) - A New Carnosaur (Dinosauria, Theropoda) from the Jurassic of Xinjiang, People's Republic of China. *Can. J. Earth Sci.*, **30**: 2037-2081.
- CURRIE, P.J. & JACOBSEN, A. (1995) - An Azhdarchid Pterosaur Eaten by a Velociraptorine Theropod. *Can. J. Earth Sci.*, **32**: 922-925.
- CURRIE, P.J. (1998) - Possible Evidence of Gregarious Behavior in Tyrannosaurids. *Gaia*, **15** (this volume).
- CZERKAS, S.M. & GLUT, D.F. (1982) - *Dinosaurs, Mammoths, and Cavemen-The Art of Charles R. Knight*. E.P. Dutton, New York, 120 pp.
- DANIS, J. (1973) - *The Age of Dinosaurs in Canada*. Natl. Museum Nat. Sci., Natl. Museum Can., Ottawa, 36 pp.
- DEMERE, T.A. & CERUTTI, R.A. (1982) - A Pliocene Shark Attack on a Cethotheriid Whale. *J. Paleontol.*, **56**(6): 1480-1482.
- DONG, Z.M. & CURRIE, P.J. (1996) - On the Discovery of an Oviraptorid Skeleton on a Nest of Eggs at Bayan Mandahu, Inner Mongolia, People's Republic of China. *Can. J. Earth Sci.*, **33**: 631-636.
- EFFINGER, J.A. (1998) - Entelodontidae, in JANIS C.M., SCOTT K.M. & JACOBS L.L. (Eds.), *Evolution of Tertiary Mammals of North America. 1: Terrestrial Carnivores, Ungulates, and Ungulate-like Mammals*. Cambridge Univ. Press, Cambridge, pp. 375-380.
- ERICKSON, G. (1995) - Split Carinae on Tyrannosaurid Teeth and Implications of Their Development. *J. Vertebr. Paleontol.*, **15**(2): 268-274.
- ERICKSON, G. (1996) - Toothlessness in American Alligators, *Alligator mississippiensis*. *Copeia*, **1996**(3): 739-743.
- ERICKSON, G. & OLSON, K.H. (1996) - Bite Marks Attributable to *Tyrannosaurus rex*: Preliminary Description and Implications. *J. Vertebr. Paleontol.*, **16**(1): 175-178.
- ERICKSON, G.; VAN KIRK, S.D.; SU, J.; LEVENSTON, M.E.; CALER, W.E. & CARTER, D.R. (1996) - Bite-Force Estimation for *Tyrannosaurus rex* from Tooth-Marked Bones. *Nature*, **382**: 706-708.
- EVANS, S.E. (1983) - Mandibular Fracture and Inferred Behavior in a Fossil Reptile. *Copeia*, **1983**(3): 845-847.

HEAD-BITING BEHAVIOR IN THEROPOD DINOSAURS: PALEOPATHOLOGICAL EVIDENCE

- FARLOW, J.O. (1976) - Speculations about the Diet and Foraging Behavior of Large Carnivorous Dinosaurs. *Am. Midl. Naturalist*, **95**: 186-191.
- FARLOW, J.O. & BRINKMAN, D.L. (1987) - Serration Coarseness and Patterns of Wear of Theropod Dinosaur Teeth. *21st Ann. Meeting, South-Central Section, Geol. Soc. Amer.*, Abstracts with Programs, Waco, Texas, p. 151.
- FARLOW, J.O.; BRINKMAN, D.L.; ABLER, W.L. & CURRIE, P.J. (1991) - Size, Shape, and Serration Density of Theropod Dinosaur Lateral Teeth. *Modern Geol.*, **16**: 161-198.
- FARLOW, J.O. (1994) - Speculations About the Carrion-Locating Ability of Tyrannosaurs. *Hist. Biol.*, **7**: 159-165.
- FARLOW, J.O.; SMITH, M.B. & ROBINSON, J.M. (1995) - Body Mass, Bone Strength Indicator, and Cursorial Potential of *Tyrannosaurus rex*. *J. Vertebr. Paleontol.*, **15**(4): 713-725.
- FAUST, R.J. & BAYLESS, M.K. (1996) - Nile Monitors - Ecology, Morphology and Husbandry. *Reptiles*, **4**(11): 68-83.
- FIORILLO, A. (1991a) - Taphonomy and Depositional Setting of Careless Creek Quarry (Judith River Formation), Wheatland County, Montana, U.S.A. *Palaeogeog., Palaeoclimatol., Palaeoecol.*, **81**: 281-311.
- FIORILLO, A. (1991b) - Prey Bone Utilization by Predatory Dinosaurs. *Palaeogeog., Palaeoclimatol., Palaeoecol.*, **88**: 157-166.
- FOOTT, J.O. (1970) - Nose Scars in Female Sea Otters. *J. Mamm.*, **51**: 621-622.
- GAHLOT, T.K.; CHOUDHARY, R.J.; CHOUHAN, D.S.; CHAWLA, C.K. & KRISHNAMURTHY, D. (1989) - Clinical Evaluation of Interdental Wiring Technique for Mandibular Fracture Repair in Camels (*Camelus dromedarius*). *Ind. Vet. J.*, **66**: 251-254.
- GILMORE, C.W. (1920) - Osteology of the Carnivorous Dinosauria in the United States National Museum, with Special Reference to the Genera *Antrodemus* (*Allosaurus*) and *Ceratosauros*. *Bull. U.S. Nat. Museum*, **60**: 1-154.
- GILMORE, C.W. (1946) - Notes on Recently Mounted Reptile Fossil Skeletons in the United States National Museum. *Proc. U.S. Nat. Museum*, **96**: 195-203.
- GLUT, D. (1980) - *The Dinosaur Scrapbook*. Citadel Press, Secaucus, New Jersey, 320pp.
- HARLAN, B. (1990) - The Rex of All - *Tyrannosaurus gigantus*. *Newsweek*, **Oct.**: 63.
- HOPSON, J.A. (1977) - Relative Brain Size and Behavior in Archosaurian Reptiles. *Ann. Rev. Ecol. Syst.*, **8**: 429-448.
- HORNER, J. R. (1982) - Evidence of Colonial Nesting and 'Site Fidelity' Among Ornithischian Dinosaurs. *Nature*, **297**: 675-676.
- HORNER, J. R. & LESSEM, D. (1993) - *The Complete T. Rex*. Simon and Schuster, New York, 239 pp.
- HORNER, J. R. (1994) - Steak Knives, Beady Eyes, and Tiny Little Arms. (A Portrait of *T. rex* as a Scavenger), in ROSENBERG, G.D. & WOLBERG, D.L. (Eds.), *Dinofest. Paleontol. Soc. Special Publ.*, **7**: 151-164.
- HUTCHINSON, J.H. & FRYE, F.L. (1989) - Pathologies of the Shell in Eocene Turtles. *J. Vertebr. Paleontol.*, **9**(3): 26A.
- JACOBSEN, A. R. (1998) - Feeding Behavior of Carnivorous Dinosaurs as Determined by Tooth Marks on Dinosaur Bones. *Hist. Biol.*, **13**: 17-26.
- KELLEY, K.V., JR. (1971) - *Kelley's Guide to Fossil Sharks*. 2nd Edition, M&M Printing, Ruskin, Florida, 38 pp.
- KNIGHT, C.R. (1942) - Parade of Life Through the Ages. *Natl. Geograph. Mag.*, **81**(2): 141-184.
- KRUUK, H. (1972) - *The Spotted Hyena - A Study of Predation and Social Behavior*. Univ. Chicago Press, Chicago, 335 pp.
- LAMBE, L.M. (1917) - The Cretaceous Carnivorous Dinosaur *Gorgosaurus*. *Geol. Surv. Can., Mem.*, **100**: 1-84.
- LAMBERT, D. (1993) - *The Ultimate Dinosaur Book*. Dorling Kindersley, London, 192 pp.
- LARSON, P.L. (1991) - The Black Hills Institute *Tyrannosaurus* - A Preliminary Report. *J. Vertebr. Paleontol.*, **11**(3): 41A-42A.
- LE BOEUF, B.J. & MESNICK, S. (1990) - Sexual Behavior of Male Northern Elephant Seals: I. Lethal Injuries to Adult Females. *Behavior*, **116**(1-2): 143-162.
- LESSEM, D. (1988) - *T. rex* Exposed? *Rotunda*, **21**(2): 34-44.
- MCGINNIS, H.J. (1982) - *Carnegie's Dinosaurs*. The Board of Trustees, Carnegie Inst., Pittsburgh, 119 pp.
- MADSEN, J.H., JR. (1976) - *Allosaurus fragilis* - a revised osteology. *Utah Geol. Min. Surv., Utah Dept. Nat. Res.*, **109**: 1-163 pp.
- MARTIN, L.D. & ROTHSCHILD, B.M. (1989) - Paleopathology and Diving Mosasosaurs. *Am. Scientist*, **77**: 460-467.
- MESTEL, R. (1994) - Seamy Side of Sea Otter Life. *New Scientist*, **141**(1913): 5.
- MILLER, G.J. (1980) - Some New Evidence in Support of the Stabbing Hypothesis for *Smilodon californicus* BOVARD. *Carnivore*, **3**(2): 8-26.
- MOLNAR, R.E. & FARLOW, J.O. (1990) - Carnosaur Paleobiology, in WEISHAMPEL D. B.; DODSON P. & OSMÓLSKA H. (Eds.), *The Dinosauria*, Univ. California Press, Berkeley, pp. 210-224.
- MOLNAR, R.E. (1991) - The Cranial Morphology of *Tyrannosaurus rex*. *Palaeontographica, A*, **217**: 137-176.
- MONASTERSKY, R. (1989) - A Nose for Combat. *Sci. News*, **136**: 318.
- NAEYE, R. (1996) - *T. Rex* Gets Tougher. *Earth*, **5**(1): 12.
- NAISH, D. (1998) - Theropods Eating Theropods in the Wealden Group Fauna of England (Abstract), in JAGT, J.W.M.; LAMBERS, P.H.; MULDER, E.W.A. & SCHULP, A.S. (Eds.), *Third European Workshop on Vertebrate Palaeontology: Programme and Abstracts*. Natuurhist. Museum Maastrich, p. 56.
- NEWMAN, B.H. (1970) - Stance and Gait in the Flesh-Eating Dinosaur *Tyrannosaurus*. *Biol. J. Linn. Soc.*, **2**: 119-123.
- NORELL, M.A.; CLARK, J.M.; CHIAPPE, L.M. & DASHZEVEG, D. (1995) - A Nesting Dinosaur. *Nature*, **378**: 774-776.
- OLSHEVSKY, G. (1991) - *A Revision of the Parainfraclass Archosauria COPE, 1869, Excluding the Advanced Crocodylia. Mesozoic Meanderings*, Publications Requiring Research, San Diego, California, 196 pp.
- OSBORN, H.F. (1913) - *Tyrannosaurus*, Restoration and Model of the Skeleton. *Bull. Am. Museum Nat. Hist.*, **32**: 91-92.
- PAUL, G.S. (1988) - *Predatory Dinosaurs of the World - A Complete Illustrated Guide*. Simon & Schuster, New York, 464 pp.
- PETERSEN, K.; ISAKSON, J.I. & MADSEN, J.H., JR. (1972) - Preliminary Study of Paleopathologies in the Cleveland-Lloyd Dinosaur Collection. *Utah Acad. Sci. Proc.*, **49**: 44-47.
- PETERSON, R.O.; WOOLINGTON, J.D. & BAILEY, T.N. (1984) - Wolves of the Kenai Peninsula, Alaska. *Wildl. Mono.*, **88**: 52 pp.
- POLIS, G.A. (1981) - The Evolution and Dynamics of Intraspecific Predation. *Ann. Rev. Ecol. Syst.*, **12**: 225-251.
- RAUSCH, R.A. (1967) - Some Aspects of the Population Ecology of Wolves, Alaska. *Am. Zool.*, **7**: 253-265.
- REID, M. (1990) - *The Last Great Dinosaurs - A Guide to the Dinosaurs of Alberta*. Discovery Books, Red Deer College Press, 184 pp.
- ROTHSCHILD, B.M. & TANKE, D.H. (1992) - Paleopathology of Vertebrates: Insights to Lifestyle and Health in the Geological Record. *Geosci. Can.*, **19**(2): 73-82.
- ROTHSCHILD, B.M. & MARTIN, L.D. (1993) - *Paleopathology - Disease in the Fossil Record*. CRC Press, Boca Raton, 386 pp.
- ROTHSCHILD, B.M. (1997) - Dinosaurian Paleopathology, in FARLOW J.O. & BRETT-SURMAN M.K. (Eds.), *The Complete Dinosaur*, Indiana Univ. Press, Bloomington, pp. 426-448.
- ROTHSCHILD, B.M.; TANKE, D.H. & CARPENTER, K. (1997) - Tyrannosaurs Suffered from Gout. *Nature*, **387**: 357.

- RUSSELL, D.A. (1970) - Tyrannosaurs from the Late Cretaceous of Western Canada. *Natl. Museum Nat. Sci., Publ. in Paleontol.*, 1: 1-34.
- RYAN, M.J.; BELL, J.G. & EBERTH, D.A. (1995) - Taphonomy of a Hadrosaur (Ornithischia:Hadrosauridae) Bonebed from the Horseshoe Canyon Formation (Early Maastrichtian), Alberta, Canada. *J. Vertebr. Paleontol.*, 15(3): 51A.
- SAWYER, G.T. & ERICKSON, B.R. (1985) - Injury and Diseases in Fossil Animals - The Intriguing World of Paleopathology. *Encounters*, May/June: 25-28.
- SAWYER, G.T. & ERICKSON, B.R. (1998) - Paleopathology of the Paleocene Crocodile *Leidyosuchus* (= *Borealosuchus*) *Formidabilis*. Monograph, Volume 4: Paleontology. *Sci. Museum Minnesota*, St. Paul, 38 pp.
- SCHALLER, G.B. (1972) - *The Serengeti Lion. A Study of Predator-Prey Relations*. Univ. Chicago Press, Chicago, 480 pp.
- SCHOWALTER, T. (1995) - Jaws of Giants - Bone Scars Suggest Dinosaurs Often Fought. *The Calgary Herald*, Sept. 16, 1995: B6. Reprinted as: Museum Collecting Fossilized Bones Marked by Injury. *The Drumheller Mail*, Oct. 4, 1995: 5.
- SCHWIMMER, D.R. & WILLIAMS, J.D. (1991) - Evidence of Scavenging by the Selachian *Squalicorax kaupi* in Upper Marine Sediments of the Eastern Gulf Coastal Plain. *J. Vertebr. Paleontol.*, 11(3): 55A.
- SERENO, P.C. & NOVAS, F.E. (1993) - The Skull and Neck of the Basal Theropod *Herrerasaurus ischigualastensis*. *J. Vertebr. Paleontol.*, 13(4): 451-476.
- SINCLAIR, W.J. (1922) - Entelodonts from the Badlands of South Dakota in the Geological Museum of Princeton University. *Proc. Am. Phil. Soc.*, 40: 467-475.
- STAEDLER, M. & RIEDMAN, M. (1993) - Fatal Mating Injuries in Female Sea Otters (*Enhydra lutrius nereis*). *Mammalia*, 57(1): 135-139.
- STAEDTER, T. (1997) - Scavenging Machines. *Earth*, 6(4): 16.
- STOUT, W.; PREISS, B. & SERVICE, W. (1981) - *The Dinosaurs - A Fantastic New View of a Lost Era*. Bantam Books, New York, 160 pp.
- TANKE, D.H. & CURRIE, P.J. & LARSON, P.L. (1992) - Once Bitten Twice Shy: Predator Toothmarks on Oreodont (Mammalia: Merycoidodontoidea) Skulls, Middle and Upper Oligocene Brule Formation of South Dakota and Nebraska, USA. *J. Vertebr. Paleontol.*, 12(3): 54A-55A.
- TANKE, D.H. & CURRIE, P.J. (1995) - Intraspecific Fighting Behavior Inferred from Toothmark Trauma on Skulls and Teeth of Large Carnosaurs (Dinosauria). *J. Vertebr. Paleontol.*, 15(3): 55A.
- TANKE, D.H. & CURRIE, P.J. (1997) - Paleopathology, in CURRIE P.J. & PADIAN K. (Eds.), *The Dinosaur Encyclopedia*, Academic Press, San Diego, pp. 525-530.
- TANKE, D.H. & ROTHSCHILD, B.M. (1997) - Paleopathology, in CURRIE, P.J. & PADIAN, K. (Eds.), *Encyclopedia of Dinosaurs*, Academic Press, London, pp. 525-530.
- TANKE, D.H. & ROTHSCHILD, B.M. (1999) - *Dinosaurs: An Annotated Bibliography of Dinosaur Paleopathology and Related Topics - 1838-1999*. Privately published, 292 pp.
- THULBORN, T. (1989) - The Gaits of Dinosaurs, in GILLETTED.D. & LOCKLEY M.G. (Eds.), *Dinosaur Tracks and Traces*. Cambridge Univ. Press, Cambridge, pp. 39-50.
- THULBORN, T. & TURNER, S. (1995) - An Elasmosaur Bitten by a Pliosaur, in SARGEANT, W.A.S. (Ed.), *Vertebrate Fossils and the Evolution of Scientific Concepts: Writings in Tribute to Beverly Halstead*. Gordon and Breach, Newark, New Jersey, pp. 499-511.
- TRACY, C.R. (1976) - Tyrannosaurs: Evidence for Endothermy? *Am. Nat.*, 110:1105-1106.
- VANCE, T. (1989) - Probable Use of the Vestigial Forelimbs of the Tyrannosaurid Dinosaurs. *Bull. Chicago Herpetol. Soc.*, 24(3): 41-47.
- WEBB, G.J.W. & MESSEL, H. (1977) - Abnormalities and Injuries in the Estuarine Crocodile, *Crocodylus porosus*. *Australian Wildl. Res.*, 4: 311-319.
- WEBB, G.J.W. & MANOLIS, C. (1989) - *Crocodyles of Australia*. Reed Books Pty. Ltd., French's Forest, New South Wales, Australia, 160 pp.
- ZHAO, X.-J. & CURRIE, P.J. (1993) - A Large Crested Theropod from the Jurassic of Xinjiang, People's Republic of China. *Can. J. Earth Sci.*, 30: 2027-2036.