



# University of HUDDERSFIELD

## University of Huddersfield Repository

Ousey, Karen, Cutting, Keith, Rogers, Alan A. and Rippon, Mark

The Importance of Hydration in Wound Healing: Reinvigorating the clinical perspective

### Original Citation

Ousey, Karen, Cutting, Keith, Rogers, Alan A. and Rippon, Mark (2016) The Importance of Hydration in Wound Healing: Reinvigorating the clinical perspective. *Journal of wound care*, 25 (3). pp. 122-130. ISSN 0969-0700

This version is available at <http://eprints.hud.ac.uk/id/eprint/27032/>

The University Repository is a digital collection of the research output of the University, available on Open Access. Copyright and Moral Rights for the items on this site are retained by the individual author and/or other copyright owners. Users may access full items free of charge; copies of full text items generally can be reproduced, displayed or performed and given to third parties in any format or medium for personal research or study, educational or not-for-profit purposes without prior permission or charge, provided:

- The authors, title and full bibliographic details is credited in any copy;
- A hyperlink and/or URL is included for the original metadata page; and
- The content is not changed in any way.

For more information, including our policy and submission procedure, please contact the Repository Team at: [E.mailbox@hud.ac.uk](mailto:E.mailbox@hud.ac.uk).

<http://eprints.hud.ac.uk/>

## **The Importance of Hydration in Wound Healing: Reinvigorating the clinical perspective**

### **Authors**

Karen Ousey, PhD., Reader Advancing Clinical Practice, School of Human and Health Sciences, Institute of Skin Integrity and Infection Prevention, University of Huddersfield, Queensgate, Huddersfield, UK

Keith Cutting, Clinical Research Consultant, Hertfordshire, UK

Alan A. Rogers, BSc.(Hons), Independent Wound Care Consultant, Flintshire, UK

Mark G. Rippon, PhD., Visiting Clinical Research Fellow, School of Human and Health Sciences, Institute of Skin Integrity and Infection prevention, University of Huddersfield, Queensgate, Huddersfield, UK

### **Corresponding author:**

**Alan A. Rogers**

**23 Wood Lane**

**Holywell**

**Flintshire, CH8 7HU**

**Email: [alan@woundcaresol.co.uk](mailto:alan@woundcaresol.co.uk)**

**Tel: 01352 711347**

## **Abstract**

Balancing skin hydration levels is important as any disruption in skin integrity will result in disturbance of the dermal water balance. The discovery that a moist wound healing environment actively supports the healing response when compared to a dry environment highlights the importance of water and good hydration levels for optimal wound healing.

The benefits of “wet” or “hyper-hydrated” wound healing appears to offer benefits that are similar to those offered by moist wound healing over wounds healing in a dry environment. This suggests that the presence of free water itself during wound healing may not be detrimental to healing but that any adverse effects of wound fluid on tissues is more likely related to the biological components contained within chronic wound exudate (e.g. elevated protease levels).

Appropriate dressings applied to wounds must be able to absorb not only the exudate but also retain this excess fluid together with its protease solutes while concurrently preventing desiccation. This is particularly important in the case of chronic wounds where peri-wound skin barrier properties are compromised and there is increased permeation across the injured skin barrier. This review discusses the importance of appropriate levels of hydration in skin with a particular focus on the need for optimal hydration levels for effective healing.

**Declaration of interest:** This paper was supported by HARTMANN LTD. The authors have provided consultative services to HARTMANN LTD.

**Key Words:** wound healing, hydration, moist wound healing, wound fluid

This article briefly describes the importance of hydration in biological processes, particularly in skin homeostasis. It underlines the significance of the moist environment in the wound healing response and highlights the evidence suggesting that a “wet” or “hyper-hydrated” wound environment offers benefits similar those of a moist environment. The concept that it is the damaging biological components (e.g., proteinases) contained within chronic wound exudates and not the presence of free fluid at the wound site that are responsible for the deleterious effects of chronic wound exudate on ulcers is discussed.

## **THE LITERATURE SEARCH**

The limitations of this article include that this was not designed to be a systematic review of the literature. The databases used to search the literature were limited to Medline and Google Scholar. The search terms used included “skin structure”, “moist wound healing”, “hydration”, “moisture”, “chronic wound” and “ulcer”. The number of retrievals for each search term were not recorded. No limits were applied in relation to the year of publication. References were also selected from a range of scientific/clinical publications that were recorded in the authors’ personal bibliographic databases. Results from all sources were analysed and the relevant articles retrieved.

Clinical case studies are used as illustrative examples in support of the concepts discussed.

## **THE IMPORTANCE OF HYDRATION IN SKIN**

Water is essential for life. Without water, humans can only survive for a few days. Once living organisms ventured from the oceans onto land, the uptake and retention of water were key to their survival and the development of a barrier to water loss was an important step in the prevention of tissue desiccation. It was not until the 1940s that the precise mechanism by which the skin acts as a barrier to water loss was identified. Tape stripping studies provide evidence of the importance of the stratum corneum (SC), (Figure 1) as the region responsible for the skin’s barrier properties.<sup>1-3</sup>

Water is essential for the normal functioning of the skin and for maintaining a healthy skin.<sup>4</sup> Since the discovery of the SC’s importance in water homeostasis, there has been a significant body of work describing the precise mechanisms by which it functions in this role.<sup>4-7</sup> The skin contains approximately 30% water, but in the viable epidermis the water content can be as high as 70%. Moving outwards from the dermal-epidermal junction, this high level of water falls off quickly at the junction between the stratum granulosum (SG) and the SC where water content ranges between 15-30%.<sup>8,9</sup> The SC maintains the stable gradient of water and solutes throughout the layers of the epidermis<sup>8,10,11</sup> and it is thought that the sudden change at the SG-SC junction isolates the SC from the rest of the body and helps to conserve important solutes and water within the viable epidermis.<sup>4</sup> The SC’s ability to hold on to water depends upon two major components of this skin layer: (1) the

presence of a number of water-attracting (hygroscopic) components (collectively called natural moisturising factor (NMF)) located within the terminally differentiated, non-viable corneocytes of the SC and, (2) intercellular lipids which act as a barrier to trans-epidermal water loss (TEWL).

Water also plays a particularly important role in the correct functioning of the epidermis. For example, normal water content in the SC is required for the correct maturation of the epidermis and the formation of the SC and skin desquamation.<sup>4</sup> The enzymatic processes that are needed for normal desquamation are impaired when moisture levels in the skin are reduced leading to the appearance of dry, flaky skin (Figure 2). Disrupted function of the enzymes responsible for making the components of “natural moisturising factor” (NMF, biochemical components of skin that aid skin homeostasis) can also lead to the development of dry skin. An imbalance of the water content in the epidermis resulting from a disturbance of the SC, e.g., skin stripping from adhesive tape, increases TEWL with a corresponding alteration in gene expression in epidermal keratinocytes.<sup>12,13</sup> A recent study by Xu and co-workers<sup>14</sup> reports that hydration status of the skin directly affects the expression of inflammatory signals in the epidermis. Additionally there are several reports of the inflammatory response being elevated under conditions of water loss<sup>15-17</sup> with a corresponding increase in a variety of cytokines.<sup>14,18-21</sup>

## **SKIN INJURY**

### **Maintaining an optimal hydration level in skin**

Optimal skin hydration is an orchestrated interplay between several mechanisms and the integrity of the skin is key to moisture balance being maintained.<sup>22</sup> Within the dermal component of the skin, the water of the interstitial fluid is mostly absorbed into the extracellular matrix/connective tissue components, some of which have large capacities for water binding.<sup>23,24</sup> Although the reservoir of water in the interstitial fluid is kept in balance, it is not a static reservoir. Maintaining this level of dermal hydration is an active process, with water constantly being supplied from the blood circulatory system and drained via the lymphatics. Any disruption of this dynamic balance in tissue hydration control can result in clinical problems. For example, the uncontrolled influx of water in the form of plasma from the blood circulation and/or deficient lymphatic system drainage can lead to build-up of excessive levels of tissue water as a result of overwhelming water-absorbing capacity of the interstitial matrix, leading to tissue oedema.<sup>22,24</sup> When considering how tissue hydration levels are controlled in normal skin, there is a tightly controlled interplay between the interstitial fluid pressure, the capillary filtration pressure and the rate of lymphatic drainage, with the additional factor of the absorption capacity of the extracellular matrix.<sup>24</sup>

The interstitial fluid pressure is maintained largely by the integrity of the skin and integrity is dependent upon the barrier properties of the skin as a whole both at the large and small scale, i.e., between the various layers of the skin down to the interaction between the cellular components of the skin's layers and the chemical contributors to the skin's barrier function (e.g., skin lipids). Once the integrity of the skin is compromised, for example, physical wounding, the mechanisms responsible for maintaining the appropriate levels of tissue hydration are significantly challenged.<sup>22</sup>

- There is a reduced ability to maintain the interstitial fluid pressure needed to control fluid inflow from the blood circulation and its removal via lymphatic flow
- Blood vessel dilation resulting from inflammation increases the leakage of fluid from the blood circulation into the surround tissue
- The majority of this 'water' will be held by the high water-absorbing extracellular matrix components therefore acting as a large reservoir

### **Wound healing and hydration**

Wound healing is dependent upon the level of hydration<sup>22</sup> and it has been suggested this is the single most important external factor responsible for optimal healing.<sup>25</sup> The increased drying effect that results from a physical breach of the skin barrier properties, can to some extent, compensate for the increased fluid outflow from blood vessels in these circumstances. However, outflow of fluid from blood vessels can quickly overwhelm the fluid-absorbing capacity of the tissue and lymphatic drainage and excess fluid is drained from the wounded tissue as exudate.

Following a breach of skin integrity haemostasis is secured and physical plugging of the defect with a fibrin mesh (scab) that seals the breach takes place (Figure 3). In parallel with achieving haemostasis, an influx of inflammatory cells, commences a cascade of signalling pathways that results in cell proliferation and deposition of the extracellular matrix (ECM). Synthesis of collagen commences the generation of new tissue matrix whereby granulation tissue is laid down. The stimulation of new blood vessels into the highly vascularised granulation tissue provides the oxygen and nutrients needed to sustain tissue synthesis that occurs during the granulation phase of healing. Tissue remodelling and re-epithelialisation of the wound leads to the reconstitution of the physical barrier of the skin at the original wound site. Over the subsequent days/weeks, tissue is further remodelled and the barrier properties of the skin are reinstated at a level close to that of the pre-wounded skin (Figure 4).

### **Moist wound healing**

Landmark studies by George Winter in the 1960s showed that wounds exposed to the air and allowed to dry tend to heal slowly with poor cosmesis when compared to wounds that heal in a

moist environment.<sup>26-28</sup> The examination of tissue biopsies from these pre-clinical studies highlighted that re-epithelialisation of 'dry' wounds was impaired leading to a delay in the healing response and suggested that the physical barrier of the dry eschar tissue was an important determinant for the delayed healing response.<sup>27,29</sup> Thus, there is a clear dependency on adequate hydration if optimal healing is sought.<sup>22,26-28</sup> In Winter's studies, the air-dried partial-thickness wounds were compared with wounds that were occluded with polyurethane film dressing which maintained a moist environment and ensured that an adequate level of hydration was maintained. Since development of the concept that a moist environment aids wound healing, there has been growing evidence in support of this notion<sup>30</sup> and the wound care community has broadly accepted the concept of moist wound healing and the need for exudate management.<sup>30,32</sup> There have been numerous laboratory, preclinical and clinical studies that provides evidence for the benefits of moist wound healing (see Table 1) with positive outcomes for healing being achieved in a variety of wound types when wound dressings designed to provide optimal hydration levels in the wound are used as part of the overall wound care regimen. Figure 5 shows a schematic representation of some of the key differences between healing in a moist versus dry environment and Figures 6-9 show representative clinical examples of wounds treated with hydration-optimising wound dressings.

Concern that occlusion of wounds and the maintenance of a level of hydration within the wound would lead to an increase in bacterial number and infection appear to be unfounded, with studies showing that wounds treated with dressings promoting a moist wound healing environment are associated with a lower infection rate despite the wounds being colonised by bacteria.<sup>33-35</sup> Skin dermatitis has been reported after prolonged exposure to water.<sup>36,37</sup> A number of studies have suggested additional changes to the layers of the skin occur, particularly in the SC and include altered permeability and flexibility, viscoelastic properties, weakened intercellular attachment and changes in electrical impedance properties.<sup>38-44</sup> The physical structure of the epidermis can be particularly affected.<sup>45,46</sup> However, other studies have suggested that hydration-induced changes to the epidermis are quickly reversed upon removal of the cause.<sup>44,47,48</sup>

#### *Hyper-hydration of tissue and healing*

The adoption of the concept of moist wound healing by the wound care community has led to the development of a number of classes of wound dressings that have been designed to effectively manage the various levels of wound exudate produced by both acute and chronic wounds. Effective wound dressings must be able to cope with the volume of wound exudate production while at the same time maintain a level of tissue hydration that is consistent with a moist environment. This is despite the fact that there is no clear definition of what constitutes an "optimal" or "balanced" moist environment.<sup>22</sup> When considering wound dressing selection, clinicians are required to focus on the

capability of the dressing to absorb and retain a large volume of fluid while at the same time avoiding maceration of the peri-wound skin. Maceration of the peri-wound skin can occur as a result of prolonged contact of wound exudate with the peri-wound skin which may be a result of poor dressing performance or unrealistic expectations of wound dressing behaviour.

Tissue hydration and maceration may be difficult to differentiate at first glance. However, these are important concepts to separate as the former, i.e., maceration, has distinct physiological and clinical implications in terms of treatment options, whereas hydration (e.g., moist wound environment) is beneficial to wound healing (see below). Rippon et al. have recently defined the important differences between hydration and maceration and, further, have argued that the deleterious effects of maceration on wounds and peri-wound skin is as a result of the presence of damaging biological components fluids that cause maceration and not due to the presence of water.<sup>49</sup>

Irrespective of the cause, the presence of maceration has led to the assumption that a surfeit of moisture will inevitably lead to sustained tissue damage. However, a number of studies have indicated that a wound that is overly hydrated may not result in tissue damage,<sup>50-52</sup> and rather suggest that a wound bathed in a hyper-hydrated environment may benefit from the advantages of moist wound healing.<sup>30</sup> This is demonstrated in Figure 10.

Using chambers that seal fluid over the wound site creating a hyper-hydrated wound environment have examined tissue responses to being exposed to saline solution. In both pre-clinical and clinical studies, the hyper-hydrated wound environment proved to be safe for the treatment of a number of wounds. Wound healing under these hyper-hydrated conditions progressed in a similar manner to those where moist conditions were used<sup>30,52</sup> – the wounds showed less tissue necrosis, faster healing rates and a better quality of healing, compared with dry wounds.

The concept of creating a hyper-hydrated environment to support wound healing has been suggested for a number of years. Junker et al.<sup>30</sup> highlight work from the mid-19<sup>th</sup> century where patients with major burn wounds were submerged in bathtubs<sup>54</sup> and during the Second World War, wounded servicemen were treated in a manner whereby fluid was applied to and surrounded wounded tissue.<sup>55</sup> The application of a hyper-hydrated environment to a wound has become increasingly prevalent in the treatment of wounds with the development of irrigation systems designed for the delivery of fluid to wounds, particularly to promote wound cleansing. The addition of supplementary components to irrigation fluid (e.g., antimicrobials, growth factors, insulin) could expand the potential for wound irrigation devices.<sup>30</sup> Topical wound irrigation with saline solutions have been used successfully in promoting wound healing in a number of different wound types, including acute traumatic wounds,<sup>56,57</sup> infected wounds<sup>58</sup> and diabetic foot ulcers.<sup>59</sup> The introduction



of a hydrated wound environment as part of Negative Pressure Wound Therapy (NPWT) has been shown to enhance the uptake of wound exudate, removal of foreign material, devitalised tissue and bacterial contaminants as well as providing a hyper-hydrated environment.<sup>60</sup> “Instillation therapy” intermittently delivers fluid to the wound being treated by NPWT, acting as an adjunct to the therapy.<sup>61,62</sup> This therapy has been suggested to provide a unique (i.e., hyper-hydrated) wound environment that promotes wound bed preparation.<sup>63</sup> Continuous-instillation NPWT is a modification of the original instillation therapy concept whereby the hydrating fluid is constantly being replenished and renewed via an inflow-outflow tube system.<sup>61</sup> The development of NPWT with instillation and a dwell time (NPWTi-d) offers the delivery of a timed, predetermined volume of topical solution that is intermittently delivered and allowed to dwell in the wound bed whilst NPWT is paused for a predetermined time.<sup>64</sup> The NPWTi-d system promotes wound cleansing, loosening wound contaminants and facilitating their removal via the negative pressure phase.<sup>65</sup> With regard to the benefits of the presence of the instilled fluid on the wound environment, a panel of experts proposing a set of International Consensus Guidelines for Negative Pressure Wound Therapy with Instillation achieved >80% consensus on the use of a number of anti-microbial solutions for instillation.<sup>66</sup> The benefits of the hyper-hydrated environment, for example, when saline alone is used as the instilled solution – have also been noted.<sup>65</sup>

There are other examples where a hyper-hydrated environment results in timely, scar-free wound healing and where the wounds do not appear to sustain long-term damage from the effects of over-hydration. Although studies have suggested that scarless healing in skin wounds *in utero* is an intrinsic property of the foetal skin itself,<sup>67</sup> foetal skin wounds bathed in sterile, nutrient-rich amniotic fluid do not show signs of over-hydration. The environment of the oral mucosa is one that is bathed in saliva. This saliva ensures that a hyper-hydrated environment is maintained over the delicate tissues inside the oral cavity. As with foetal wounds, oral wounds heal quickly and with less scarring than skin wounds.<sup>68</sup> Similar to wounds of foetal tissues, oral wounds show no indications of detrimental effects of the hyper-hydrated environment in which they are found.

#### *Exudate-dependent tissue damage*

The findings suggesting that hyper-hydration is as beneficial to the wound healing response as a moist healing environment may be surprising as, clinically, excessive exudate in prolonged contact with the peri-wound skin has been associated with poor healing and the exacerbation of problems such as maceration.<sup>69,70</sup> It is clear that wounds maintained in a moist or hyper-hydrated environment do not appear to be suffer unduly (Figure 11). The studies examining the effect of a hyper-hydrated environment were carried out using synthetic tissue culture medias and are very different in composition from chronic wound exudates.<sup>50-53</sup> Studies have shown that ulcer-derived exudate is

fundamentally different from acute wound fluids.<sup>71,72</sup> The underlying pathological processes involved in chronic wound recalcitrance means that chronic exudate is highly damaging to tissues with its high content of protein-degrading enzymes.<sup>73</sup> Whilst proteases are necessary for normal wound healing,<sup>74</sup> the highly inflamed nature of the chronic wound bed is partly as a result of elevated and uncontrolled levels of proteases such as matrix metalloproteases,<sup>75,76</sup> neutrophil elastase<sup>73,77,78</sup> and pro-inflammatory cytokines in chronic wound exudate.<sup>79</sup> The combined presence of these corrosive components within chronic wound fluid leads to damage of the ulcer bed and wound margin. It should be noted also that the peri-wound skin of chronic wounds has a compromised barrier function when compared with undamaged skin<sup>80</sup> and is therefore its susceptibility to damage from chronic wound exudate is enhanced. In addition to the development of wound dressings which provide effective fluid management and limit the exposure of tissues to these corrosive fluids,<sup>32</sup> new areas of wound dressing research have focused on developing dressing technologies designed to specifically target and inhibit the excessive and damaging proteases present in chronic wounds.<sup>81-84</sup>

## CONCLUSION

The establishment and maintenance of an optimal level of hydration is key to maximising efficient progress of biological processes, including those found in the skin. When skin wounding occurs, an important aspect of the body's response to trauma is to re-establish skin barrier function, minimise fluid loss and safeguard hydration levels. Studies have shown that both moist and hyper-hydrated wounds heal at a faster rate than wounds exposed to the air and allowed to dry. These and other studies have indicated that water *per se* is not responsible for the deleterious effects of wound exudate found in the recalcitrant wound (e.g., ulcers) but, rather, that the biological components contained within wound fluid is directly responsible for the tissue damage that can be present during inefficient exudate management.

Optimisation of hydration balance at the wound site is a key property of modern wound dressings. Wound dressings with improved capability to manage both the fluid level and the damaging caustic components of chronic wound exudate maximise the management of these potentially harmful fluids while at the same time provide an optimal hydration balance.

## REFERENCES

1. Winsor, T., Burch, G.E. Differential roles of layers of human epigastric skin on diffusion rate of water. *Arch Intern Med.* 1944; 74: 6, 428-436.
2. Blank, I.H. Further observations on factors which influence the water content of the stratum corneum. *J Invest Dermatol.* 1953; 21: 4, 259-271.
3. Madison, K.C. Barrier function of the skin: "la raison d'être" of the epidermis. *J Invest Dermatol.* 2003; 121: 2, 231-241.
4. Verdier-Sévrain, S., Bonté, F. Skin hydration: a review on its molecular mechanisms. *J Cosmet Dermatol.* 2007; 6: 2, 75-82.
5. Harding, C.R. The stratum corneum: structure and function in health and disease. *Dermatol Ther.* 2004; 17: Suppl. 1, 6-15.
6. Rawlings, A.V., Harding, C.R. Moisturization and skin barrier function. *Dermatol Ther.* 2004; 17: Suppl. 1, 43-48.
7. Elias, P.M. Stratum corneum defensive functions: an integrated view. *J Invest Dermatol.* 2005; 125: 2, 183-200.
8. Warner, R.R., Myers, M.C., Taylor, D.A. Electron probe analysis of human skin: determination of the water concentration profile. *J Invest Dermatol.* 1988; 90: 2, 218-224.
9. Caspers, P.J., Lucassen, G.W., Puppels, G.J. Combined in vivo confocal Raman spectroscopy and confocal microscopy of human skin. *Biophys J.* 2003; 85: 1, 572-580.
10. Warner, R.R., Bush, R.D., Ruebusch, N.A. Corneocytes undergo systematic changes in element concentrations across the human inner stratum corneum. *J Invest Dermatol.* 1995; 104: 4, 530-536.
11. Warner, R.R., Myers, M.C., Taylor, D.A. Electron probe analysis of human skin: element concentration profiles. *J Invest Dermatol.* 1988; 90: 1, 78-85.
12. Barel, A.O., Clarys, P. Study of the stratum corneum barrier function by transepidermal water loss measurements: comparison between two commercial instruments: Evaporimeter and Tewameter. *Skin Pharmacol.* 1995; 8: 4, 186-195.
13. Wong, R., Tran, V., Talwalker, S., Benson, N.R. Analysis of RNA recovery and gene expression in the epidermis using non-invasive tape stripping. *J Dermatol Sci.* 2006; 44: 2, 81-92.
14. Xu, W., Jia, S., Xie, P. et al. The expression of proinflammatory genes in epidermal keratinocytes is regulated by hydration status. *J Invest Dermatol.* 2014; 134: 4, 1044-1055.
15. De Fine Olivarius, F., Agner, T., Menné, T. Skin barrier function and dermal inflammation. An experimental study of transepidermal water loss after dermal tuberculin injection compared with SLS patch testing. *Br J Dermatol.* 1993; 129: 5, 554-557.
16. Haratake, A., Uchida, Y., Mimura, K. et al. Intrinsically aged epidermis displays diminished UVB-induced alterations in barrier function associated with decreased proliferation. *J Invest Dermatol.* 1997; 108: 3, 319-323.
17. de Jongh, C.M., Jakasa, I., Verberk, M.M., Kezic, S. Variation in barrier impairment and inflammation of human skin as determined by sodium lauryl sulphate penetration rate. *Br J Dermatol.* 2006; 154: 4, 651-657.
18. Wood, L.C., Stalder, A.K., Liou, A. et al. Barrier disruption increases gene expression of cytokines and the 55 kD TNF receptor in murine skin. *Exp Dermatol.* 1997; 6: 2, 98-104.
19. Kloeters, O., Schierle, C., Tandara, A., Mustoe, T.A. The use of a semioclusive dressing reduces epidermal inflammatory cytokine expression and mitigates dermal proliferation and inflammation in a rat incisional model. *Wound Repair Regen.* 2008; 16: 4, 568-575.
20. Buraczewska, I., Berne, B., Lindberg, M. et al. Moisturizers change the mRNA expression of enzymes synthesizing skin barrier lipids. *Arch Dermatol Res.* 2009; 301: 8, 587-594.

21. Elias, P.M. Therapeutic implications of a barrier-based pathogenesis of atopic dermatitis. *Ann Dermatol.* 2010; 22: 3, 245-254.
22. Bishop, S.M., Walker, M., Rogers, A.A., Chen, W.Y.J. Importance of moisture balance at the wound-dressing interface. *J Wound Care.* 2003; 12: 4, 125-128.
23. Plante, G.E., Chakir, M., Ettaouil, K. et al. Consequences of alteration in capillary permeability. *Can J Physiol Pharmacol.* 1996; 74: 7, 824-833.
24. Faria, D., Fowler, E., Carson, S.N. Understanding edema and managing the edematous lower leg. In: Krasner, D. (ed). *Chronic Wound Care: A clinical source book for healthcare professionals*, HMP Communications, 2001.
25. Atiyeh, B.S., Hayek, S.N. Intérêt d'un onguent chinois (MEBO) dans le maintien local de l'humidité. *J Plaies Cicatrisation.* 2005; 9: 7-11.
26. Winter, G.D. Formation of the scab and the rate of epithelialization of superficial wounds in the skin of the young domestic pig. *Nature.* 1962; 193: 293-294.
27. Winter, G.D. Effect of air exposure and occlusion on experimental human skin wounds. *Nature.* 1963; 200: 378-379.
28. Winter, G.D., Scales, J.T. Effect of air drying and dressings on the surface of a wound. *Nature.* 1963; 197: 91-92.
29. Hinman, C.D., Maibach, H. Effect of air exposure and occlusion on experimental human skin wounds. *Nature.* 1963; 200: 377-378.
30. Junker, J.P., Kamel, R.A., Caterson, E.J., Eriksson, E. Clinical impact upon wound healing and inflammation in moist, wet, and dry environments. *Adv Wound Care (New Rochelle).* 2013; 2: 7, 348-356.
31. Butcher, M. Moist wound healing, exudate and management of the wound bed. *J Wound Care.* 2010; 19: Suppl. 1, 10-13.
32. Sibbald, R.G., Elliott, J.A., Ayello, E.A., Somayaji, R. Optimizing the moisture management tightrope with Wound Bed Preparation 2015©. *Adv Skin Wound Care.* 2015; 28: 10, 466-476.
33. Hutchinson, J.J., Lawrence, J.C. Wound infection under occlusive dressings. *J Hosp Infect.* 1991; 17: 2, 83-94.
34. Lawrence, J.C. Dressings and wound infection. *Am J Surg.* 1994; 167: 1A, 21S-24S.
35. Kannon, G.A., Garrett, A.B. Moist wound healing with occlusive dressings. A clinical review. *Dermatol Surg.* 1995; 21: 7, 583-590.
36. Willis, I. The effects of prolonged water exposure on human skin. *J Invest Dermatol.* 1973; 60: 3, 166-171.
37. Rietschel, R.L., Allen, A.M. Effects of prolonged continuous exposure of human skin to water: a reassessment. *J Invest Dermatol.* 1977; 68: 2, 79-81.
38. Scheuplein, R., Ross, L. Effects of surfactants and solvents on the permeability of epidermis. *J Soc Cosmet Chem.* 1970; 21: 853-873.
39. Evans, M.E., Roth, R. Shaping the skin: the interplay of mesoscale geometry and corneocyte swelling. *Phys Rev Lett.* 2014; 112: 3, 038102.
40. Park, A.C., Baddiel, C.B. Rheology of stratum corneum – II. A physico-chemical investigation of factors influencing the water content of the corneum. *J Soc Cosmet Chem.* 1972; 23: 1, 13-21.
41. Christensen, M.S., Hargens, C.W. 3rd, Nacht, S., Gans, E.H. Viscoelastic properties of intact human skin: instrumentation, hydration effects, and the contribution of the stratum corneum. *J Invest Dermatol.* 1977; 69: 3, 282-286.

42. Wildnauer, R.H., Bothwell, J.W., Douglass, A.B. Stratum corneum biochemical properties. I. Influence of relative humidity on normal and extracted human stratum corneum. *J Invest Dermatol.* 1971; 56: 1, 72-78.
43. Weigand, D.A., Gaylor, J.R. Removal of stratum corneum in vivo: an improvement on the cellophane tape stripping technique. *J Invest Dermatol.* 1973; 60: 2, 84-87.
44. Björklund, S., Ruzgas, T., Nowacka, A. et al. Skin membrane electrical impedance properties under the influence of a varying water gradient. *Biophys J.* 2013; 104: 12, 2639-2650.
45. Egawa, M., Hirao, T., Takahashi, M. In vivo estimation of stratum corneum thickness from water concentration profiles obtained with Raman spectroscopy. *Acta Derm Venereol.* 2007; 87: 1, 4-8.
46. Warner, R.R., Stone, K.J., Boissy, Y.L. Hydration disrupts human stratum corneum ultrastructure. *J Invest Dermatol.* 2003; 120: 2, 275-284.
47. Thomas, S. The role of dressings in the treatment of moisture-related skin damage. *World Wide Wounds*, <http://www.worldwidewounds.com/2008/march/Thomas/Maceration-and-the-role-of-dressings.html>, 2008. Accessed on 15 Sept 2015.
48. Tan, G., Xu, P., Lawson, L.B. et al. Hydration effects on skin microstructure as probed by high-resolution cryo-scanning electron microscopy and mechanistic implications to enhanced transcutaneous delivery of biomacromolecules. *J Pharm Sci.* 2010; 99: 2, 730-740.
49. Rippon, M.G., Ousey, K., Cutting, K.F. Wound healing and hyper-hydration – a counter intuitive model. *J Wound Care* (in press)
50. Breuing, K., Eriksson, E., Liu, P., Miller, D.R. Healing of partial thickness porcine skin wounds in a liquid environment. *J Surg Res.* 1992; 52: 1, 50-58.
51. Svensjö, T., Pomahac, B., Yao, F. et al. Accelerated healing of full-thickness skin wounds in a wet environment. *Plast Reconstr Surg.* 2000; 106: 3, 602-612.
52. Vranckx, J.J., Slama, J., Preuss, S. et al. Wet wound healing. *Plast Reconstr Surg.* 2002; 110: 7, 1680-1687.
53. Vogt, P.M., Andree, C., Breuing, K. et al. Dry, moist, and wet skin wound repair. *Ann Plast Surg.* 1995; 34: 5, 493-499.
54. Hebra, F. Ueber kontinuierliche allgemeine Bäder und deren Anwendung bei Behandlung von Verbrennungen Allgemeiner. *Wiener Medizinische Zeitung.* 1861, 6: 351-354.
55. Bunyan, J. Treatment of burns and wounds by the envelope method. *Br Med J.* 1941; 2: 4200, 1-7.
56. Dulecki, M., Pieper, B. Irrigating simple acute traumatic wounds: a review of the current literature. *J Emerg Nurs.* 2005; 31: 2, 156-160.
57. Hall, S. A review of the effect of tap water versus normal saline on infection rates in acute traumatic wounds. *J Wound Care.* 2007; 16: 1, 38-41.
58. Tao, Q., Ren, J., Ji, Z. et al. Continuous topical irrigation for severely infected wound healing. *J Surg Res.* 2015; 198: 2, 535-540.
59. Zelen, C.M., Stover, B., Nielson, D., Cunningham, M. A prospective study of negative pressure wound therapy with integrated irrigation for the treatment of diabetic foot ulcers. *Eplasty.* 2011; 11: e5.
60. Gabriel, A., Kahn, K.M. New advances in instillation therapy in wounds at risk for compromised healing. *Surg Technol Int.* 2014; 24: 75-81.
61. Huang, C., Leavitt, T., Bayer, L.R., Orgill, D.P. Effect of negative pressure wound therapy on wound healing. *Curr Probl Surg.* 2014; 51: 7, 301-331.
62. Scimeca, C.L., Bharara, M., Fisher, T.K. et al. Novel use of insulin in continuous-instillation negative pressure wound therapy as "wound chemotherapy" *J Diabetes Sci Technol.* 2010; 4: 4, 820-824.

63. Raad, W., Lantis, J.C. 2nd, Tyrie, L. et al. Vacuum-assisted closure instill as a method of sterilizing massive venous stasis wounds prior to split thickness skin graft placement. *Int Wound J.* 2010; 7: 2, 81-85.
64. Gabriel, A., Kahn, K., Karmy-Jones, R. Use of negative pressure wound therapy with automated, volumetric instillation for the treatment of extremity and trunk Wounds: Clinical outcomes and potential cost-effectiveness. *Eplasty.* 2014; 14: 328-338.
65. Wolvos, T. The evolution of negative pressure wound therapy: negative pressure wound therapy with instillation. *J Wound Care.* 2015; 24: 4 Suppl., 15-20.
66. Kim, P.J., Attinger, C.E., Steinberg, J.S. et al. Negative-pressure wound therapy with instillation: international consensus guidelines. *Plast Reconstr Surg.* 2013; 132: 6, 1569-1579.
67. Leung, A., Crombleholme, T.M., Keswani, S.G. Fetal wound healing: implications for minimal scar formation. *Curr Opin Pediatr.* 2012; 24: 3, 371-378.
68. Brand, H.S., Ligtenberg, A.J., Veerman, E.C. Saliva and wound healing. *Monogr Oral Sci.* 2014; 24: 52-60.
69. Cutting, K.F. The causes and prevention of maceration of the skin. *J Wound Care.* 1999; 8: 4, 200-201.
70. Cutting, K.F., White, R.J. Maceration of the skin and wound bed 1: Its nature and causes. *J Wound Care.* 2002; 11: 7, 275-278.
71. Trengove, N.J., Stacey, M.C., MacAuley, S. et al. Analysis of the acute and chronic wound environments: the role of proteases and their inhibitors. *Wound Repair Regen.* 1999; 7: 6, 442-452.
72. Hart, J. Inflammation 2: its role in the healing of chronic wounds. *J Wound Care.* 2002; 11: 7, 245-249.
73. McCarty, S.M., Percival, S.L. Proteases and delayed wound healing. *Adv Wound Care.* 2013; 2: 8, 438-447.
74. Schultz, G.S., Sibbald, R.G., Falanga, V. et al. Wound bed preparation: a systematic approach to wound management. *Wound Repair Regen.* 2003; 11; Suppl. 1, S1-S28.
75. Caley, M.P., Martins, V.L.C., O'Toole, E.A. Metalloproteinases and wound healing. *Adv Wound Care.* 2015; 4: 4, 225-234.
76. Gibson, D.J., Schultz, G.S. Molecular wound assessments: matrix metalloproteinases. *Adv Wound Care.* 2013; 2: 1, 18-23.
77. McDaniel, J.C., Roy, S., Wilgus, T.A. Neutrophil activity in chronic venous leg ulcers – a target for therapy? *Wound Repair Regen.* 2013; 21: 3, 339-351.
78. Wilgus, T.A., Roy, S., McDaniel, J.C. Neutrophils and wound repair: positive actions and negative reactions. *Adv Wound Care.* 2013; 2: 7, 379-388.
79. Eming, S.A., Krieg, T., Davidson, J.M. Inflammation in wound repair: molecular and cellular mechanisms. *J Invest Dermatol.* 2007; 127: 3, 514-525.
80. Walker, M., Hulme, T.A., Rippon, M.G. et al. In vitro model(s) for the percutaneous delivery of active tissue repair agents. *J Pharm Sci.* 1997; 86: 12, 1379-1384.
81. Vasconcelos, A., Cavaco-Paulo, A. Wound dressings for a proteolytic-rich environment. *Appl Microbiol Biotechnol.* 2011; 90: 2, 445-460.
82. Wiegand, C., Hipler, U.C. A superabsorbent polymer-containing wound dressing efficiently sequesters MMPs and inhibits collagenase activity in vitro. *J Mater Sci Mater Med.* 2013; 24: 10, 2473-2478.
83. Wiegand, C., Abel, M., Ruth, P., Hipler, U.C. Superabsorbent polymer-containing wound dressings have a beneficial effect on wound healing by reducing PMN elastase concentration and inhibiting microbial growth. *J Mater Sci Mater Med.* 2011; 22: 11, 2583-2590.

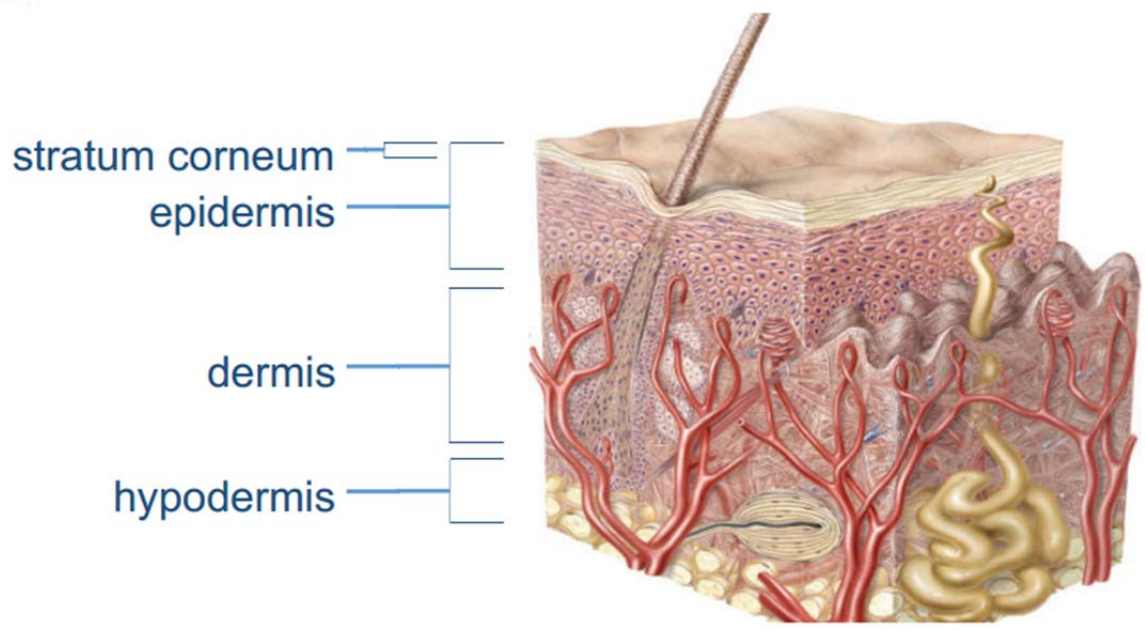
84. Edwards, J.V., Caston-Pierre, S. Citrate-linked keto- and aldo-hexose monosaccharide cellulose conjugates demonstrate selective human neutrophil elastase-lowering activity in cotton dressings. *J Funct Biomater*. 2013; 4: 2, 59-73.
85. Dyson, M., Young, S., Pendle, C.L. et al. Comparison of the effects of moist and dry conditions on dermal repair. *J Invest Dermatol*. 1988; 91: 5, 434-439.
86. Beam, J.W. Occlusive dressings and the healing of standardized abrasions. *J Athl Train*. 2008; 43: 6, 600-607.
87. Eaglstein, W.H. Moist wound healing with occlusive dressings: a clinical focus. *Dermatol Surg*. 2001; 27: 2, 175-182.
88. Ågren, M.S., Karlsmark, T., Hansen, J.B., Rygaard, J. Occlusion versus air exposure on full-thickness biopsy wounds. *J Wound Care*. 2001; 10: 8, 301-304.
89. Varghese, M.C., Balin, A.K., Carter, D.M., Caldwell, D. Local environment of chronic wounds under synthetic dressings. *Arch Dermatol*. 1986; 122: 1, 52-57.
90. Rubio, P.A. Use of semioclusive, transparent film dressings for surgical wound protection: experience in 3637 cases. *Int Surg*. 1991; 76: 4, 253-254.
91. Madden, M.R., Nolan, E., Finkelstein, J.L. et al. Comparison of an occlusive and semi-occlusive dressing and the effect of the wound exudate upon keratinocyte proliferation. *J Trauma*. 1989; 29: 7, 924-931.
92. Wigger-Alberti, W., Kuhlmann, M., Ekanayake, S., Wilhelm, D. Using a novel wound model to investigate the healing properties of products for superficial wounds. *J Wound Care*. 2009; 18: 3, 123-131.
93. Dyson, M., Young, S.R., Hart, J. et al. Comparison of the effects of moist and dry conditions on the process of angiogenesis during dermal repair. *J Invest Dermatol*. 1992; 99: 6, 729-733.
94. Mosti, G. Wound care in venous ulcers. *Phlebology*. 2013; 28: Suppl. 1, 79-85.
95. Korting, H.C., Schöllmann, C., White, R.J. Management of minor acute cutaneous wounds: importance of wound healing in a moist environment. *J Eur Acad Dermatol Venereol*. 2011; 25: 2, 130-137.
96. Chen, W.Y.J., Rogers, A.A., Lydon, M.J. Characterization of biologic properties of wound fluid collected during early stages of wound healing. *J Invest Dermatol*. 1992; 99: 5, 559-564.
97. Leung, B.K., LaBarbera, L.A., Carroll, C.A. et al. The effects of normal saline instillation in conjunction with negative pressure wound therapy on wound healing in a porcine model. *Wounds*. 2010; 22: 7, 179-187.
98. Field, C.K., Kerstein, M.D. Overview of wound healing in a moist environment. *Am J Surg*. 1994; 167: 1A Suppl., 2S-6S.
99. Dowsett, C., Ayello, E. TIME principles of chronic wound bed preparation and treatment. *Br J Nurs*. 2004; 13: 15, S16-S23.
100. Katz, M.H., Alvarez, A.F., Kirsner, R.S. et al. Human wound fluid from acute wounds stimulates fibroblast and endothelial cell growth. *J Am Acad Dermatol*. 1991; 25: 6 Part 1, 1054-1058.
101. Atiyeh, B.S., Dham, R., Costagliola, M. et al. Moist exposed therapy: an effective and valid alternative to occlusive dressings for postlaser resurfacing wound care. *Dermatol Surg*. 2004; 30: 1, 18-25.
102. Atiyeh, B.S., El-Musa, K.A., Dham, R. Scar quality and physiologic barrier function restoration after moist and moist-exposed dressings of partial-thickness wounds. *Dermatol Surg*. 2003; 29: 1, 14-20.
103. O'Shaughnessy, K.D., De La Garza, M., Roy, N.K., Mustoe, T.A. Homeostasis of the epidermal barrier layer: a theory of how occlusion reduces hypertrophic scarring. *Wound Repair Regen*. 2009; 17: 5, 700-708.

104. Mustoe, T.A., Gurjala, A. The role of the epidermis and the mechanism of action of occlusive dressings in scarring. *Wound Repair Regen.* 2011; 19: Suppl. 1, s16-s21.
105. Tandara, A.A., Kloeters, O., Mogford, J.E., Mustoe, T.A. Hydrated keratinocytes reduce collagen synthesis by fibroblasts via paracrine mechanisms. *Wound Repair Regen.* 2007; 15: 4, 497-504.
106. Hoeksema, H., De Vos, M., Verbelen, J. et al. Scar management by means of occlusion and hydration: a comparative study of silicones versus a hydrating gel-cream. *Burns.* 2013; 39: 7, 1437-1448.
107. Hackl, F., Kiwanuka, E., Philip, J. et al. Moist dressing coverage supports proliferation and migration of transplanted skin micrografts in full-thickness porcine wounds. *Burns.* 2014; 40: 2, 274-280.
108. Powers, J.G., Morton, L.M., Phillips, T.J. Dressings for chronic wounds. *Dermatol Ther.* 2013; 26: 3, 197-206.
109. Attinger, C.E., Janis, J.E., Steinberg, J. et al. Clinical approach to wounds: debridement and wound bed preparation including the use of dressings and wound-healing adjuvants. *Plast Reconstr Surg.* 2008; 117: 7 Suppl, 72S-109S.
110. Wiechula, R. The use of moist wound-healing dressings in the management of split-thickness skin graft donor sites: a systematic review. *Int J Nurs Pract.* 2003; 9: 2, S9-S17.
111. Metzger, S. Clinical and financial advantages of moist wound management. *Home Healthc Nurse.* 2004; 22: 9, 586-590.
112. Leaper, D.J., Schultz, G., Carville, K. et al. Extending the TIME concept: what have we learned in the past 10 years? *Int Wound J.* 2012; 9: Suppl. 2, 1-19.
113. Coutts, P., Woo, K.Y., Bourque, S. Treating patients with painful chronic wounds. *Nurs Stand.* 2008; 23: 10, 42-46.
114. Feldman, D.L. Which dressing for split-thickness skin graft donor sites? *Ann Plast Surg.* 1991; 27: 3, 288-291.
115. Nemeth, A.J., Eaglstein, W.H., Taylor, J.R., et al. Faster healing and less pain in skin biopsy sites treated with an occlusive dressing. *Arch Dermatol.* 1991; 127: 11, 1679-1683.
116. King, A., Stellar, J.J., Blevins, A., Shah, K.N. Dressings and products in pediatric wound care. *Adv Wound Care.* 2014; 3: 4, 324-334.
117. Gray, D., White, R., Cooper, P., Kingsley, A. Applied wound management and using the wound healing continuum in practice. *Wound Essentials.* 2010; 5: 131-139.

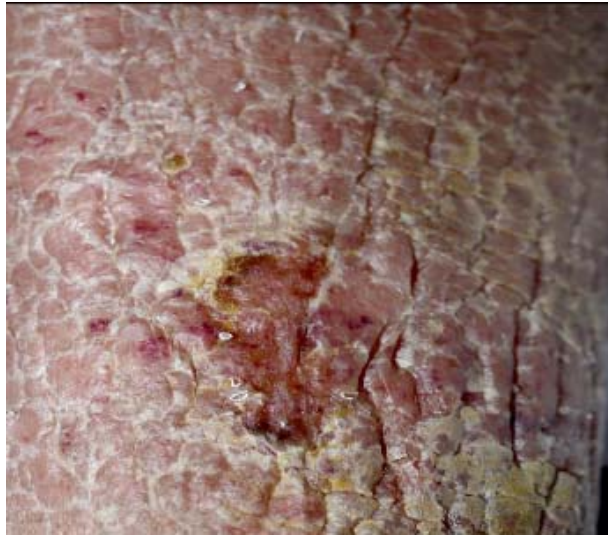


<b>Benefits of moist wound healing</b>
<b>Faster wound healing</b> <sup>26,85,86</sup>
<b>Promote epithelialisation rate</b> <sup>26,87-93</sup>
<b>Promote dermal/wound bed healing responses, e.g., cell proliferation, ECM synthesis</b> <sup>51,93-100</sup>
<b>Reduces scarring</b> <sup>101-106</sup>
<b>Retention of growth factors at wound site</b> <sup>51,53,96,107-109</sup>
<b>Lower wound infection rates</b> <sup>33-35</sup>
<b>Reduces pain perception</b> <sup>110-115</sup>
<b>Enhances autolytic debridement</b> <sup>116,117</sup>

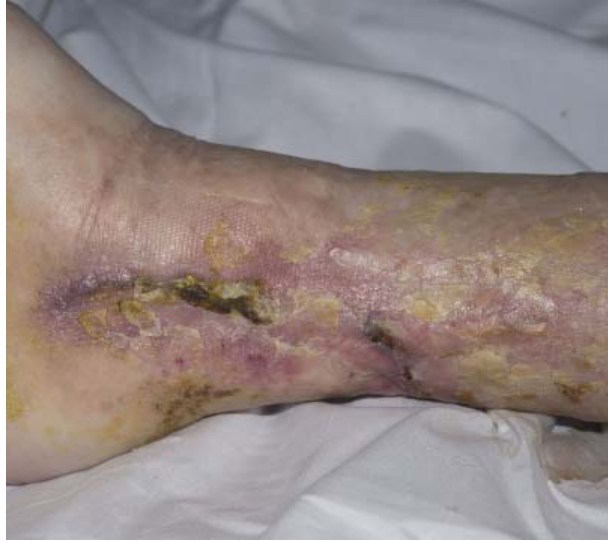Table 1: Benefits of moist wound healing



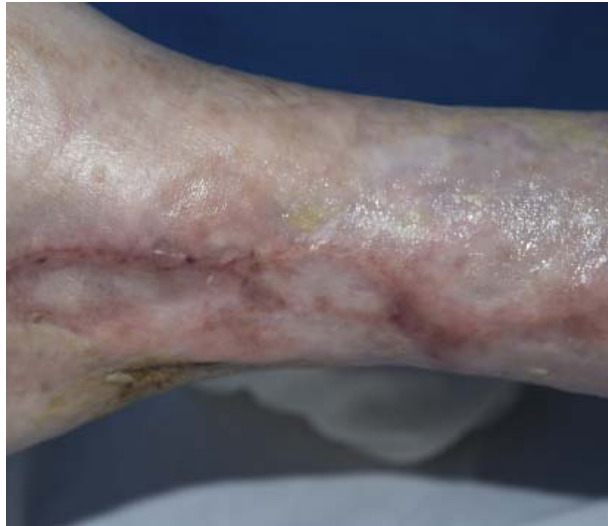**Figure 1:** Structure of skin showing stratum corneum as outermost barrier layer of skin.



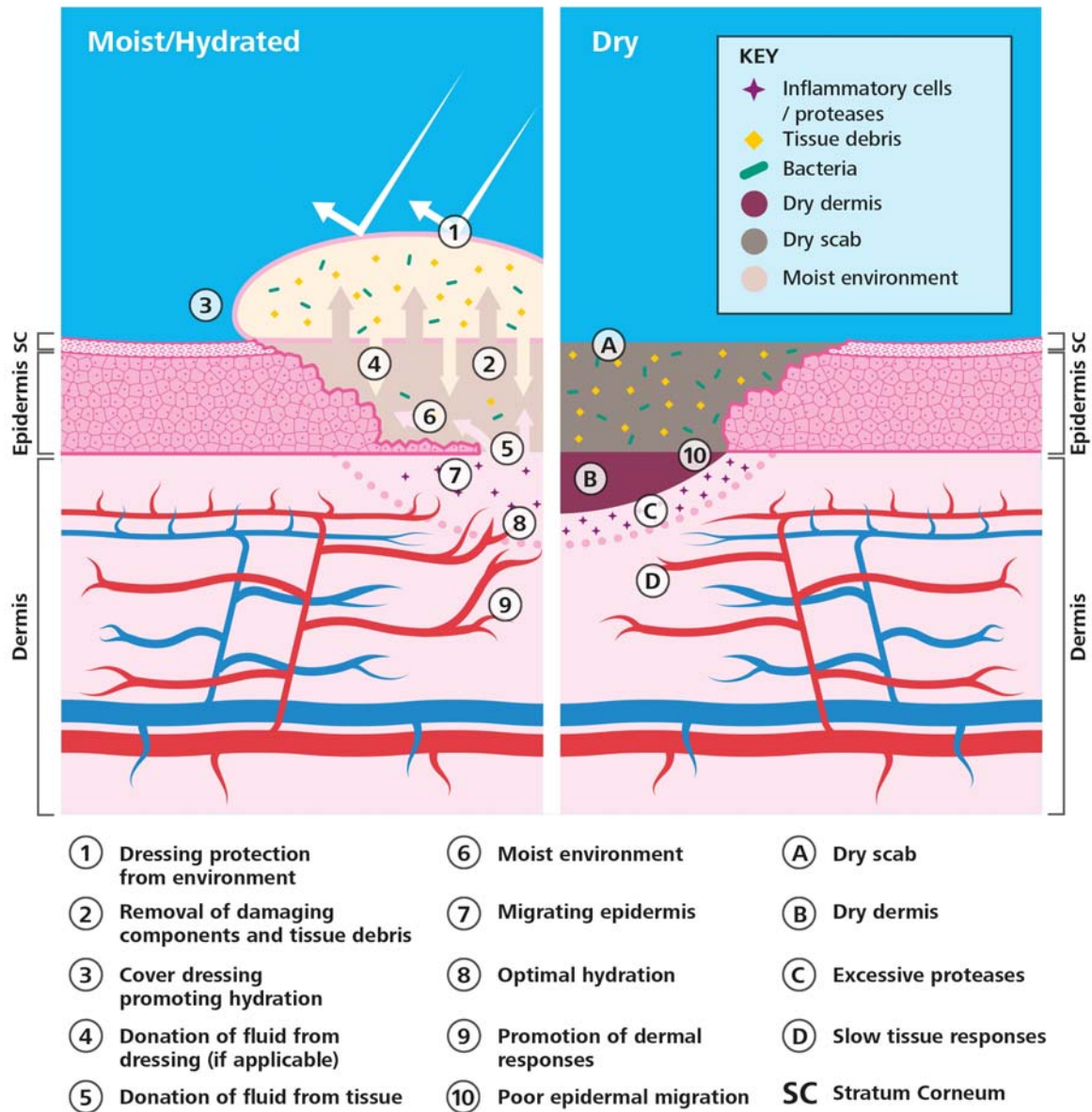
**Figure 2:** Dry, flaky skin as a result of inadequate hydration.



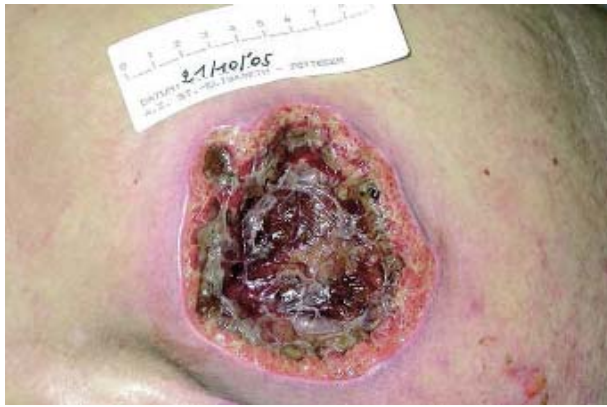**Figure 3:** Wound of the leg showing presence of scab covering wound.



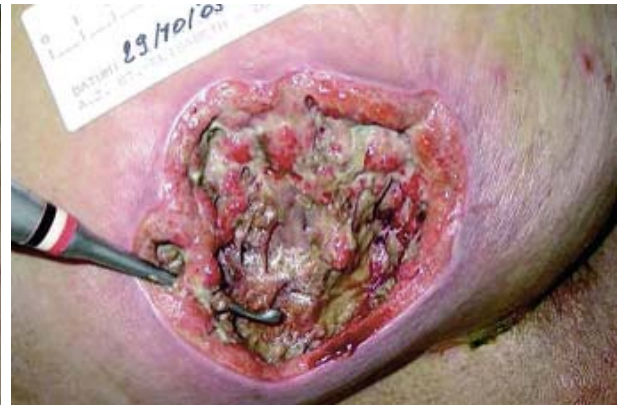**Figure 4:** Wound of the leg showing coverage of wound site with new epidermal coverage.



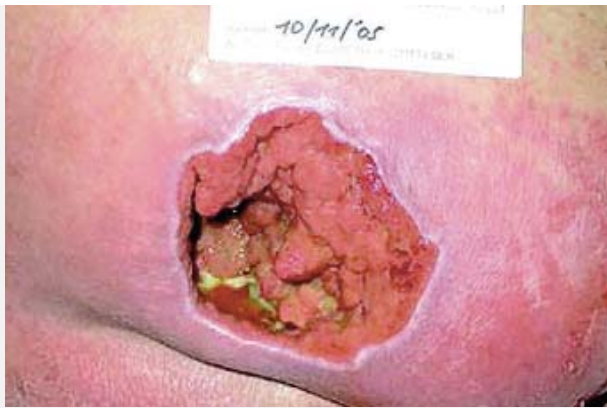**Figure 5:** Comparison of processes in wound healing under moist/hydrated and dry healing environments.



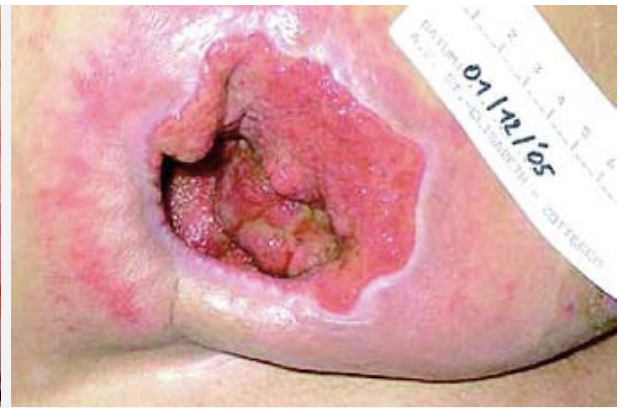A



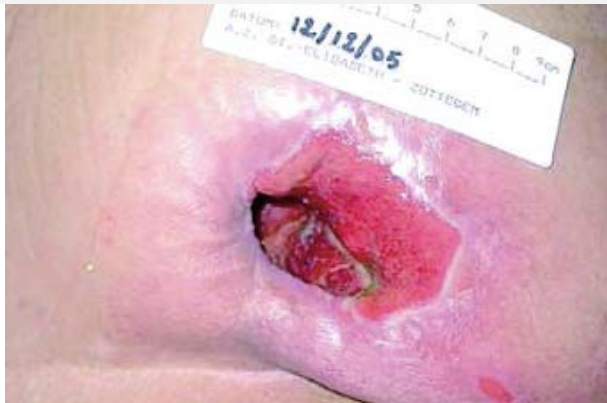B



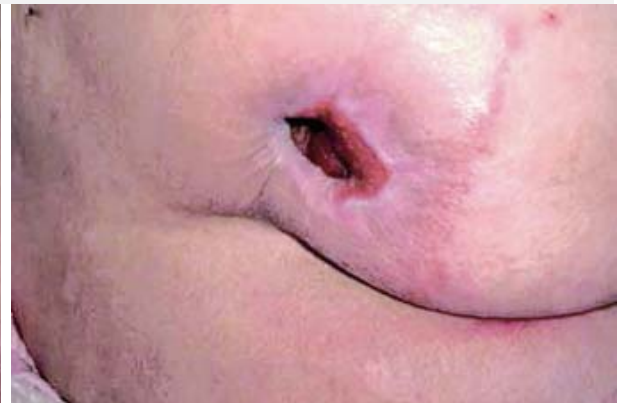C



D

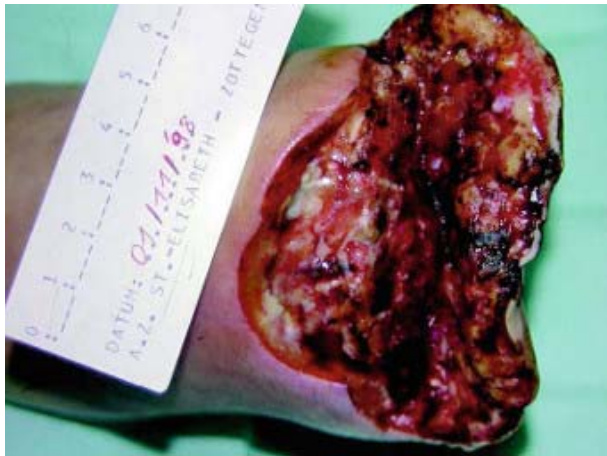

E

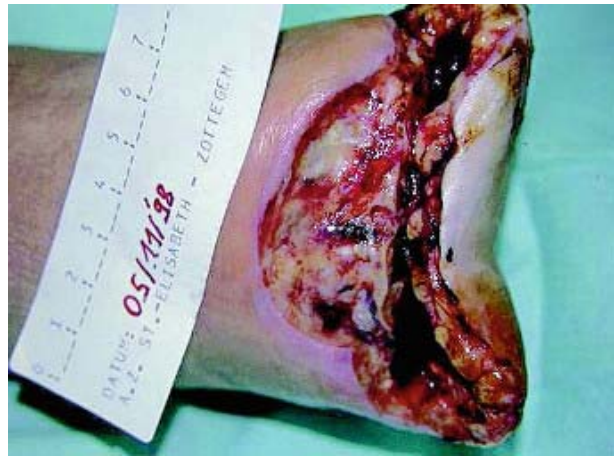

F

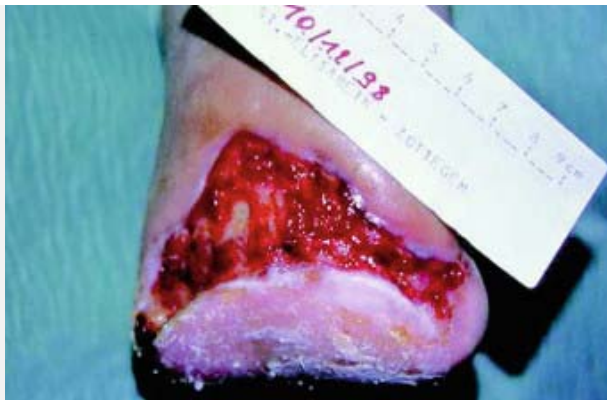**Figure 6:** Patient with a stage 4 pressure ulcer showing healing progress during treatment with dressing that optimises wound hydration levels. A) Day 0; B) Day 8; C) Day 22; D) Day 43; E) Day 55; and F) 2.5 months.



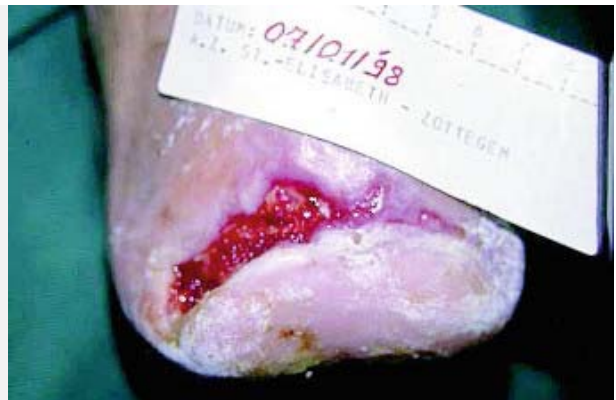A



B



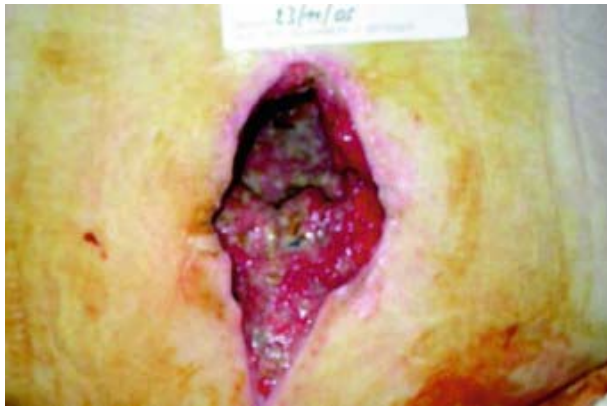C



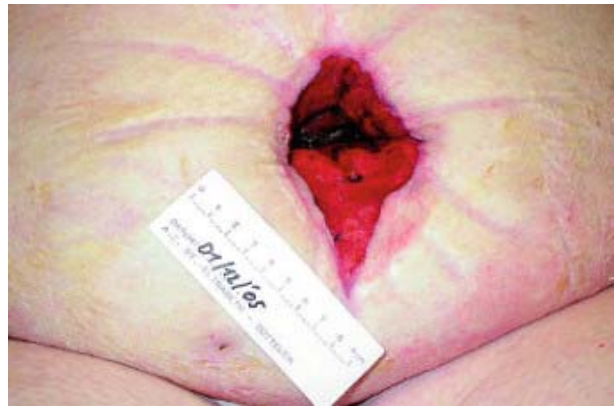D

**Figure 7:** Patient with surgical wound after amputation of diabetic foot showing wound healing progress during treatment with dressing that optimises wound hydration levels. A) Day 0; B) Day 5; C) Day 40; and D) Day 68.

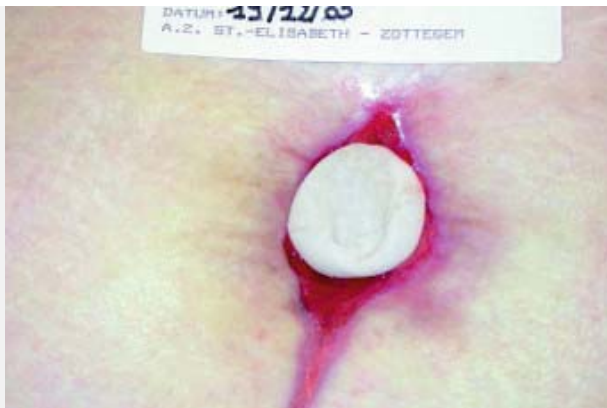



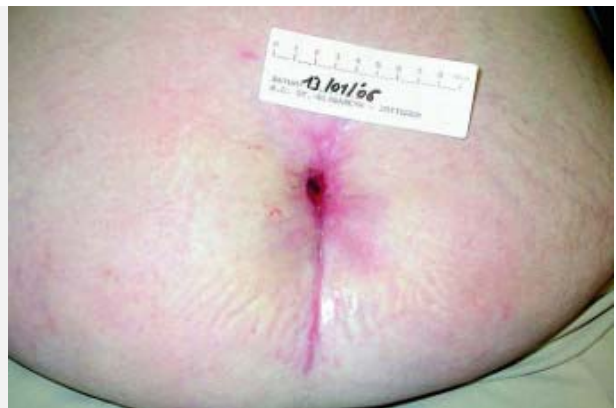A



B

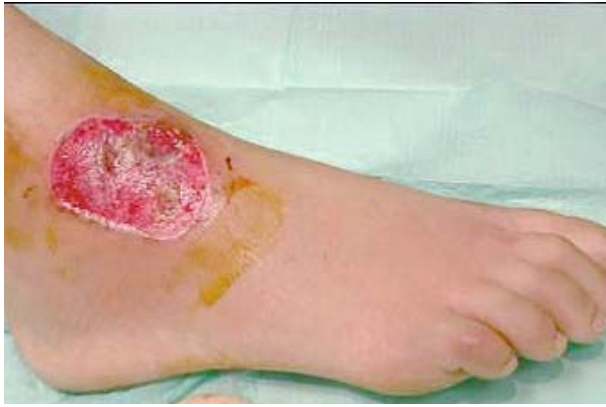

C

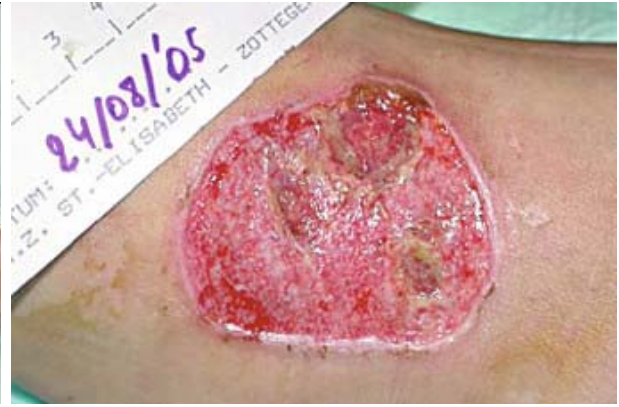

D

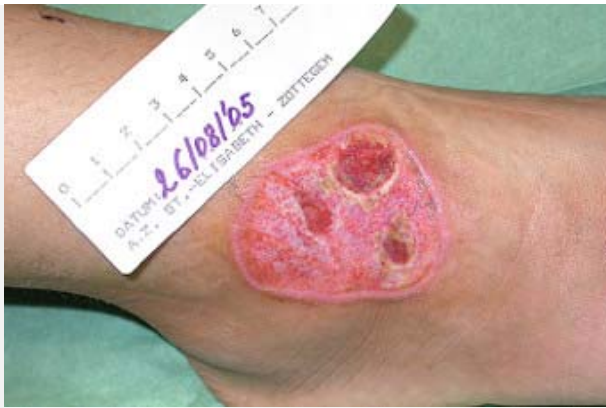**Figure 8:** Patient with wound dehiscence after abdominal surgery showing wound healing progress during treatment with dressing that optimises wound hydration levels. A) Day 0; B) Day 8; C) Day 27; and D) 1.5 months.



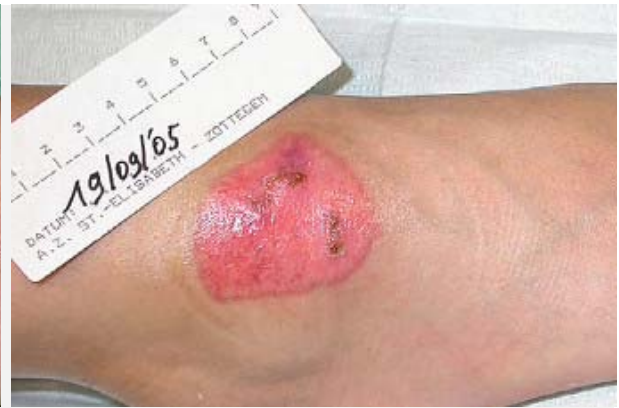A



B

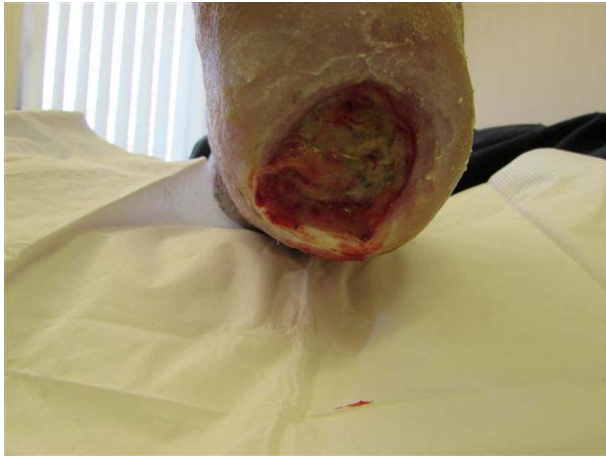

C

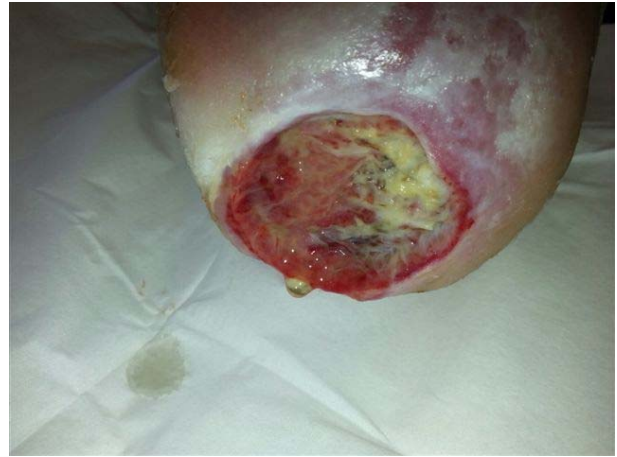

D

**Figure 9:** Patient with traumatic wound after falling from moped showing wound healing progress during treatment with dressing that optimises wound hydration levels. A) and B) Day 1; C) Day 3; and D) Day 26.

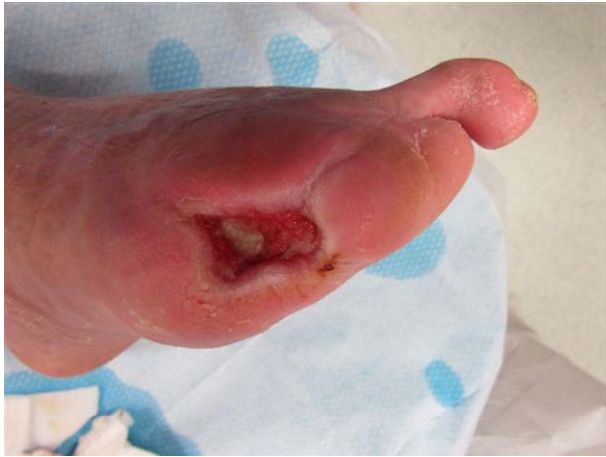

**A**

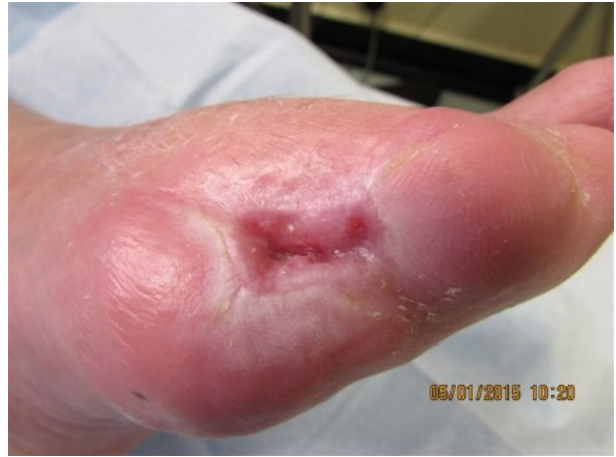

**B**

**Figure 10:** A) A wound showing signs of a possible under-hydrated state and B) wound progression when a hydro-responsive wound dressing.



**A**



**B**

**Figure 11:** A) An amputation wound site on the foot of a diabetic patient showing good wound progression after 6 weeks' treatment with a hydro-responsive wound dressing.